NOVEL STRUCTURED MRI REPORTING SYSTEM IN NEONATAL HYPOXIC-ISCHEMIC ENCEPHALOPATHY – ISSUES OF DEVELOPMENT AND FIRST USE EXPERIENCES

Andrea LAKATOS[1], Márton KOLOSSVÁRY[1, 2], Miklós SZABÓ[3], Ágnes JERMENDY[3], Zsolt BAGYURA[2], Péter BARSI[1], Gábor RUDAS[1], Lajos R. KOZÁK[1]

[1]MR Research Center, Semmelweis University, Budapest
[2]MTA-SE Cardiovascular Imaging Research Group, Heart and Vascular Center, Semmelweis University, Budapest
[3]First Department of Paediatrics, Semmelweis University, Budapest

Correspondent: Lajos R. KOZÁK PhD, MR Research Center, Semmelweis University;
1083 Budapest, Balassa u. 6. Telephone/fax: +36-1-459-1580. E-mail: lrkozak@gmail.com
https://orcid.org/0000-0003-0368-3663

Érkezett: 2017. november 30. Elfogadva: 2018. január 2.

Online kiegészítő ábra (az iSORT reprezentációja fagráfban) a „Strukturált koponya-MR-leletezés neonatalis hypoxiás-ischaemiás encephalopathiában – a fejlesztés speciális kérdései és első tapasztalatok” című közleményhez

Supplementary Figure 1. *Tree representation of the iSORT template*

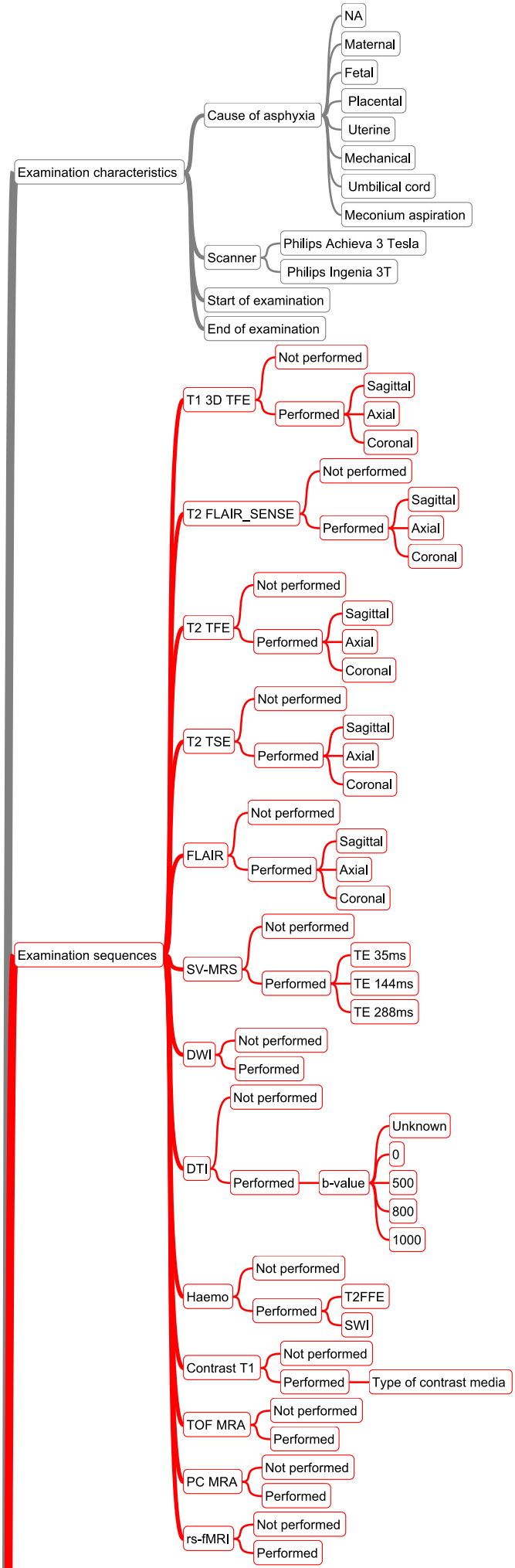
Examination characteristics
Cause of asphyxia
NA
Maternal
Fetal
Placental
Uterine
Mechanical
Umbilical cord
Meconium aspiration
Scanner
Philips Achieva 3 Tesla
Philips Ingenia 3T
Start of examination
End of examination
Examination sequences
T1 3D TFE
Not performed
Performed
Sagittal
Axial
Coronal
T2 FLAIR_SENSE
Not performed
Performed
Sagittal
Axial
Coronal
T2 TFE
Not performed
Performed
Sagittal
Axial
Coronal
T2 TSE
Not performed
Performed
Sagittal
Axial
Coronal
FLAIR
Not performed
Performed
Sagittal
Axial
Coronal
SV-MRS
Not performed
Performed
TE 35ms
TE 144ms
TE 288ms
DWI
Not performed
Performed
DTI
Not performed
Performed
b-value
Unknown
0
500
800
1000
Haemo
Not performed
Performed
T2FFE
SWI
Contrast T1
Not performed
Performed
Type of contrast media
TOF MRA
Not performed
Performed
PC MRA
Not performed
Performed
rs-fMRI
Not performed
Performed

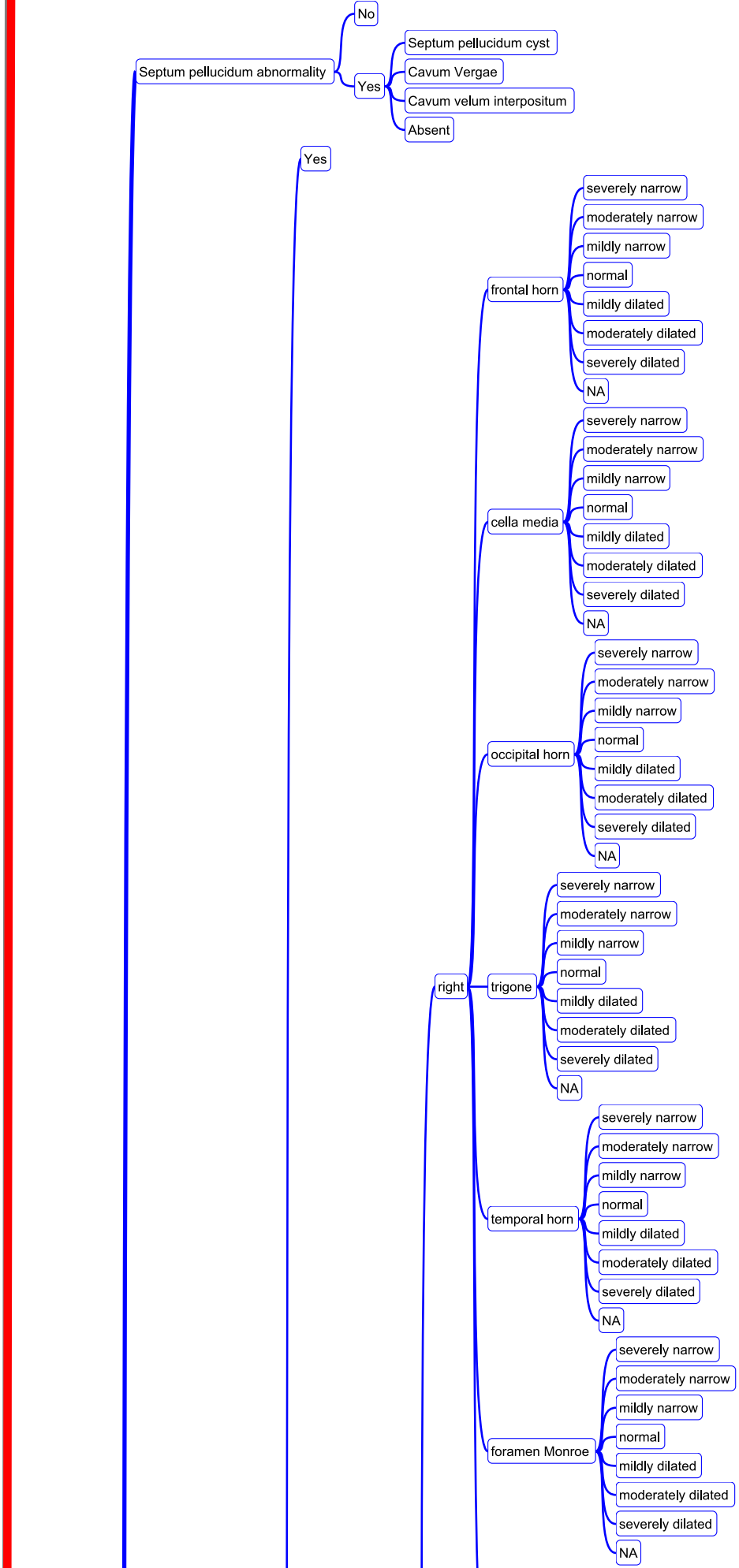
No
Septum pellucidum abnormality
Yes
Septum pellucidum cyst
Cavum Vergae
Cavum velum interpositum
Absent
Yes
right
frontal horn
severely narrow
moderately narrow
mildly narrow
normal
mildly dilated
moderately dilated
severely dilated
NA
cella media
severely narrow
moderately narrow
mildly narrow
normal
mildly dilated
moderately dilated
severely dilated
NA
occipital horn
severely narrow
moderately narrow
mildly narrow
normal
mildly dilated
moderately dilated
severely dilated
NA
trigone
severely narrow
moderately narrow
mildly narrow
normal
mildly dilated
moderately dilated
severely dilated
NA
temporal horn
severely narrow
moderately narrow
mildly narrow
normal
mildly dilated
moderately dilated
severely dilated
NA
foramen Monroe
severely narrow
moderately narrow
mildly narrow
normal
mildly dilated
moderately dilated
severely dilated
NA

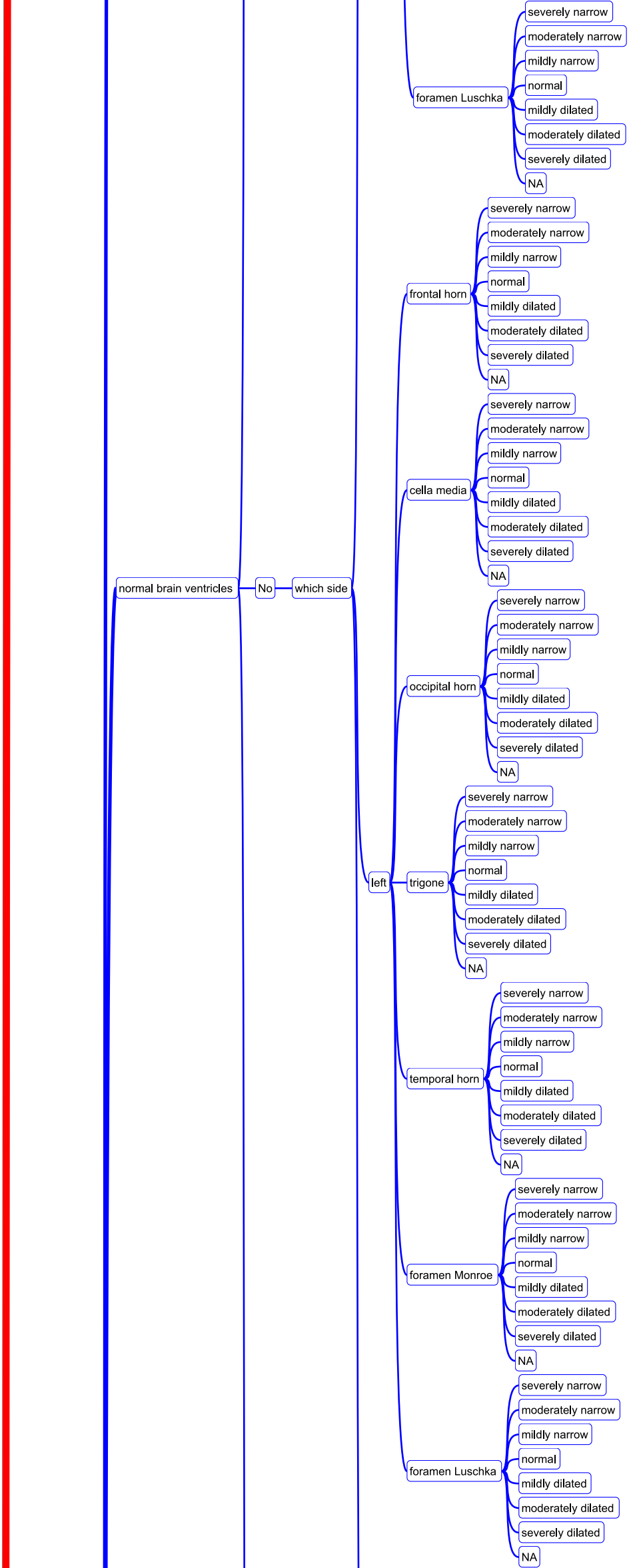
foramen Luschka
severely narrow
moderately narrow
mildly narrow
normal
mildly dilated
moderately dilated
severely dilated
NA
normal brain ventricles
No
which side
left
frontal horn
severely narrow
moderately narrow
mildly narrow
normal
mildly dilated
moderately dilated
severely dilated
NA
cella media
severely narrow
moderately narrow
mildly narrow
normal
mildly dilated
moderately dilated
severely dilated
NA
occipital horn
severely narrow
moderately narrow
mildly narrow
normal
mildly dilated
moderately dilated
severely dilated
NA
trigone
severely narrow
moderately narrow
mildly narrow
normal
mildly dilated
moderately dilated
severely dilated
NA
temporal horn
severely narrow
moderately narrow
mildly narrow
normal
mildly dilated
moderately dilated
severely dilated
NA
foramen Monroe
severely narrow
moderately narrow
mildly narrow
normal
mildly dilated
moderately dilated
severely dilated
NA
foramen Luschka
severely narrow
moderately narrow
mildly narrow
normal
mildly dilated
moderately dilated
severely dilated
NA

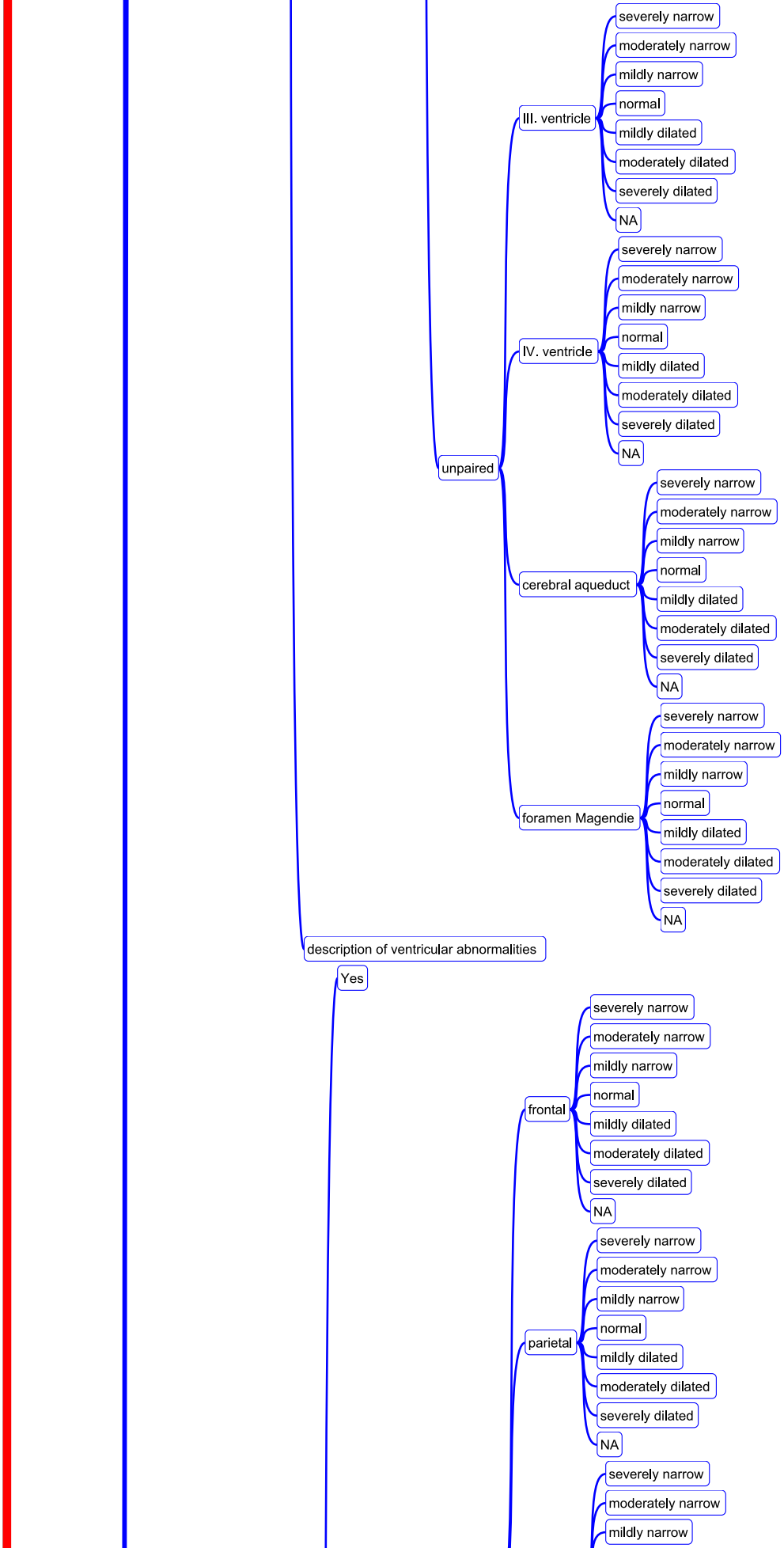
severely narrow
moderately narrow
mildly narrow
normal
mildly dilated
moderately dilated
severely dilated
NA
III. ventricle
severely narrow
moderately narrow
mildly narrow
normal
mildly dilated
moderately dilated
severely dilated
NA
IV. ventricle
unpaired
severely narrow
moderately narrow
mildly narrow
normal
mildly dilated
moderately dilated
severely dilated
NA
cerebral aqueduct
severely narrow
moderately narrow
mildly narrow
normal
mildly dilated
moderately dilated
severely dilated
NA
foramen Magendie
description of ventricular abnormalities
Yes
severely narrow
moderately narrow
mildly narrow
normal
mildly dilated
moderately dilated
severely dilated
NA
frontal
severely narrow
moderately narrow
mildly narrow
normal
mildly dilated
moderately dilated
severely dilated
NA
parietal
severely narrow
moderately narrow
mildly narrow

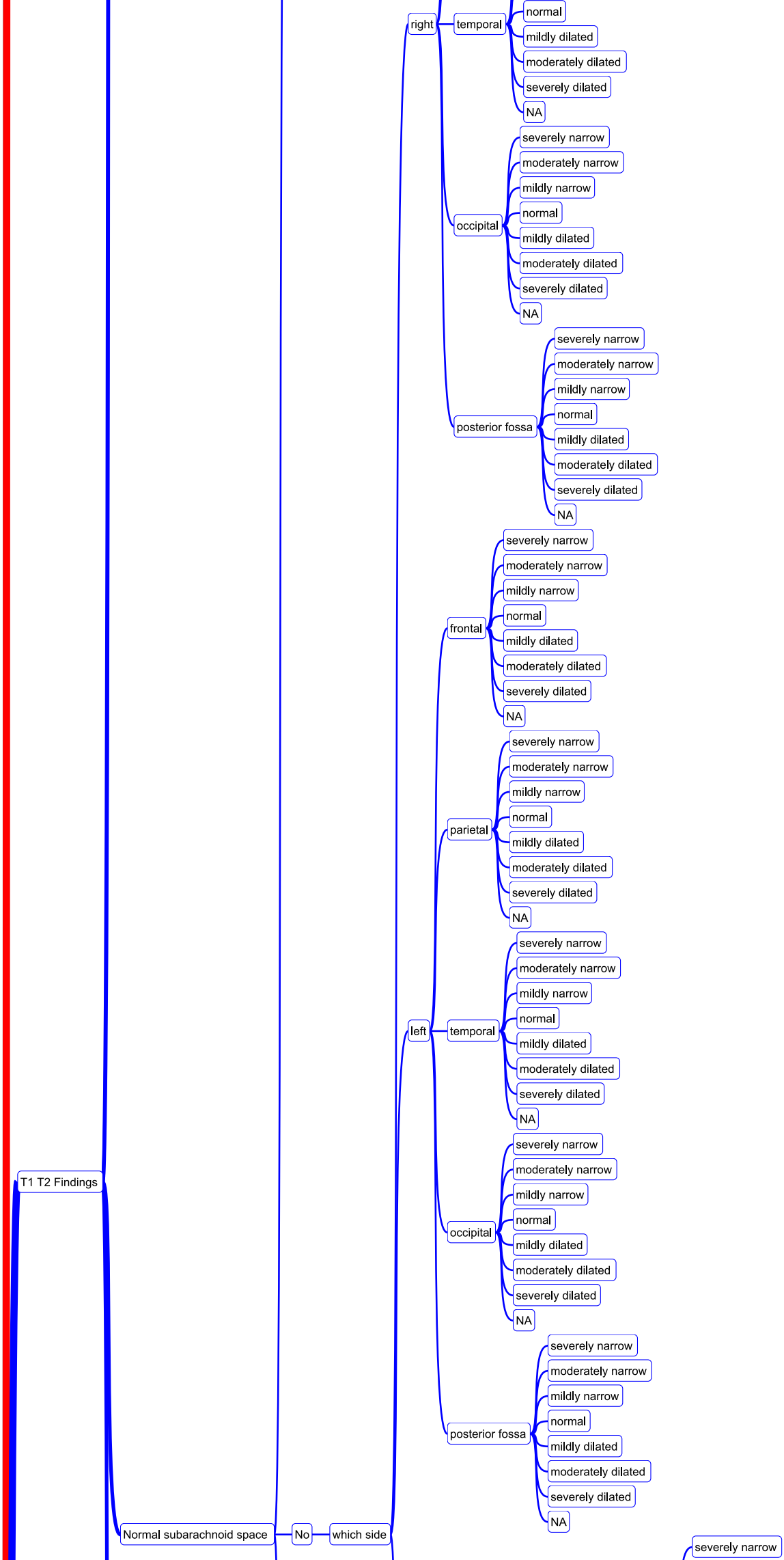
right
temporal
normal
mildly dilated
moderately dilated
severely dilated
NA
occipital
severely narrow
moderately narrow
mildly narrow
normal
mildly dilated
moderately dilated
severely dilated
NA
posterior fossa
severely narrow
moderately narrow
mildly narrow
normal
mildly dilated
moderately dilated
severely dilated
NA
left
frontal
severely narrow
moderately narrow
mildly narrow
normal
mildly dilated
moderately dilated
severely dilated
NA
parietal
severely narrow
moderately narrow
mildly narrow
normal
mildly dilated
moderately dilated
severely dilated
NA
temporal
severely narrow
moderately narrow
mildly narrow
normal
mildly dilated
moderately dilated
severely dilated
NA
occipital
severely narrow
moderately narrow
mildly narrow
normal
mildly dilated
moderately dilated
severely dilated
NA
T1 T2 Findings
posterior fossa
severely narrow
moderately narrow
mildly narrow
normal
mildly dilated
moderately dilated
severely dilated
NA
Normal subarachnoid space
No
which side
severely narrow

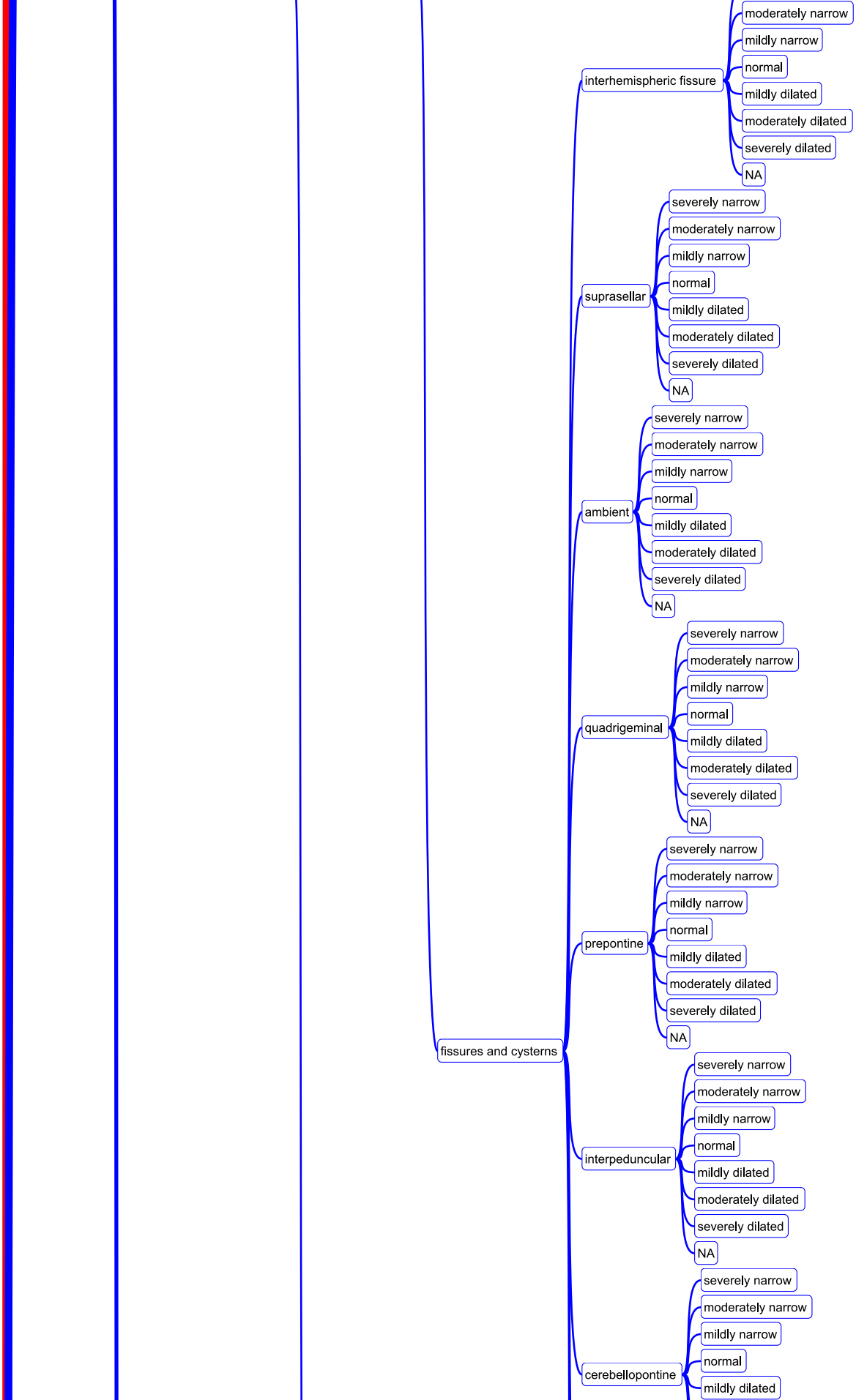
moderately narrow
mildly narrow
normal
mildly dilated
moderately dilated
severely dilated
NA
interhemispheric fissure
severely narrow
moderately narrow
mildly narrow
normal
mildly dilated
moderately dilated
severely dilated
NA
suprasellar
severely narrow
moderately narrow
mildly narrow
normal
mildly dilated
moderately dilated
severely dilated
NA
ambient
severely narrow
moderately narrow
mildly narrow
normal
mildly dilated
moderately dilated
severely dilated
NA
quadrigeminal
severely narrow
moderately narrow
mildly narrow
normal
mildly dilated
moderately dilated
severely dilated
NA
prepontine
fissures and cysterns
severely narrow
moderately narrow
mildly narrow
normal
mildly dilated
moderately dilated
severely dilated
NA
interpeduncular
severely narrow
moderately narrow
mildly narrow
normal
mildly dilated
cerebellopontine

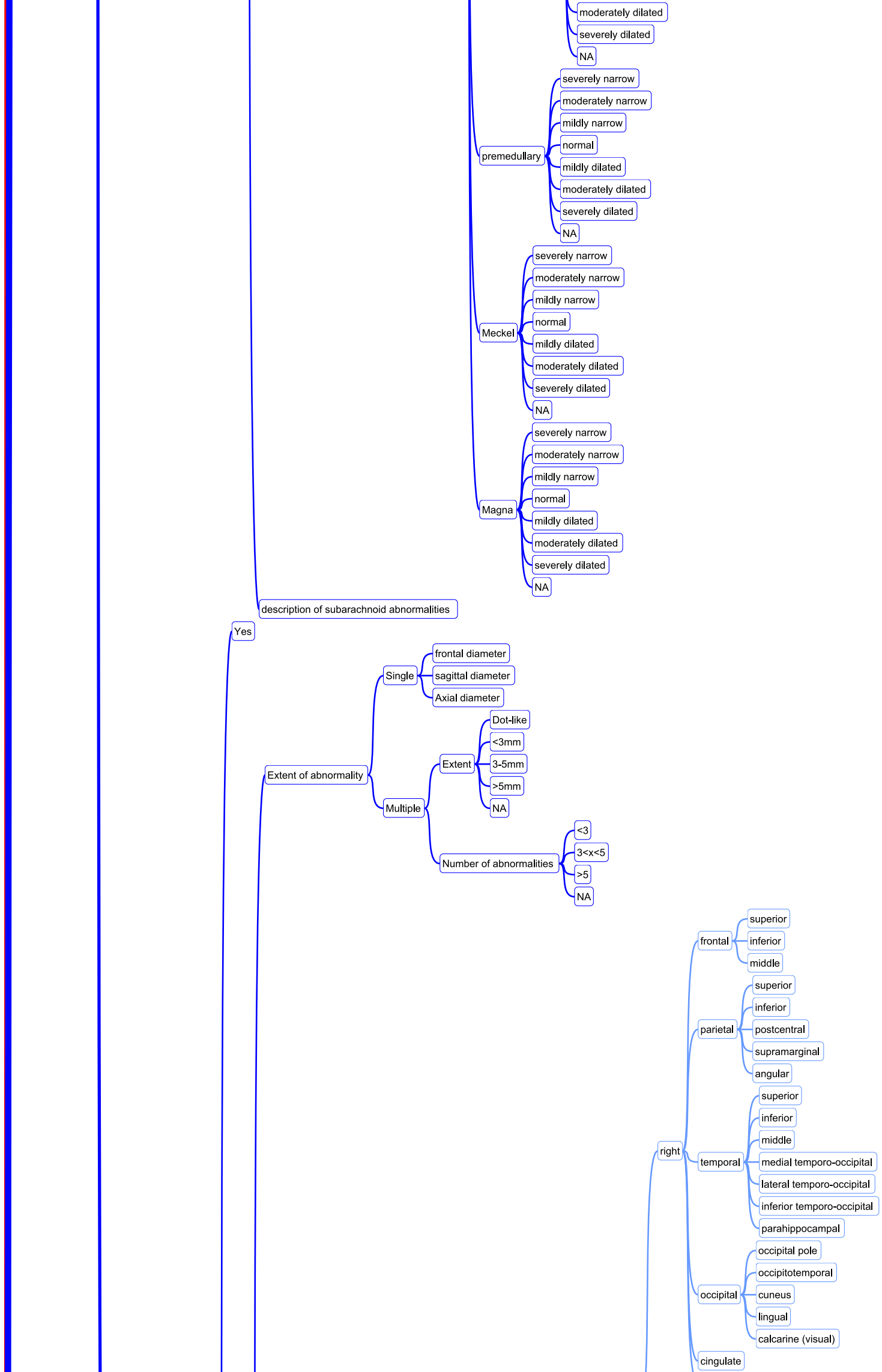
moderately dilated
severely dilated
NA
premedullary
severely narrow
moderately narrow
mildly narrow
normal
mildly dilated
moderately dilated
severely dilated
NA
Meckel
severely narrow
moderately narrow
mildly narrow
normal
mildly dilated
moderately dilated
severely dilated
NA
Magna
severely narrow
moderately narrow
mildly narrow
normal
mildly dilated
moderately dilated
severely dilated
NA
description of subarachnoid abnormalities
Yes
Extent of abnormality
Single
frontal diameter
sagittal diameter
Axial diameter
Multiple
Extent
Dot-like
<3mm
3-5mm
>5mm
NA
Number of abnormalities
<3
3<x<5
>5
NA
right
frontal
superior
inferior
middle
parietal
superior
inferior
postcentral
supramarginal
angular
temporal
superior
inferior
middle
medial temporo-occipital
lateral temporo-occipital
inferior temporo-occipital
parahippocampal
occipital
occipital pole
occipitotemporal
cuneus
lingual
calcarine (visual)
cingulate

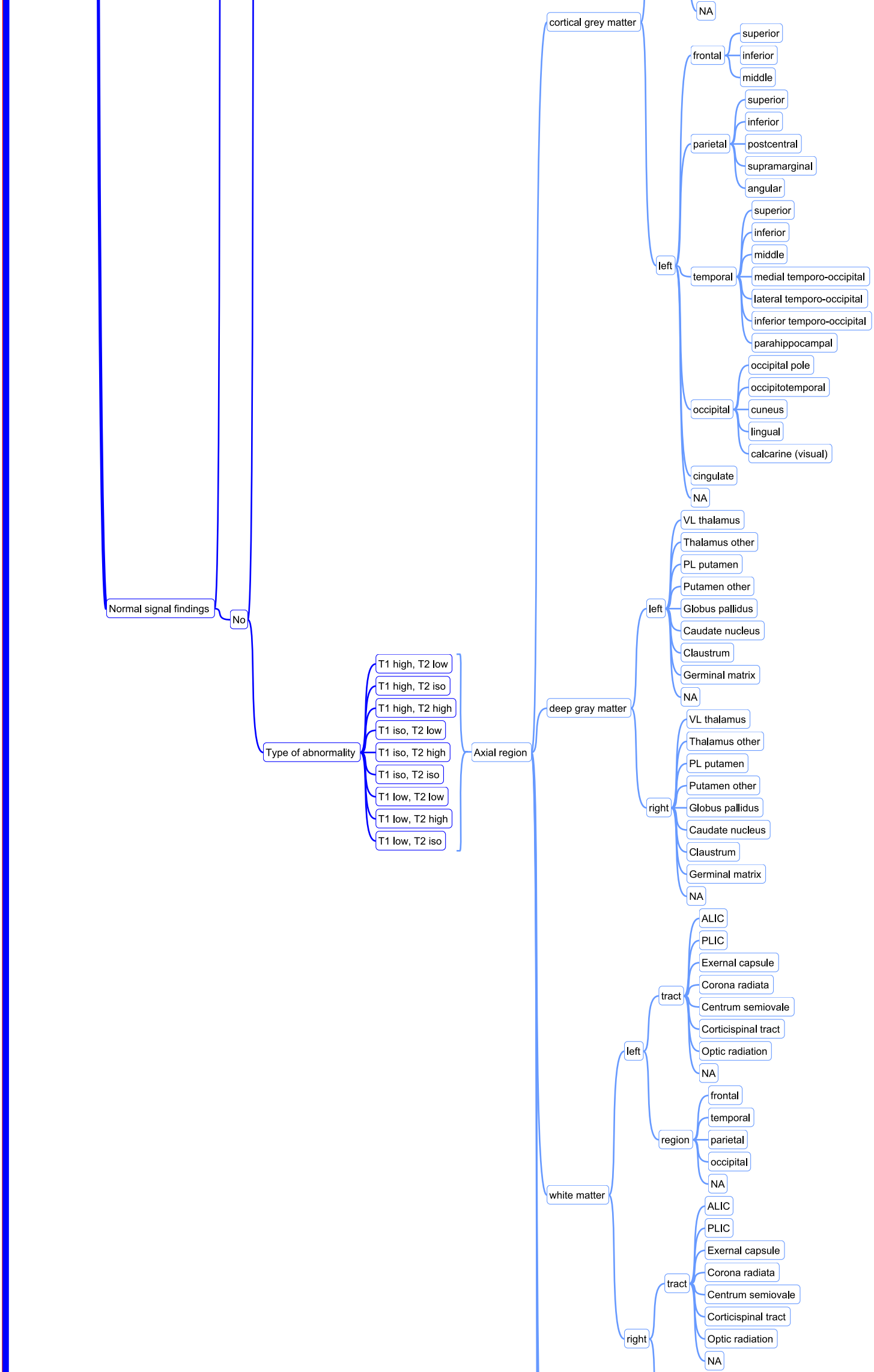
NA
cortical grey matter
frontal
superior
inferior
middle
parietal
superior
inferior
postcentral
supramarginal
angular
left
temporal
superior
inferior
middle
medial temporo-occipital
lateral temporo-occipital
inferior temporo-occipital
parahippocampal
occipital
occipital pole
occipitotemporal
cuneus
lingual
calcarine (visual)
cingulate
NA
Normal signal findings
No
Type of abnormality
T1 high, T2 low
T1 high, T2 iso
T1 high, T2 high
T1 iso, T2 low
T1 iso, T2 high
T1 iso, T2 iso
T1 low, T2 low
T1 low, T2 high
T1 low, T2 iso
Axial region
deep gray matter
left
VL thalamus
Thalamus other
PL putamen
Putamen other
Globus pallidus
Caudate nucleus
Claustrum
Germinal matrix
NA
right
VL thalamus
Thalamus other
PL putamen
Putamen other
Globus pallidus
Caudate nucleus
Claustrum
Germinal matrix
NA
white matter
left
tract
ALIC
PLIC
Exernal capsule
Corona radiata
Centrum semiovale
Corticispinal tract
Optic radiation
NA
region
frontal
temporal
parietal
occipital
NA
right
tract
ALIC
PLIC
Exernal capsule
Corona radiata
Centrum semiovale
Corticispinal tract
Optic radiation
NA

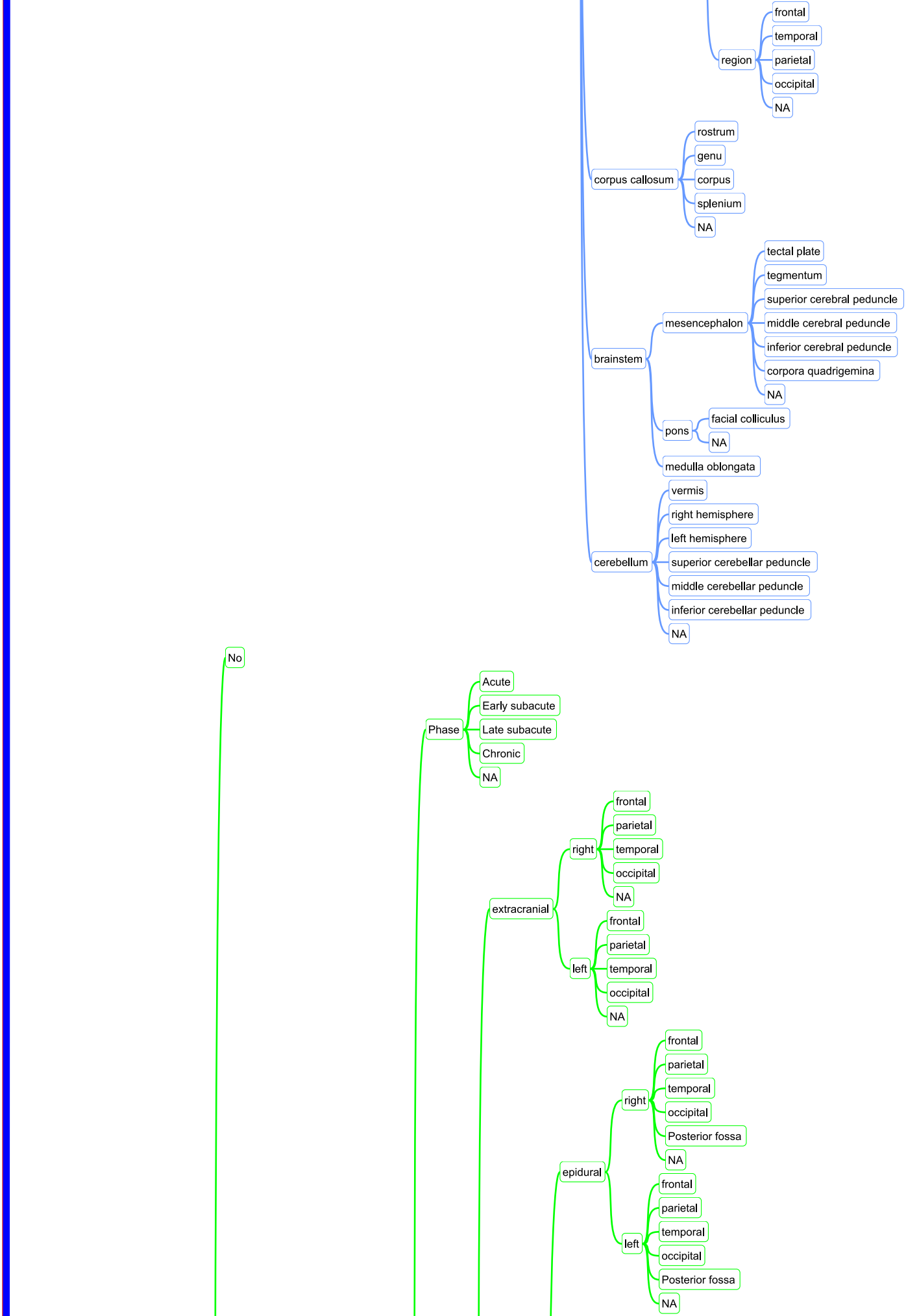
frontal
temporal
parietal
occipital
NA
region
rostrum
genu
corpus
splenium
NA
corpus callosum
tectal plate
tegmentum
superior cerebral peduncle
middle cerebral peduncle
inferior cerebral peduncle
corpora quadrigemina
NA
mesencephalon
brainstem
facial colliculus
NA
pons
medulla oblongata
vermis
right hemisphere
left hemisphere
superior cerebellar peduncle
middle cerebellar peduncle
inferior cerebellar peduncle
NA
cerebellum
No
Acute
Early subacute
Late subacute
Chronic
NA
Phase
frontal
parietal
temporal
occipital
NA
right
extracranial
frontal
parietal
temporal
occipital
NA
left
frontal
parietal
temporal
occipital
Posterior fossa
NA
right
epidural
frontal
parietal
temporal
occipital
Posterior fossa
NA
left

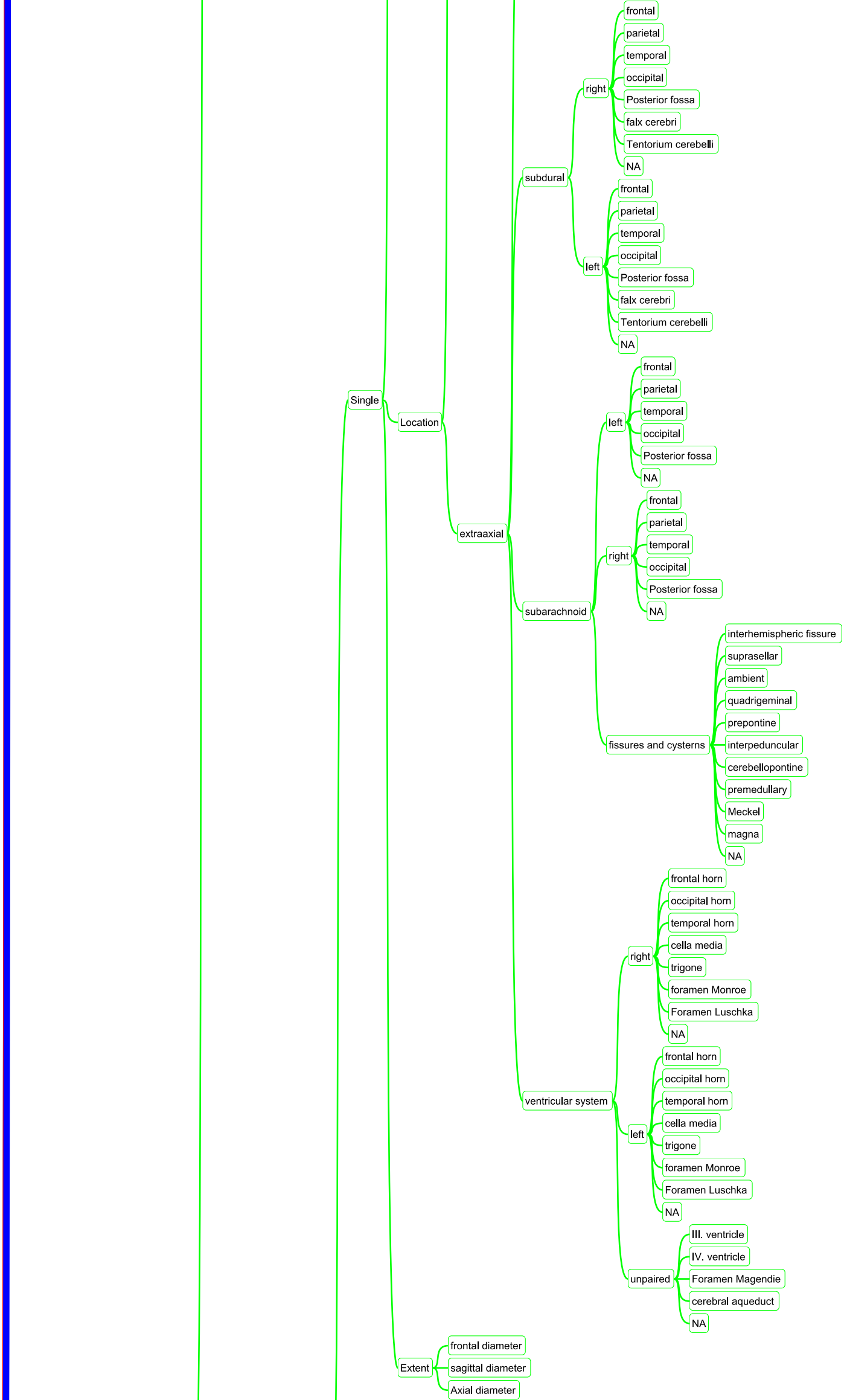
Single
Location
extraaxial
subdural
right
frontal
parietal
temporal
occipital
Posterior fossa
falx cerebri
Tentorium cerebelli
NA
left
frontal
parietal
temporal
occipital
Posterior fossa
falx cerebri
Tentorium cerebelli
NA
subarachnoid
left
frontal
parietal
temporal
occipital
Posterior fossa
NA
right
frontal
parietal
temporal
occipital
Posterior fossa
NA
fissures and cysterns
interhemispheric fissure
suprasellar
ambient
quadrigeminal
prepontine
interpeduncular
cerebellopontine
premedullary
Meckel
magna
NA
ventricular system
right
frontal horn
occipital horn
temporal horn
cella media
trigone
foramen Monroe
Foramen Luschka
NA
left
frontal horn
occipital horn
temporal horn
cella media
trigone
foramen Monroe
Foramen Luschka
NA
unpaired
III. ventricle
IV. ventricle
Foramen Magendie
cerebral aqueduct
NA
Extent
frontal diameter
sagittal diameter
Axial diameter

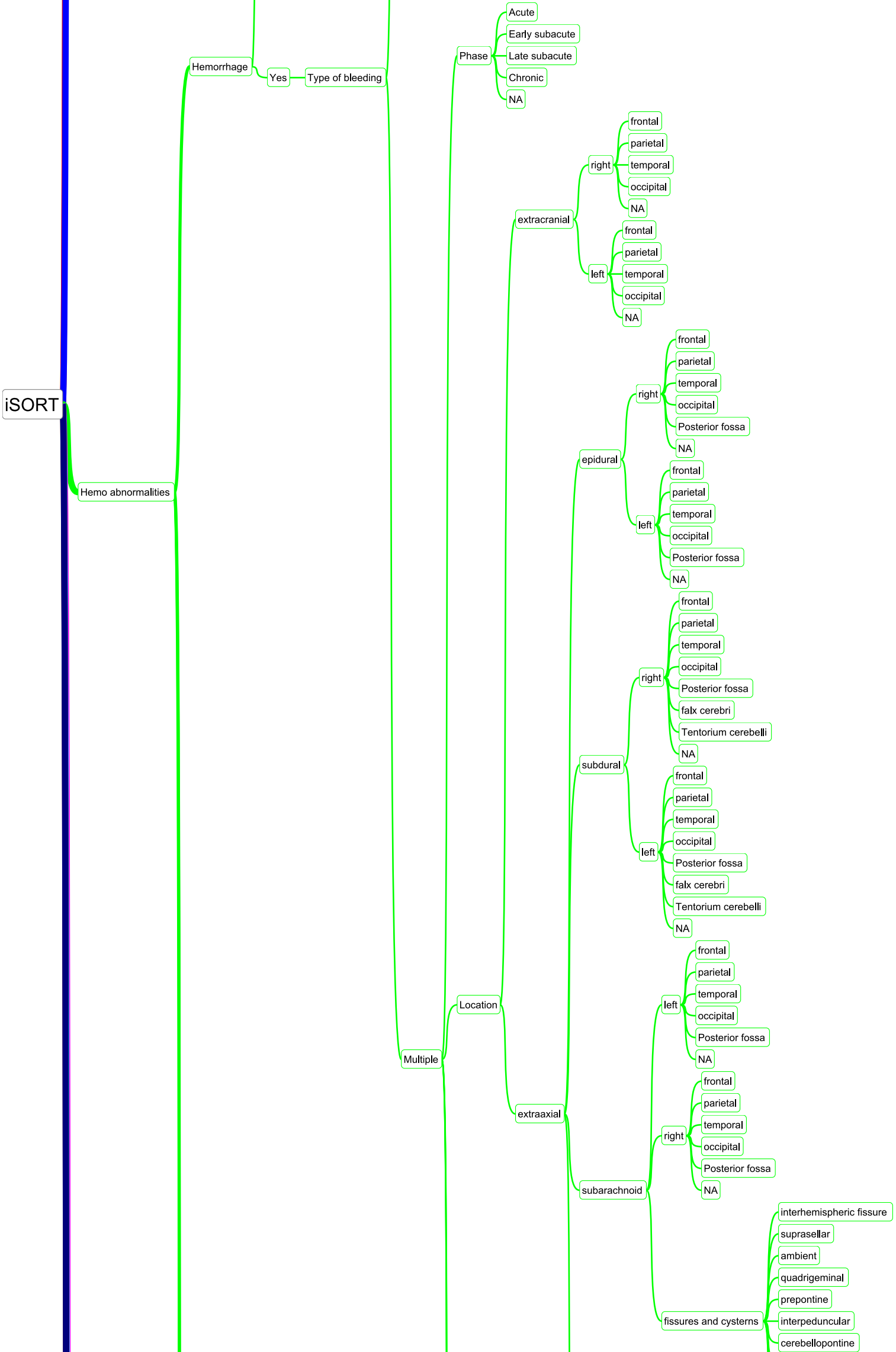
iSORT
Hemo abnormalities
Hemorrhage
Yes
Type of bleeding
Multiple
Phase
Acute
Early subacute
Late subacute
Chronic
NA
Location
extracranial
right
frontal
parietal
temporal
occipital
NA
left
frontal
parietal
temporal
occipital
NA
extraaxial
epidural
right
frontal
parietal
temporal
occipital
Posterior fossa
NA
left
frontal
parietal
temporal
occipital
Posterior fossa
NA
subdural
right
frontal
parietal
temporal
occipital
Posterior fossa
falx cerebri
Tentorium cerebelli
NA
left
frontal
parietal
temporal
occipital
Posterior fossa
falx cerebri
Tentorium cerebelli
NA
subarachnoid
left
frontal
parietal
temporal
occipital
Posterior fossa
NA
right
frontal
parietal
temporal
occipital
Posterior fossa
NA
fissures and cysterns
interhemispheric fissure
suprasellar
ambient
quadrigeminal
prepontine
interpeduncular
cerebellopontine

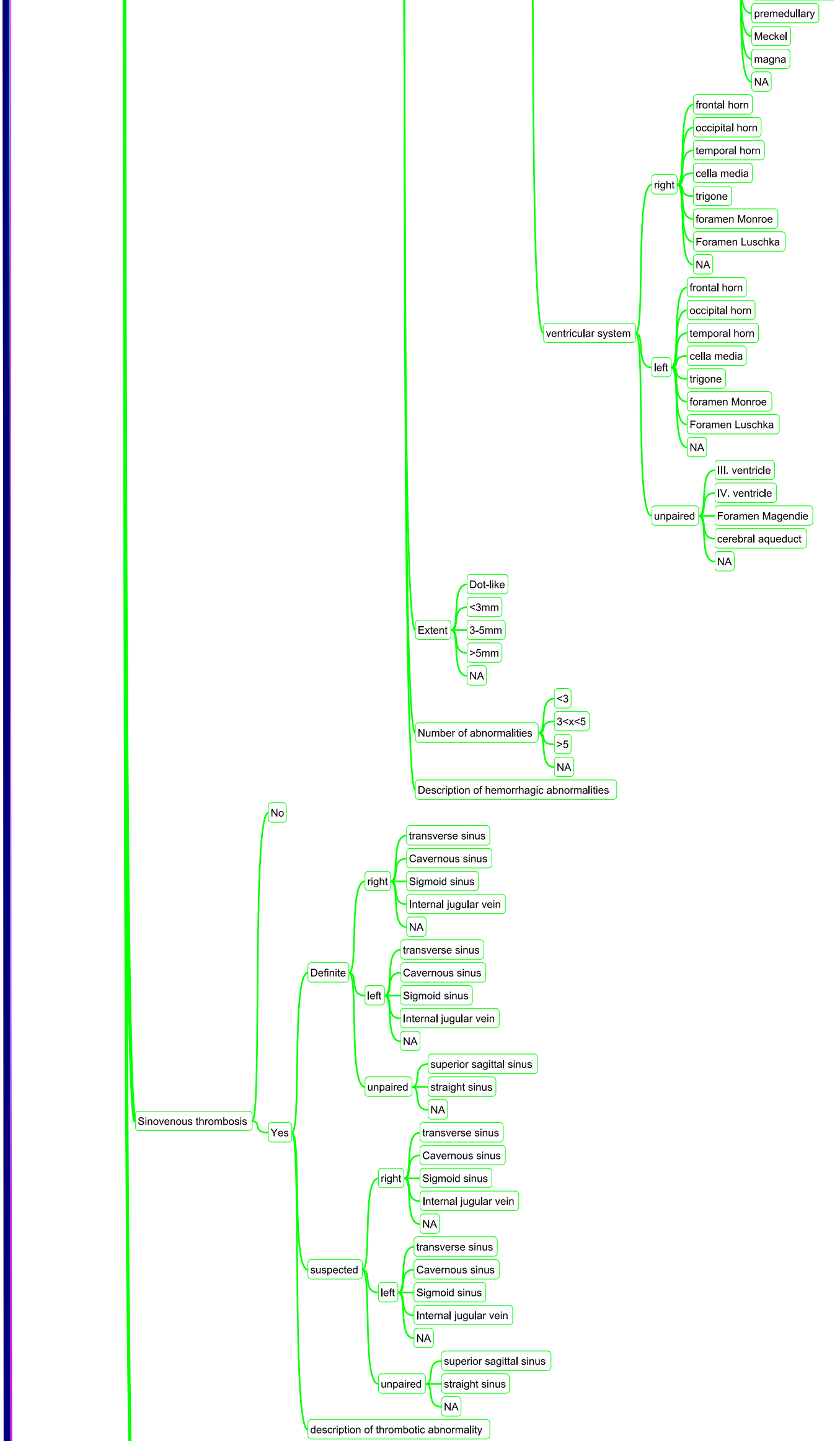
premedullary
Meckel
magna
NA
frontal horn
occipital horn
temporal horn
cella media
trigone
foramen Monroe
Foramen Luschka
NA
right
ventricular system
frontal horn
occipital horn
temporal horn
cella media
trigone
foramen Monroe
Foramen Luschka
NA
left
III. ventricle
IV. ventricle
Foramen Magendie
cerebral aqueduct
NA
unpaired
Dot-like
<3mm
3-5mm
>5mm
NA
Extent
<3
3<x<5
>5
NA
Number of abnormalities
Description of hemorrhagic abnormalities
No
transverse sinus
Cavernous sinus
Sigmoid sinus
Internal jugular vein
NA
right
transverse sinus
Cavernous sinus
Sigmoid sinus
Internal jugular vein
NA
left
Definite
superior sagittal sinus
straight sinus
NA
unpaired
Sinovenous thrombosis
Yes
transverse sinus
Cavernous sinus
Sigmoid sinus
Internal jugular vein
NA
right
transverse sinus
Cavernous sinus
Sigmoid sinus
Internal jugular vein
NA
left
suspected
superior sagittal sinus
straight sinus
NA
unpaired
description of thrombotic abnormality

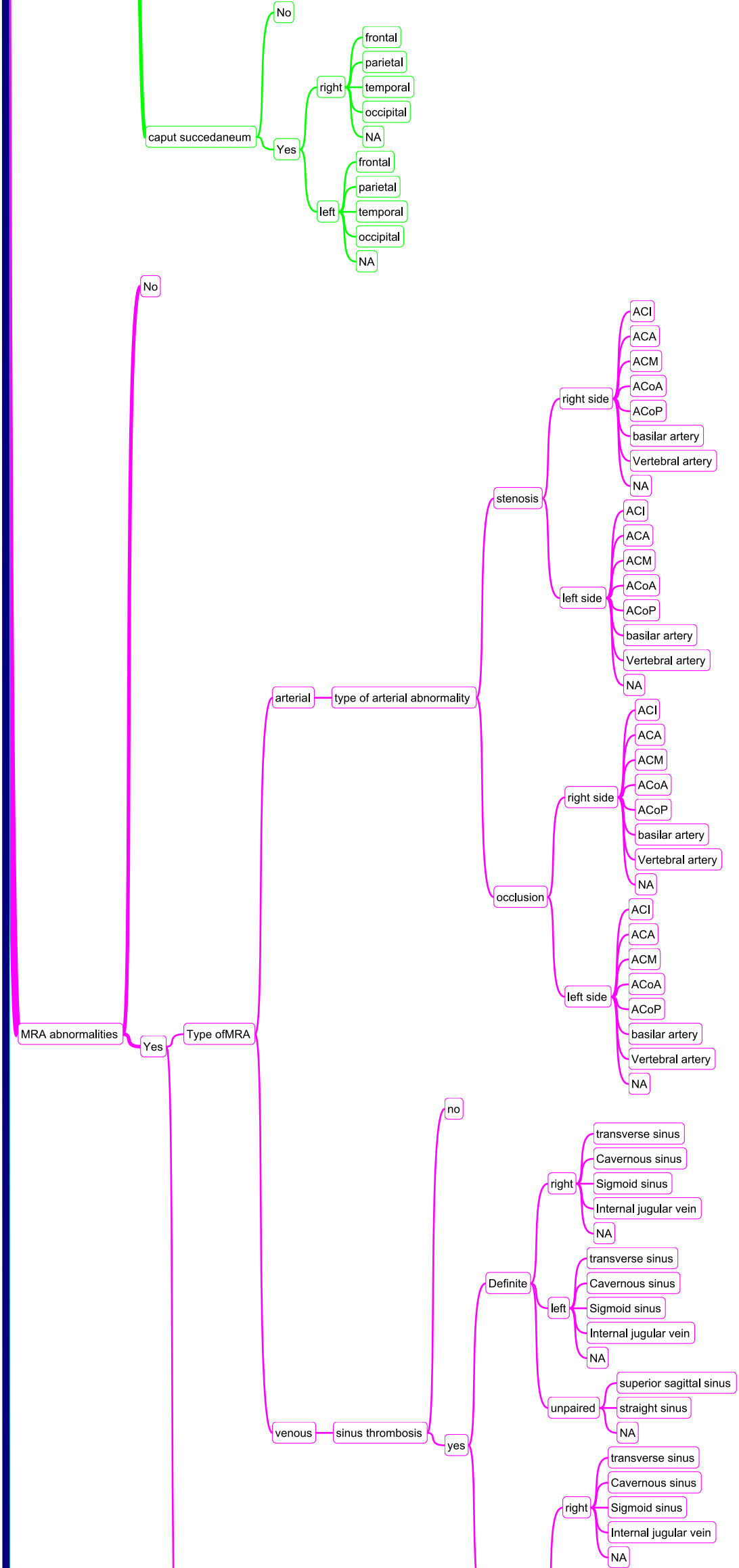
caput succedaneum
No
Yes
right
frontal
parietal
temporal
occipital
NA
left
frontal
parietal
temporal
occipital
NA
MRA abnormalities
No
Yes
Type ofMRA
arterial
type of arterial abnormality
stenosis
right side
ACI
ACA
ACM
ACoA
ACoP
basilar artery
Vertebral artery
NA
left side
ACI
ACA
ACM
ACoA
ACoP
basilar artery
Vertebral artery
NA
occlusion
right side
ACI
ACA
ACM
ACoA
ACoP
basilar artery
Vertebral artery
NA
left side
ACI
ACA
ACM
ACoA
ACoP
basilar artery
Vertebral artery
NA
venous
sinus thrombosis
no
yes
Definite
right
transverse sinus
Cavernous sinus
Sigmoid sinus
Internal jugular vein
NA
left
transverse sinus
Cavernous sinus
Sigmoid sinus
Internal jugular vein
NA
unpaired
superior sagittal sinus
straight sinus
NA
right
transverse sinus
Cavernous sinus
Sigmoid sinus
Internal jugular vein
NA

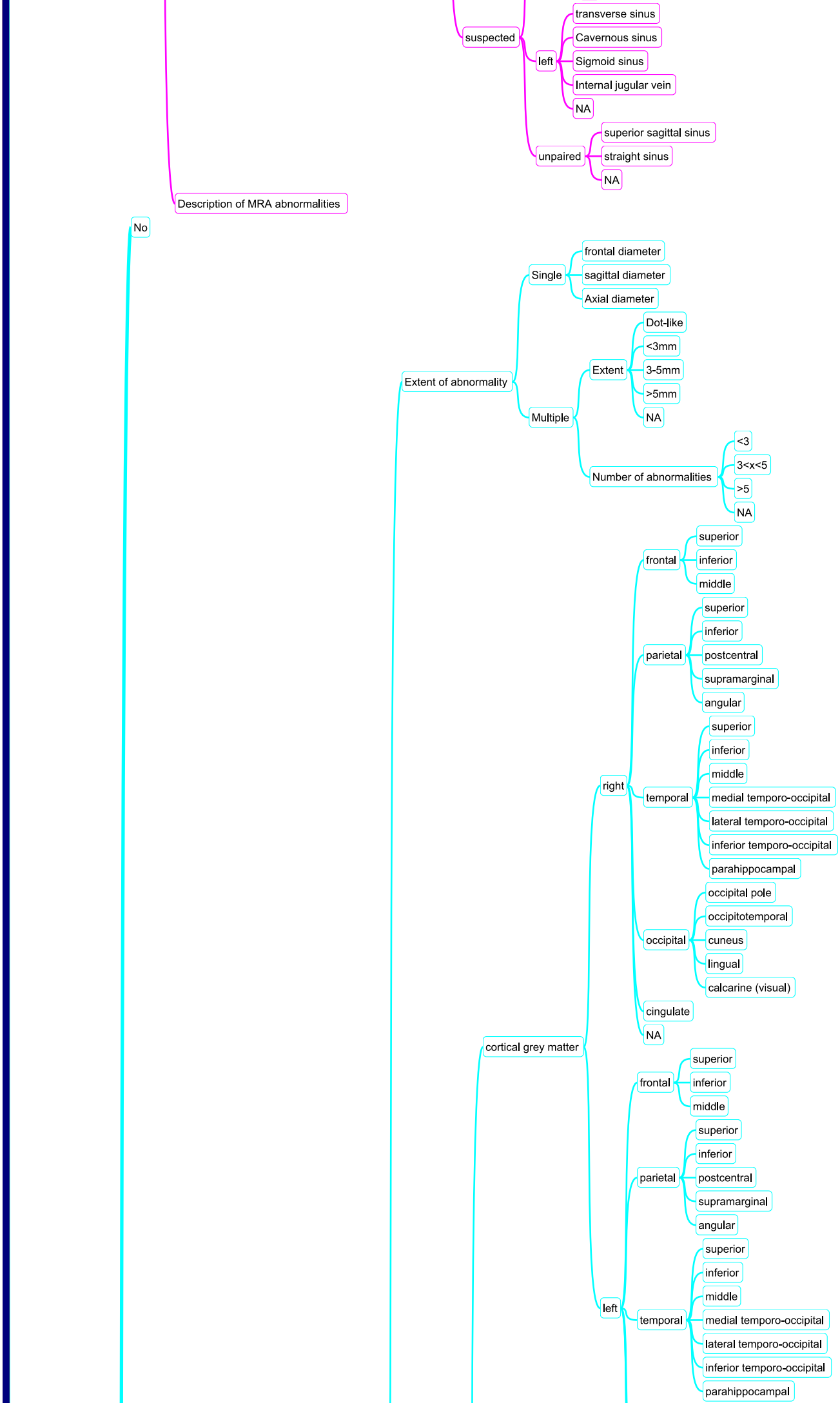
suspected
transverse sinus
Cavernous sinus
left
Sigmoid sinus
Internal jugular vein
NA
superior sagittal sinus
unpaired
straight sinus
NA
Description of MRA abnormalities
No
frontal diameter
Single
sagittal diameter
Axial diameter
Dot-like
<3mm
Extent of abnormality
Extent
3-5mm
>5mm
Multiple
NA
<3
3<x<5
Number of abnormalities
>5
NA
superior
frontal
inferior
middle
superior
inferior
parietal
postcentral
supramarginal
angular
superior
inferior
middle
right
temporal
medial temporo-occipital
lateral temporo-occipital
inferior temporo-occipital
parahippocampal
occipital pole
occipitotemporal
occipital
cuneus
lingual
calcarine (visual)
cingulate
NA
cortical grey matter
superior
frontal
inferior
middle
superior
inferior
parietal
postcentral
supramarginal
angular
superior
inferior
middle
left
temporal
medial temporo-occipital
lateral temporo-occipital
inferior temporo-occipital
parahippocampal

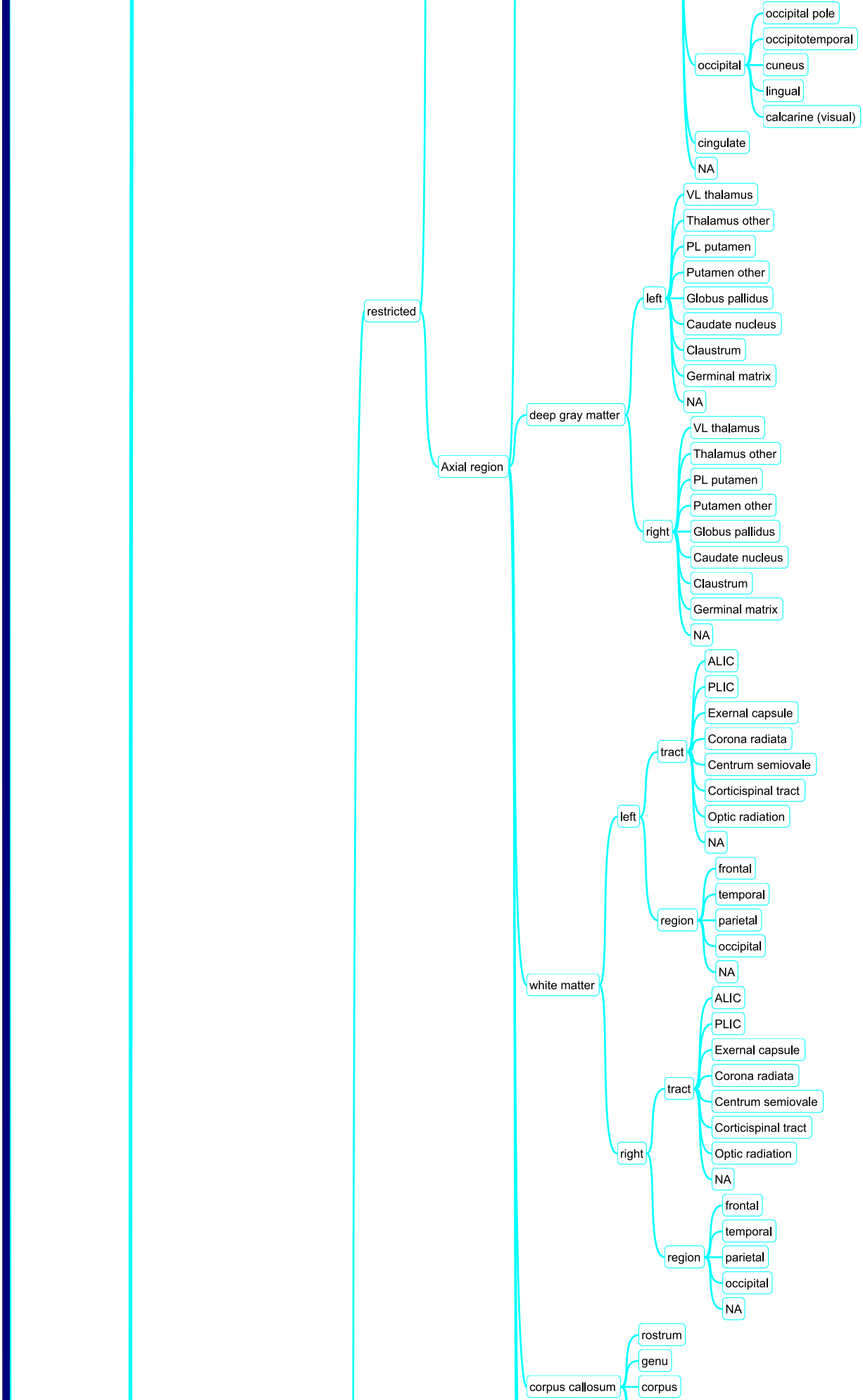
occipital pole
occipitotemporal
occipital
cuneus
lingual
calcarine (visual)
cingulate
NA
restricted
VL thalamus
Thalamus other
PL putamen
Putamen other
left
Globus pallidus
Caudate nucleus
Claustrum
Germinal matrix
NA
deep gray matter
Axial region
VL thalamus
Thalamus other
PL putamen
Putamen other
right
Globus pallidus
Caudate nucleus
Claustrum
Germinal matrix
NA
ALIC
PLIC
Exernal capsule
Corona radiata
tract
Centrum semiovale
Corticispinal tract
left
Optic radiation
NA
frontal
temporal
region
parietal
occipital
NA
white matter
ALIC
PLIC
Exernal capsule
Corona radiata
tract
Centrum semiovale
Corticispinal tract
right
Optic radiation
NA
frontal
temporal
region
parietal
occipital
NA
rostrum
genu
corpus callosum
corpus

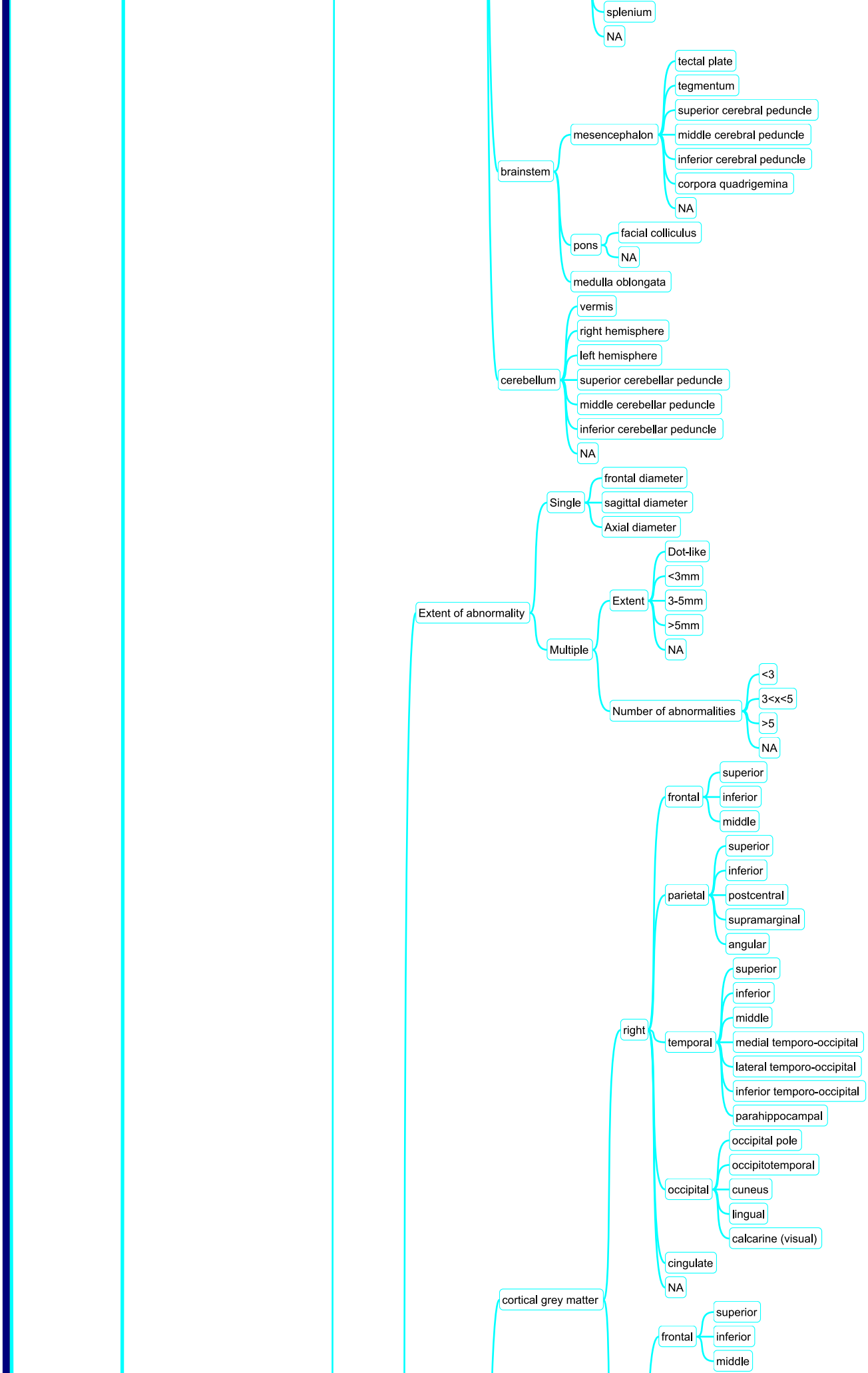
splenium
NA
tectal plate
tegmentum
superior cerebral peduncle
middle cerebral peduncle
inferior cerebral peduncle
corpora quadrigemina
NA
mesencephalon
brainstem
facial colliculus
NA
pons
medulla oblongata
vermis
right hemisphere
left hemisphere
cerebellum
superior cerebellar peduncle
middle cerebellar peduncle
inferior cerebellar peduncle
NA
frontal diameter
Single
sagittal diameter
Axial diameter
Dot-like
<3mm
Extent of abnormality
Extent
3-5mm
>5mm
Multiple
NA
<3
3<x<5
Number of abnormalities
>5
NA
superior
frontal
inferior
middle
superior
inferior
parietal
postcentral
supramarginal
angular
superior
inferior
middle
right
temporal
medial temporo-occipital
lateral temporo-occipital
inferior temporo-occipital
parahippocampal
occipital pole
occipitotemporal
occipital
cuneus
lingual
calcarine (visual)
cingulate
NA
cortical grey matter
superior
frontal
inferior
middle

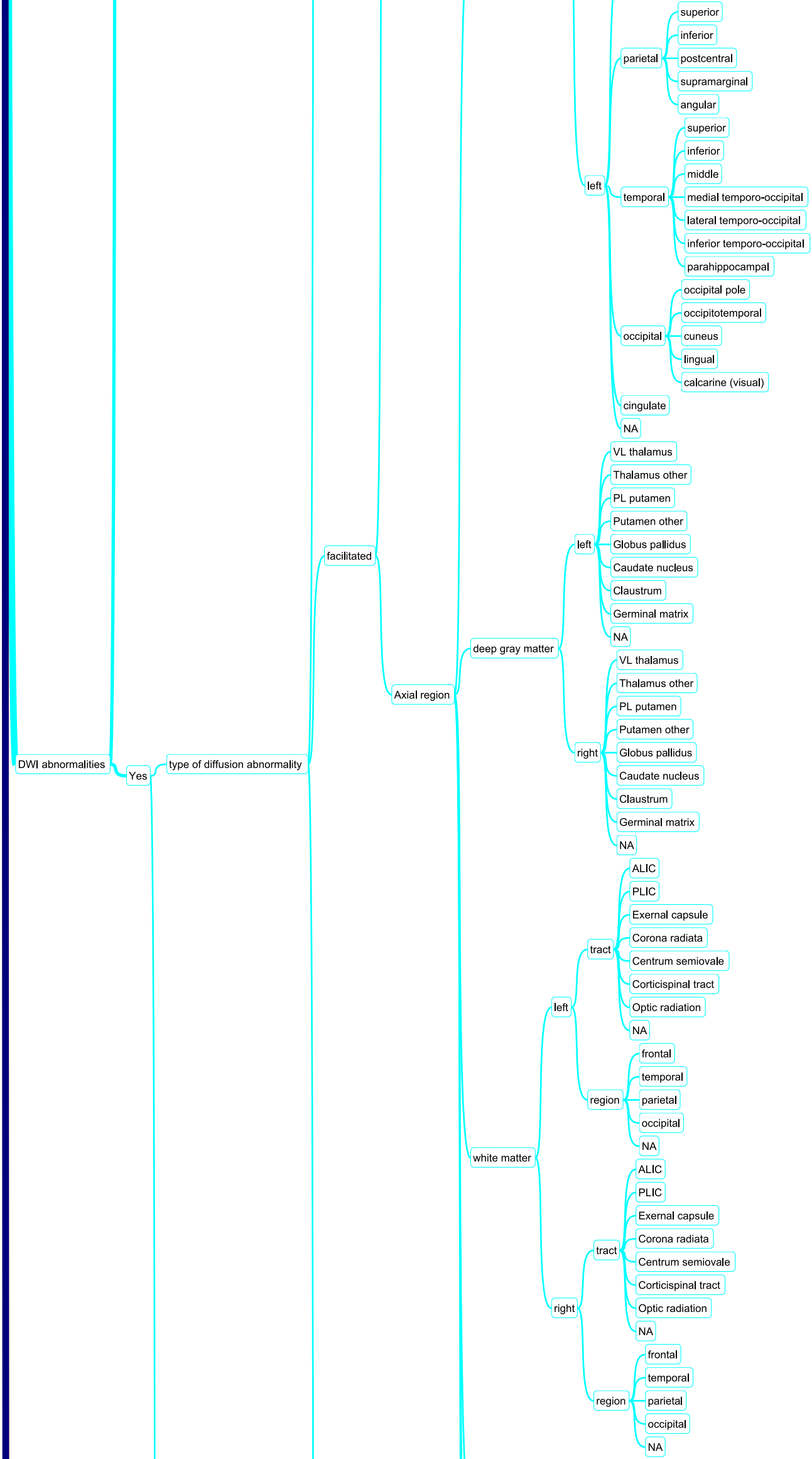
superior
inferior
parietal
postcentral
supramarginal
angular
superior
inferior
middle
left
temporal
medial temporo-occipital
lateral temporo-occipital
inferior temporo-occipital
parahippocampal
occipital pole
occipitotemporal
occipital
cuneus
lingual
calcarine (visual)
cingulate
NA
VL thalamus
Thalamus other
PL putamen
Putamen other
left
Globus pallidus
facilitated
Caudate nucleus
Claustrum
Germinal matrix
NA
deep gray matter
VL thalamus
Thalamus other
Axial region
PL putamen
Putamen other
right
Globus pallidus
DWI abnormalities
Yes
type of diffusion abnormality
Caudate nucleus
Claustrum
Germinal matrix
NA
ALIC
PLIC
Exernal capsule
Corona radiata
tract
Centrum semiovale
Corticispinal tract
left
Optic radiation
NA
frontal
temporal
region
parietal
occipital
NA
white matter
ALIC
PLIC
Exernal capsule
Corona radiata
tract
Centrum semiovale
Corticispinal tract
right
Optic radiation
NA
frontal
temporal
region
parietal
occipital
NA

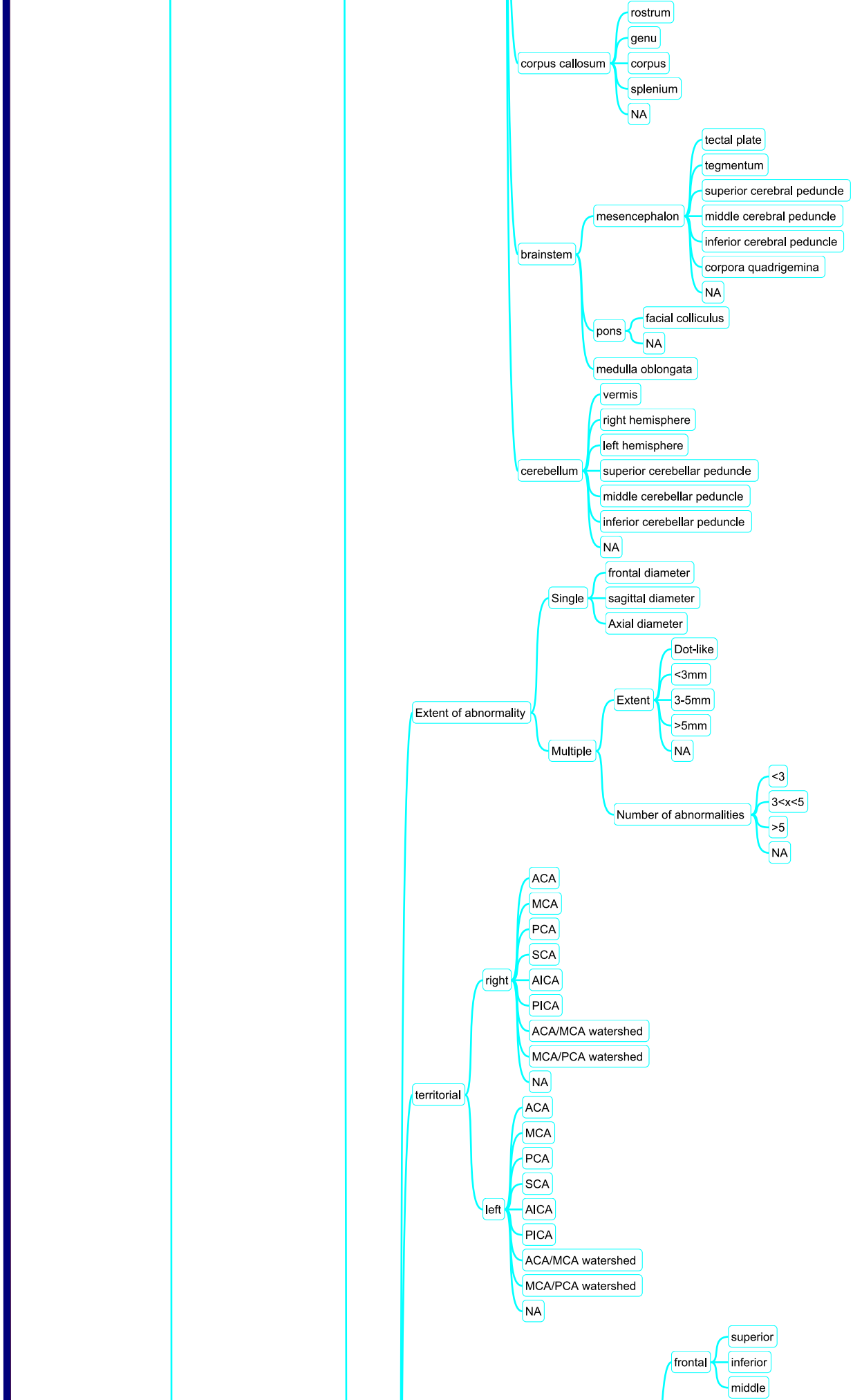
rostrum
genu
corpus callosum
corpus
splenium
NA
tectal plate
tegmentum
superior cerebral peduncle
mesencephalon
middle cerebral peduncle
inferior cerebral peduncle
brainstem
corpora quadrigemina
NA
facial colliculus
pons
NA
medulla oblongata
vermis
right hemisphere
left hemisphere
cerebellum
superior cerebellar peduncle
middle cerebellar peduncle
inferior cerebellar peduncle
NA
frontal diameter
Single
sagittal diameter
Axial diameter
Dot-like
<3mm
Extent of abnormality
Extent
3-5mm
>5mm
Multiple
NA
<3
3<x<5
Number of abnormalities
>5
NA
ACA
MCA
PCA
SCA
right
AICA
PICA
ACA/MCA watershed
MCA/PCA watershed
territorial
NA
ACA
MCA
PCA
SCA
left
AICA
PICA
ACA/MCA watershed
MCA/PCA watershed
NA
superior
frontal
inferior
middle

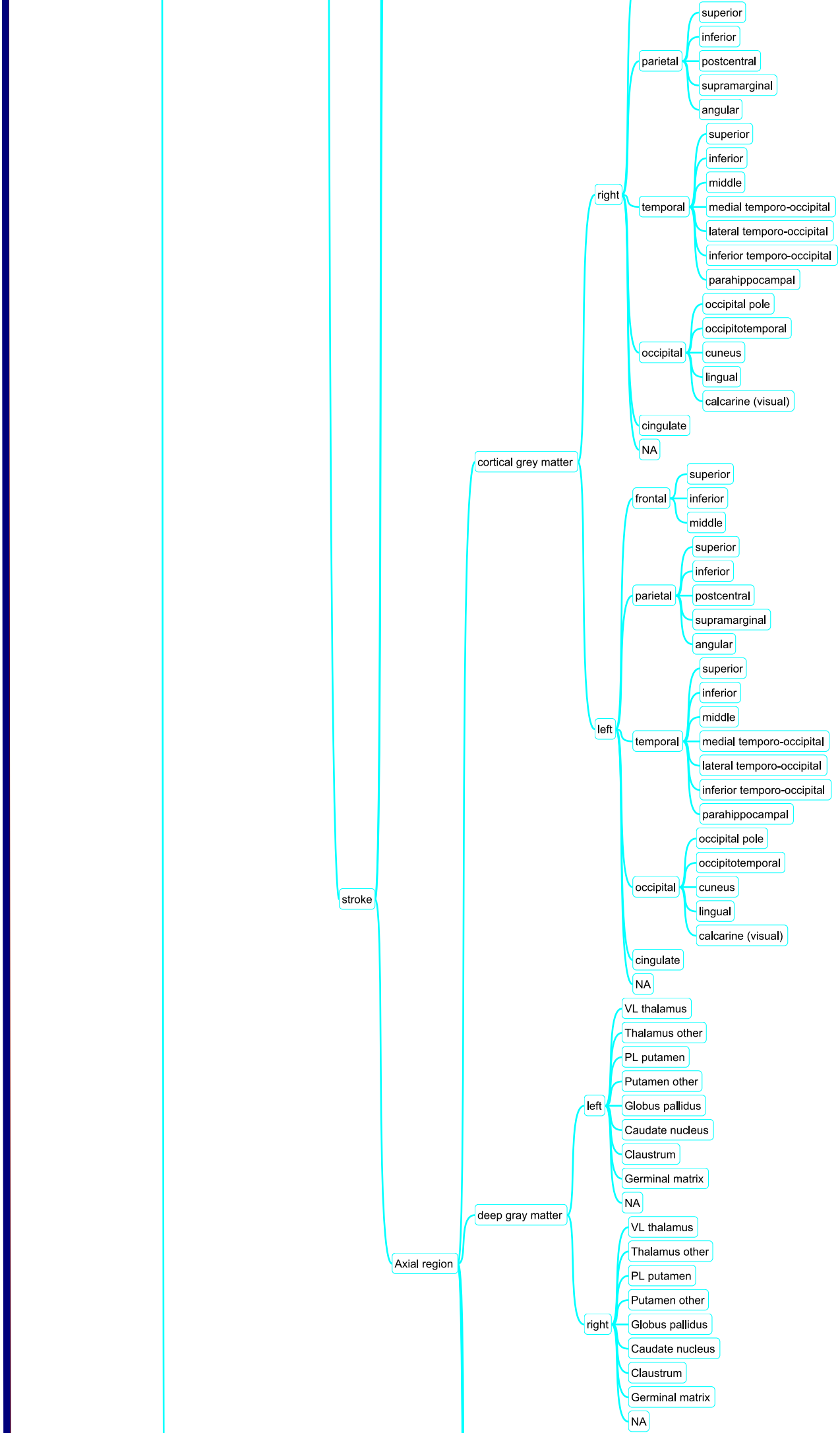
superior
inferior
parietal
postcentral
supramarginal
angular
superior
inferior
middle
right
temporal
medial temporo-occipital
lateral temporo-occipital
inferior temporo-occipital
parahippocampal
occipital pole
occipitotemporal
occipital
cuneus
lingual
calcarine (visual)
cingulate
NA
cortical grey matter
superior
frontal
inferior
middle
superior
inferior
parietal
postcentral
supramarginal
angular
superior
inferior
middle
left
temporal
medial temporo-occipital
lateral temporo-occipital
inferior temporo-occipital
parahippocampal
occipital pole
occipitotemporal
stroke
occipital
cuneus
lingual
calcarine (visual)
cingulate
NA
VL thalamus
Thalamus other
PL putamen
Putamen other
left
Globus pallidus
Caudate nucleus
Claustrum
Germinal matrix
NA
deep gray matter
VL thalamus
Axial region
Thalamus other
PL putamen
Putamen other
right
Globus pallidus
Caudate nucleus
Claustrum
Germinal matrix
NA

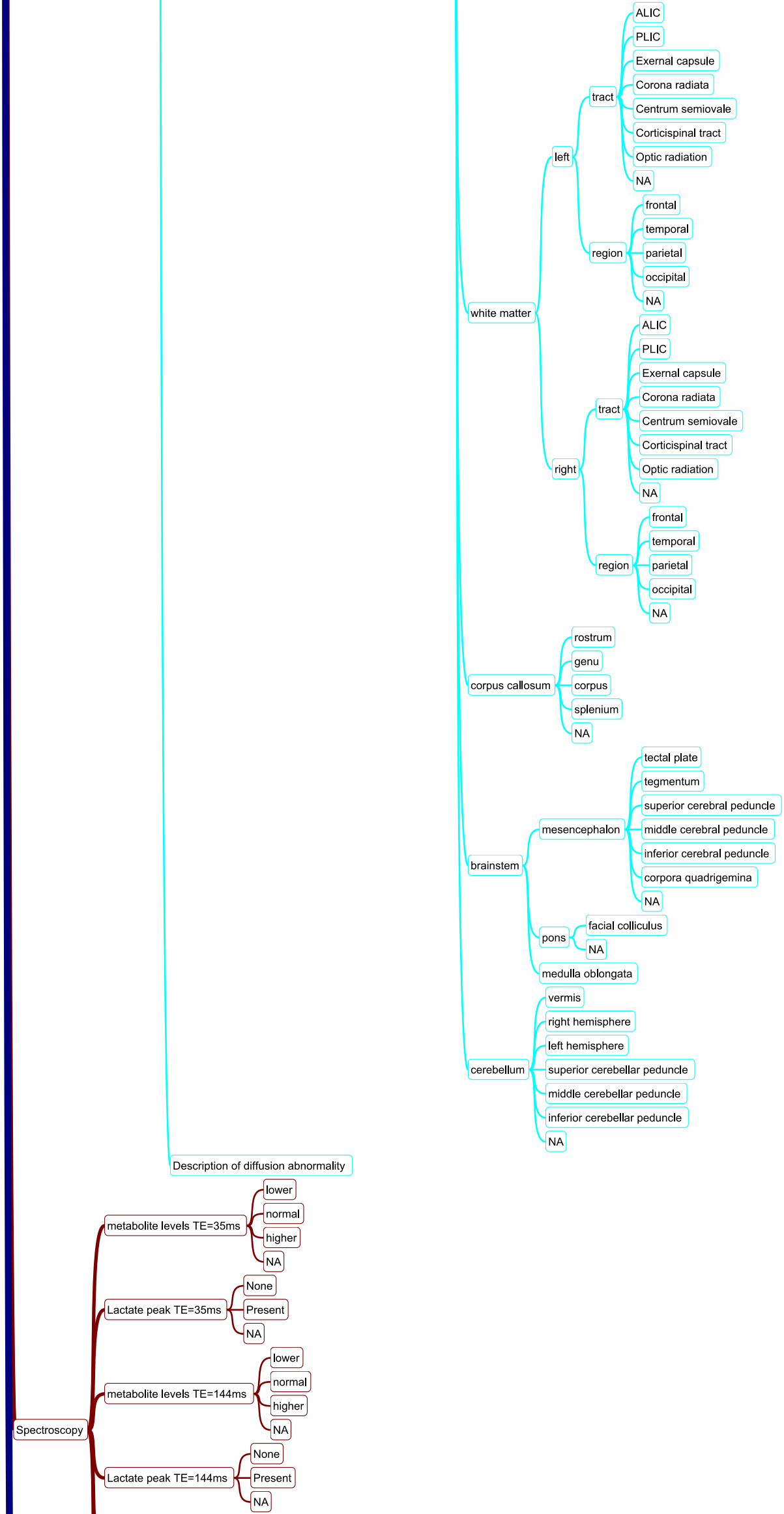
ALIC
PLIC
Exernal capsule
Corona radiata
Centrum semiovale
Corticispinal tract
Optic radiation
NA
tract
left
frontal
temporal
parietal
occipital
NA
region
white matter
ALIC
PLIC
Exernal capsule
Corona radiata
Centrum semiovale
Corticispinal tract
Optic radiation
NA
tract
right
frontal
temporal
parietal
occipital
NA
region
rostrum
genu
corpus callosum
corpus
splenium
NA
tectal plate
tegmentum
superior cerebral peduncle
mesencephalon
middle cerebral peduncle
inferior cerebral peduncle
corpora quadrigemina
NA
brainstem
facial colliculus
pons
NA
medulla oblongata
vermis
right hemisphere
left hemisphere
cerebellum
superior cerebellar peduncle
middle cerebellar peduncle
inferior cerebellar peduncle
NA
Description of diffusion abnormality
lower
normal
metabolite levels TE=35ms
higher
NA
None
Lactate peak TE=35ms
Present
NA
lower
normal
metabolite levels TE=144ms
higher
Spectroscopy
NA
None
Lactate peak TE=144ms
Present
NA

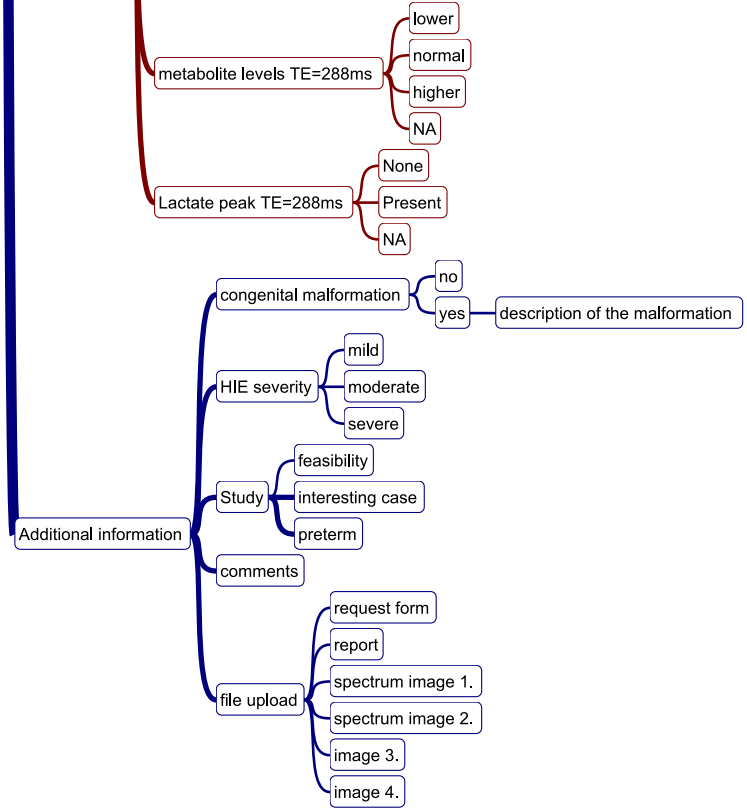
metabolite levels TE=288ms
lower
normal
higher
NA
Lactate peak TE=288ms
None
Present
NA
Additional information
congenital malformation
no
yes
description of the malformation
HIE severity
mild
moderate
severe
Study
feasibility
interesting case
preterm
comments
file upload
request form
report
spectrum image 1.
spectrum image 2.
image 3.
image 4.

Supplementary Figure 1. Tree representation of the iSORT template.
Note, that for brevity we joined the representation of different signal abnormalities in the "T1 T2 Findings" / "Normal signal findings" / "No" / "Type of abnormality" branch.