



New insights in the investigation of trepanations from the Carpathian Basin

Kitty Király¹ · Orsolya Anna Váradi^{1,2} · Luca Kis^{1,2} · Réka Nagy¹ · Gréta Elekes³ · Mátyás Bukva^{4,5,6} · Balázs Tihanyi^{1,2} · Olga Spekker¹ · Antónia Marcsik¹ · Erika Molnár¹ · György Pálfi¹ · Zsolt Bereczki¹

Received: 15 December 2021 / Accepted: 13 March 2022 / Published online: 29 March 2022
© The Author(s) 2022

Abstract

The aim of this study is to describe four new cases of trepanation from the Great Hungarian Plain and complement two other previously published cases with new results from the 9th to 16th c. CE. Sex determination and age-at-death estimation were performed using classical macromorphological methods. In certain cases, radiographic imaging, 3D scanning, and radiocarbon dating were also performed. Our cases fit the formerly established understanding of trepanations, with a male majority and signs of trauma as accompanying symptoms. The cause of intervention was mostly therapeutic, i.e., trauma, in most cases. In order to simplify the currently confusing nomenclature in trepanation categories (complete–incomplete vs. surgical–symbolic), we propose the use of “trepanation” exclusively to all forms of intentional, non-violent removals of all three layers of the cranial vault. On the other hand, the phenomena widely known in Eastern Europe as symbolic trepanations should be designated as “cranioglyphs,” referring to all forms of superficial interventions administered to the cranial vault that do not penetrate all three layers of the bone. In case the data are insufficient to properly categorize the phenomenon at hand, one should refrain from it, and simply describe the lesion as intentional cranial intervention. In order to bring spotlight to the wide range of cranial interventions in the early medieval Carpathian Basin, our team is conducting several research projects, in order to contribute to a better understanding of these traditions in the future.

Keywords Trepanation · Symbolic trepanation · Cranioglyph · Medieval · Hungary · Carpathian Basin · Nomenclature · Indication

Introduction

Trepanation is an intentional surgical procedure during which a piece of the cranial vault is removed (Aufderheide and Rodriguez-Martin, 1998; Arnott et al. 2003; Ortner 2003). Trepanation occurred among numerous ancient populations around the globe (Lisowski 1967; Campillo 1984; Furnas et al. 1985; Arnott et al. 2003; Ortner 2003). In the international literature, the traditional categorization of trepanations is based on preparation techniques (rectangular intersecting cuts, scraping, grooving, and drilling with cutting); however, different authors tend to include different methodologies under the same nomenclature (cf. Lisowski 1967; Aufderheide and Rodriguez-Martin 1998; Arnott et al. 2003; Ortner 2003; Gross 2009; Verano 2016). Among the trepanations of the Carpathian Basin, drilling and rectangular cutting have not been proven to occur, but scraping and grooving methods are common (Anda 1951; Nemeskéri et al. 1965; Bartucz 1966; Józsa and Fóthi 2007).

✉ Kitty Király
kiraly.kitty@bio.u-szeged.hu

- ¹ Department of Biological Anthropology, University of Szeged, Szeged, Hungary
- ² Department of Archaeogenetics, Institute of Hungarian Research, Budapest, Hungary
- ³ Department of Ophthalmology, University of Szeged, Szeged, Hungary
- ⁴ Laboratory of Microscopic Image Analysis and Machine Learning, Biological Research Centre, Szeged, Hungary
- ⁵ Institute of Biochemistry, Eötvös Loránd Research Network (ELKH), Szeged, Hungary
- ⁶ Department of Immunology, University of Szeged, Szeged, Hungary

According to Ortner's (2003) description of the scraping technique, using a sharp tool at a certain angle, the bone is carefully scratched to the desired depth, and the bone fragment released by the scraping process can be removed. This definition does not provide a clear distinction between scraping (where the extracted bone is most likely to be removed in small particles or dust) and grooving (where the extracted bone is removed in larger chunks). Another well-known method is the so-called push-plough technique, which has occurred in prehistoric European cases (Parry 1940). In this case, mostly circular grooves are created on the skull surface with a stone point until the vault can be cut through, and the central bone roundel is removed. In Hungary, earlier works have already described a method that contains elements of Ortner's (2003) scraping method, and also very similar to Parry's (1940) push-plough technique. During this intervention, the cranial vault has been cut through clockwise with careful, circular grooving motions using a fine sharp instrument. The procedure has been carried out usually by a right-handed surgeon, who was probably holding the trepan at an angle, towards the center of the lesion to avoid hurting the meninges or the brain tissue, creating a funnel-shaped, externally beveling hole on the skull. These kinds of trepanations were possibly made on intact skulls or as a treatment of traumatic cranial lesions (Nemeskéri et al. 1965).

Many studies include categorization based on the reasons behind these interventions. Classical trepanations can be divided into three main groups (Lisowski 1967; Aufderheide and Rodriguez-Martin 1998): real therapeutic interventions (e.g., treatment of cranial trauma, diseases affecting the intracranial soft tissue, and/or increased intracranial pressure) (Stewart 1958; Zimmerman et al. 1981; Jørgensen 1988; Józsa 1996; Józsa and Farkas 2006; Józsa and Fóthi 2011; Verano 2016), magico-therapeutic interventions (headaches, vertigo, neuralgia, convulsion, etc. believed to be caused by evil spirits, etc.) (Stewart 1958; Nemeskéri et al. 1965; Bartucz 1966; Zias and Pomeranz 1992; Aufderheide and Rodriguez-Martin 1998, and magico-ritual interventions (e.g., making an amulet from the cut piece, etc.) (Nemeskéri et al. 1965; Aufderheide and Rodriguez-Martin 1998; Gresky et al. 2016). Regarding the real therapeutic interventions, it must be noted that the surgical procedure itself and the subsequent healing process may mask the traces of the preceding pathology, especially in the case of long-term survival of the procedure (Ortner 2003; Verano 2016; González-Darder 2019). During the healing process, the original wound rims are changing, and a secondary cortical layer is produced on the exposed diploe. However, healing and the observable macroscopic morphology largely depends on the time of survival. Right after injury or operation (0–7 days), the edges of the wound are sharp, both tables and diploe are visible at the edges, and there is no osteoclastic reabsorption or bone formation. 2.5 months

after the intervention, signs of bone resorption and thinning of edges can be observed (short-term survival). After 6 months, the closing of the diploe and smoothing of the surface begin (long-term survival) (Nerlich et al. 2003; González-Darder 2019; Partiot et al. 2020). In the Hungarian and Eastern European osteological practice, another type of traditional categorization is used in trepanation research. Cranial interventions are divided into three large groups: surgical, symbolic/incomplete, and cultic interventions (Nemeskéri et al. 1965). Surgical and symbolic trepanations were made on living subjects; however, in the former case, all three layers of the cranial vault were removed (Ortner 2003), while in the latter case, only the outer cortical layer, or sometimes the diploe, was affected, as well (Nemeskéri et al. 1965). It must also be noted that the overall localization pattern on the skull surface in these two forms is markedly different (Nemeskéri et al. 1960a; 1965; Józsa and Fóthi 2007). Cultic trepanations were carried out post-mortem (Nemeskéri et al. 1960a; Bartucz 1966). In this case, all the three layers of the cranial vault were removed, typically in a circular shape, but the subjects were deceased individuals or already skeletonized skull remains. Some form of ritual purpose is hypothesized behind the creation of both cultic and symbolic interventions, and also in certain cases of surgical trepanations (Nemeskéri et al. 1965; Mednikova 2001; Gresky et al. 2016).

The first trepanation case in Hungary was found on 9 May 1853 at an archaeological site near Vereb, dated to the tenth century CE (Érdy 1858; Kovács 1985; Mesterhazy 1996) (S1). The land-owner János Végh rescued the remains which were later described by Endre Kovács physician in the same year. The findings were analyzed and published by János Érdy archaeologist (1858) (S2). The skeletal remains belonged to a young adult male. The grave contained partial horse burial, horse-riding equipment (e.g., stirrup, bit, girth buckle), silver jewelry (e.g., finger ring, bracelet), clothing ornaments (e.g., 12 pierced silver coins), a set of belt ornaments (e.g., bronze and gilded silver mounts), and archery equipment (6 iron arrowheads and traces of quiver). The right side of the skulls was covered by a piece of silver sheet, under which the trepanation was located. The silver sheet was probably worn in a head-gear to protect the trepanned area in life. As the original paper also stated, this case is the first-ever actual trepanation to have been found and analyzed in modern times (Érdy 1858), which also precedes the famous Peruvian skull found by Squier in 1865 (Broca 1867). These remains were also included among the Hungarian trepanation cases extensively described by Anda in 1951. The original description by Kovács in 1853 had started Hungarian trepanation research with such a complex scientific approach that only became widespread in Western trepanation research at the end of the nineteenth century (Bartucz 1966).

In the early days of the Hungarian trepanation research, mainly case studies and analyses of smaller groups of findings were done (Bartucz 1938; Anda 1951). Later, the investigations were aimed at the probable reasons behind the intervention (Katona 1963; Nemeskéri et al. 1965). The first attempt to collect and publish detailed descriptions of several trepanation cases together and to give a comprehensive account of the observed phenomena was a book by Lajos Bartucz (1966). Unfortunately, many cases described in this book cannot be reexamined today, since some of them are lost from the collections or not available for other reasons. Tomka in 2000 (2000), and later Józsa and Fóthi in 2007, collected and summarized the previously published and a few unpublished surgical trepanation cases, which were accessible within the historical borders of Hungary. Almost half of all trepanation cases discovered in the Carpathian Basin (73 individuals from 134 total) can be dated to the tenth century CE, but a few cases with similar lesions are known from the preceding Avar Age (568 CE–ninth century CE), as well (Józsa and Fóthi 2007). Although this custom has been repressed during the spread of Christianity in the eleventh century CE, which began with the reign of King István I (1000–1038 CE) (Anda 1951; Nemeskéri et al. 1965),

some trepanned skulls from the subsequent Árpáadian Age (1000–1301 CE) are also known.

In the international trepanation literature, the total of 134 Hungarian cases from the Neolithic to the early modern period (Józsa and Fóthi 2007) are often neglected, as most of the descriptions were published only in Hungarian.

The aim of this study is to describe four new cases from the Great Hungarian Plain, and complement two previously published cases with new results. In the light of the Hungarian trepanation research, our study provides a comparative assessment of the six cases discussed, and we also propose a modification in the nomenclature of trepanations for a better understanding of Eastern European materials.

Material and methods

The six (surgical) trepanation cases included in our study were discovered in the following six archaeological sites: Baja-Pető (Fig. 1A), Bélmegyer-Csömöki-domb (Fig. 1B), Derekegyház-Ibolyásdomb (Fig. 1C), Hódmezővásárhely-Nagysziget (Fig. 1D), Sárrétudvari-Hízóföld (Fig. 1E), and Szeged-Csongrádi út (Fig. 1F).

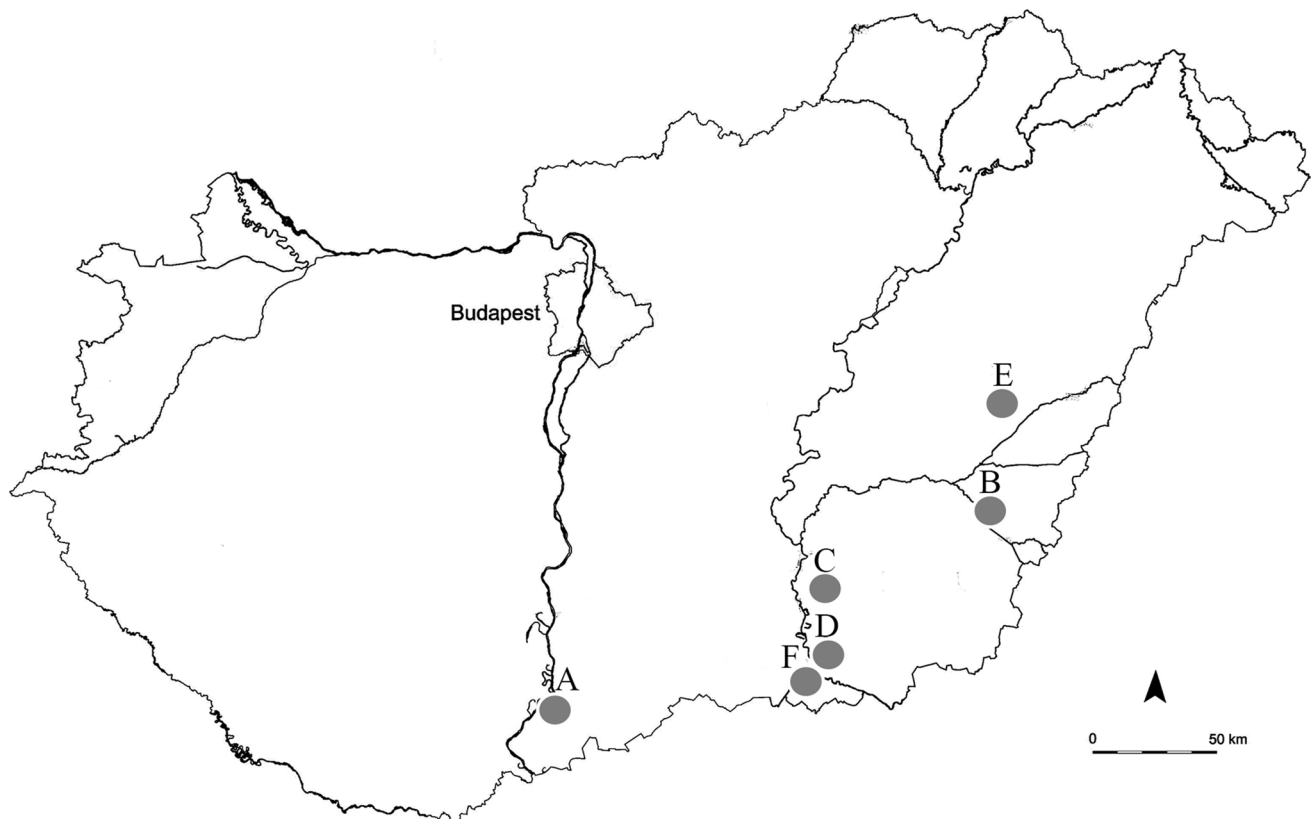


Fig. 1 Locations of the involved archaeological sites in Hungary: **A**, Baja-Pető; **B**, Bélmegyer-Csömöki-domb; **C**, Derekegyház-Ibolyásdomb; **D**, Hódmezővásárhely-Nagysziget; **E**, Sárrétudvari-Hízóföld; and **F**, Szeged-Csongrádi út

The archaeological site of Baja-Pető (eleventh to sixteenth century CE) was excavated between 1959 and 1963, under the supervision of Mihály Kőhegyi (1960; Wicker 2004). Two hundred thirty graves, located around a church, were unearthed. During the above-mentioned time period, the graveyard has been used in several phases. The anthropological investigation and evaluation of the human remains were carried out by Lotterhof (1968), but the cranial trauma case was never fully published.

The Bélmegyer-Csömöki-domb archaeological site belonging to the Late Avar Age (670/680 CE–ninth century CE) is dated to the eighth century CE (Medgyesi 1991). It was excavated between 1985 and 1989, with the supervision of Pál Medgyesi. During this period, 243 graves were unearthed. The remains of an individual with surgical trepanation have been found in a robbed grave showing different orientation from the others (Bereczki et al. 2007, 2015; Váradi et al. 2015). The radiocarbon dating and the detailed reexamination of the case yielded some new results that we present in the current study.

The excavation of the archaeological site Derekegyház-Ibolyásdomb was led by Katalin Hegedűs in 1981. In the eleventh to twelfth century CE site, 55 graves were unearthed. The surgical trepanation was mentioned by Bereczki and colleagues (Bereczki et al. 2007), but not described in detail. The reexamination of the postcranial elements yielded some new results that we present in the current study.

The Hódmezővásárhely-Nagysziget archaeological site is dated to the tenth to eleventh century CE. The first period of excavations was supervised by Gyula Gazdapusztai between 1957 and 1959 (Kovács 1979), and the second by László Révész and Katalin B. Nagy between 1982 and 1992. Altogether, the remains of 131 individuals were excavated from 135 graves. The anthropological description of the first fifteen skeletons was published by Farkas and colleagues (Farkas et al. 1969). The results of the further anthropological examinations were published by Bereczki et al. (2003, 2007) and Bereczki and Marcsik (2005). The radiological investigation and the detailed reexamination of the case yielded some new results that we present in the current study.

The rescue excavation of the archaeological site Sárrétudvari-Hízóföld was led by Ibolya M. Nepper between 1983 and 1985. The total 269 excavated graves mainly contained tenth-century-CE material, but seven of them were dated to the Bronze Age. The series were examined and described both from archaeological (Nepper 1994, 2002) and anthropological (Oláh 1990; Pálfi 1992; Pálfi et al. 1996; Berthon et al. 2015, 2019; Tihanyi et al. 2015, 2020) points of view. One surgical trepanation has already been described from the cemetery (Farkas and Marcsik 1986); however, recently a second new case was also found during the reinvestigation of the series.

The archaeological site called Szeged-Csongrádi út (tenth century CE) was excavated by Béla Kürti between 1974 and 1987 (Kürti 1996). A total of 13 graves were found. A well-healed trepanation was mentioned in an earlier study (Bereczki et al. 2007), but a new case was also found during the reexamination of the material.

For sex determination, the method developed by Éry and colleagues (Éry et al. 1963) was used. Age at death was determined by using classical macromorphological methods, observing and scoring the metamorphosis of the sternal end of the ribs (İşcan et al. 1984), the changes of the sternal articular surfaces of the clavicle (Szilvássy 1978), and the changes of the auricular surface (Lovejoy et al. 1985). In some cases, elements of a combined method established by Nemeskéri et al. (1960b) were also used.

Radiocarbon analysis was performed to confirm the archaeological dating of the Bélmegyer remains. Grave no. 27 (our trepanned individual) and grave no. 36 (a control inhumation with grave goods typically found in eighth-century-CE graves in the Carpathian Basin, e.g., a set of belt ornaments) were sampled. The bone fragments were measured by accelerator mass spectrometry (AMS) in the AMS laboratory of the Institute for Nuclear Research, Hungarian Academy of Sciences, Debrecen, Hungary (technical details concerning the sample preparation and measurement: Molnár et al. 2013). The conventional radiocarbon data was calibrated with the OxCal 4.4 software (<https://c14.arch.ox.ac.uk/oxcal/OxCal.html>, date of calibration: 7th of September 2021) with IntCal 20 settings (Reimer et al. 2020). The radiocarbon analysis was supported by the Árpád-ház Project.

In three cases (Baja-Pető 59, Bélmegyer-Csömöki-domb 27, and Derekegyház-Ibolyás-domb 27), CT scan and digital reconstruction were conducted, supported by the Árpád-ház Project. CT examinations were performed with a multi-slice CT scanner (Philips Brilliance iCT 256), with the application of the following parameters: 120 kV tube voltage, 380 mAs. Images were displayed in a 512 × 512 matrix (Department of Radiology, University of Szeged, Szeged, Hungary). In the case of Hódmezővásárhely-Nagysziget 76, CT scan and digital reconstruction were made by Péter Zádori (Kaposi Somogy County Teaching Hospital, Dr. József Baka Diagnostic, Radiation Oncology, Research and Teaching Center) with CT scanner Siemens Definition AS 128 slice, slice thickness 0.6 mm. In two cases (Sárrétudvari-Hízóföld 264 and Szeged-Csongrádi út 5), 3D scans were also made with Artec Space Spider scanner and the model was created with Artec Studio 15 (Research Centre for Archaeogenetics, Institute of Hungarian Research, Budapest, Hungary).

Results

Detailed archaeological and demographical data and description of the trepanations are summarized in Table 1. A detailed pathological description of each individual is provided in the supplementary table (S3).

Baja-Pető, grave no. 59 (BP59, female, 40–50 years) (Fig. 2)

The opening of the skull (Fig. 2a, b) created by the intervention is located in the middle of the lateral surface of the left parietal bone (Fig. 2c). The lesion has a triangular shape, and the most lateral outer edge begins from the squamous suture, 60 mm far from the sagittal suture. The outer edges of the trepanation are 65 mm, 55 mm, and 45 mm long, while the internal edges are 30 mm, 35 mm, and 25 mm in length. All trepanation margins are externally beveling. The longest edge of the lesion is created by a bony fragment, which has probably been slightly displaced from the original position and ossified to its current location. The bony piece is approximately 60 mm long and 15–20 mm wide, protruding slightly from the original surface of the skull (Fig. 2d). The edges of the entire lesion are healed; the diploe cannot be observed. The bone around the trepanation is thickened,

with considerable spongy hypertrophy and seemingly normal cortical layers.

On the orbital roofs, vascularization can be seen with an appearance resembling cribra orbitalia (Fig. 2e, f). On the endocranial surface, slight Pacchioni granulations can be found. The bones of the entire skeleton are pototic but in general, well-preserved. Arthrosis was observed on the joint surfaces of the spine and lower limbs.

Bélmegyer-Csömöki-domb grave no. 27 (BCS27, male, 40–45 years) (Figs. 3, 4, 5, and 6)

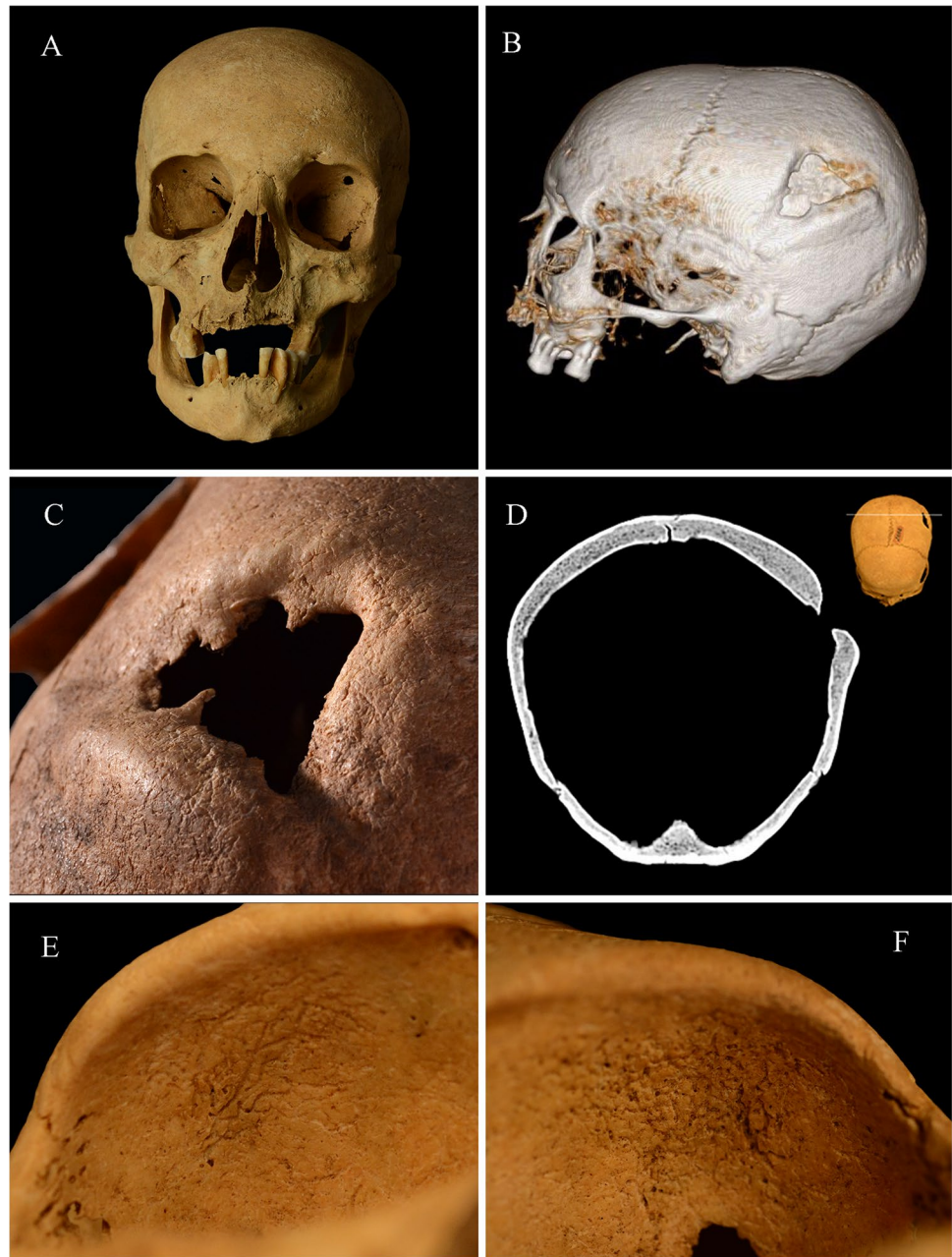
The large round trepanation can be found on the right parietal bone (Fig. 3a, b), just below the parietal tuber, 69 mm laterally from the sagittal suture, 45 mm from the coronal suture, 7 mm from the squamous suture, and 26 mm from the lambdoid suture (Fig. 3c). The rim of the lesion shows fine clockwise cut marks both along the upper (Fig. 3d) and the lower (Fig. 3e) sections. The edges slope towards the center of the opening (Fig. 3f). A small part of the dorsal margin is showing signs of some bone reaction (Fig. 3c), but in general, the diploe on the margins is clearly visible. In addition to the surgical trepanation, four symbolic trepanations were also observed (Fig. 4a) (Bereczki et al. 2015). On the right part of the frontal bone, an almond-shaped trepanation can be found (34 mm × 19 mm) (Fig. 4b). The

Table 1 Archaeological and demographical data, and description of the trepanations

Cemetery, grave no	BP59	BCS27	DI27	HN76	SH264	SZCS5
Site date	11–16 th c. CE	8 th c. CE (case date: late 9 th c. CE)	11–12 th c. CE	11–12 th c. CE	10 th c. CE	10 th c. CE
State of preservation	Good, complete	Good, incomplete	Fragmented, incomplete	Good, incomplete	Fragmented, incomplete	Fragmented, incomplete
Sex and age group	Female, 40–50 years	Male, 40–45 years	Male, 35–39 years	Male, 40–50 years	Male, 30–35 years	Female, 40–50 years
Location of trepanation	Left parietal bone	Right parietal bone	Left parietal bone	Right parietal bone	At the junction of left parietal bone, occipital bone, and left temporal bone	Around bregma and on the sagittal suture
Form and size of trepanation	Triangle shape Ext: 65 × 55 × 45 mm Int: 30 × 35 × 25 mm	Roundish shape Ext: 57 × 48 mm Int: 41 × 36 mm	Oval shape Ext: 20 × 25 mm Int: 9 × 22 mm	Roundish shape Ext: 60 × 100 mm Int: 33 × 58 mm	Rounded rectangular shape Int: 31 × 28 mm	Rounded oval shape Ext: 69 × 65 mm Int: 13 × 12 mm
Survival	L-term	S-term	L-term	S-term	L-term	L-term
Grave goods	Undisturbed, no grave goods	Disturbed, horse bones	Disturbed, no grave goods	Disturbed, no grave goods	2 penannular hair ringlets with oblique ends, bow, quiver, saber (Nepper, 2002)	Rhombus-shaped silver shift ornament, 2 silver hair ringlets, armring, string of beads (Kürti 1996)

c century, Ext ectocranial side, Int endocranial side, L-term long-term survival, S-term short-term survival

Fig. 2 Baja-Pető grave no. 59: **a** anterior view of the cranium; **b** 3D CT reconstruction of the cranium; **c** surgical trepanation on the left parietal bone; **d** frontal CT slice of the surgical trepanation; **e** slight cribra orbitalia in the right orbit; and **f** slight cribra orbitalia in the left orbit

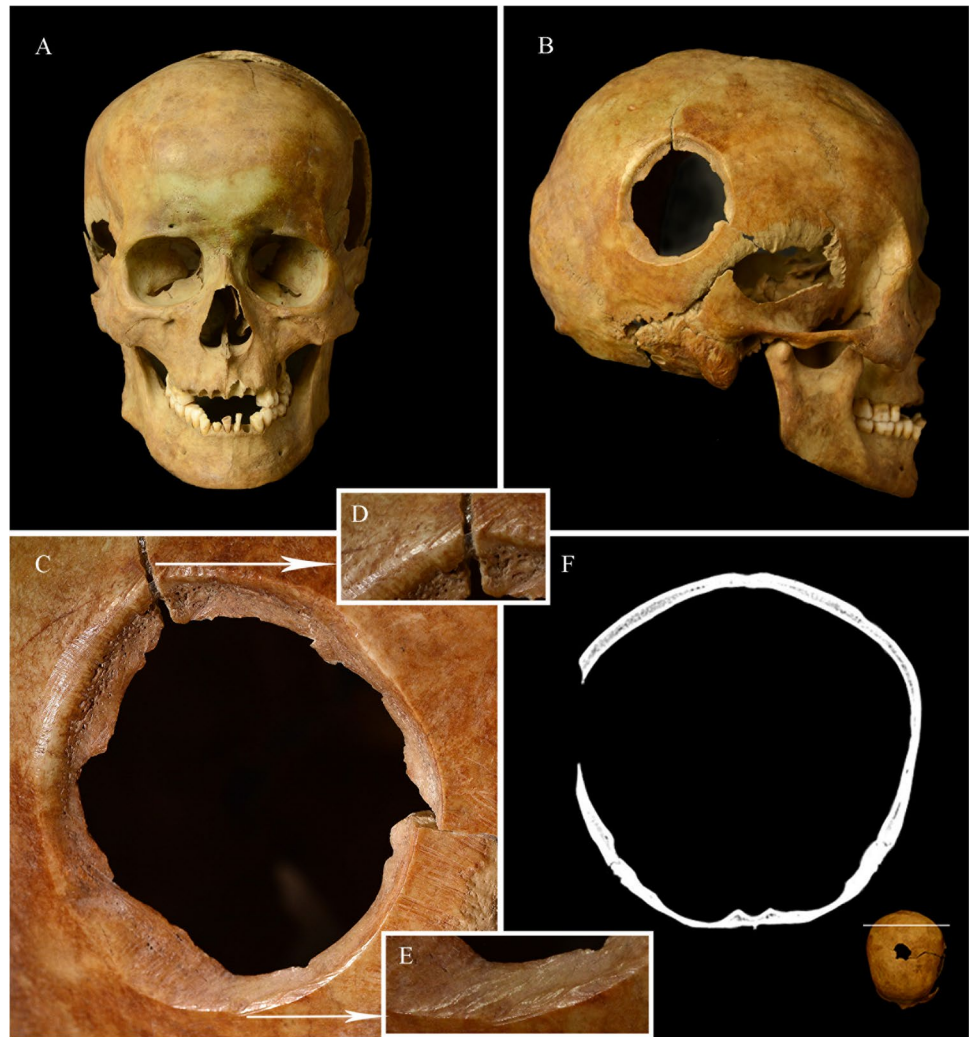

second engraving is an oval lesion (18 mm in diameter), which is located about 45 mm behind the bregma point, on the sagittal suture (Fig. 4c). The third symbolic trepanation is a 9 mm wide, funnel-shaped lesion (Fig. 4c), placed right next to the second one. The fourth symbolic trepanation is oval/almond-shaped, and it is located on the parietal tuber of the left parietal bone (50 mm × 23 mm) (Fig. 4d). On the endocranial surface of the left temporal, occipital, and frontal (posterior to the orbits) bones, granular impressions (GIs) can be observed (Fig. 5). GIs are 0.5–1 mm impressions on the endocranial surface, developing due to pressure atrophy that is caused by the tubercles formed on the dura mater in

later stages of tuberculous meningitis (Spekker et al. 2020a, 2021b).

The results of the radiocarbon analysis and the calibration are summarized in Fig. 6 and Table 2. The radiocarbon analysis of BCS27 (conventional radiocarbon age is 1123 ± 20) dated the sample between 887 and 990 CE/AD (95.4% probability) without gaps. In comparison, the radiocarbon analysis of grave no. 36 (conventional radiocarbon age is 1240 ± 26) dated the sample between 680 and 745, 759 and 779, and 784 and 880 CE/AD (95.4% probability), which might extend the archaeological dating of the cemetery to the ninth century CE. Nevertheless, the results did

Fig. 3 Bélmegyer-Csömöki-domb grave no. 27: **a** anterior view of the cranium; **b** lateral view of the cranium; **c** surgical trepanation on the right parietal bone; **d** clock-wise cutmarks along the upper rim; **e** clock-wise cutmarks along the lower rim; and **f** frontal CT slice of the surgical trepanation



not exclude the archaeological data, and the burial can be dated to the Late Avar Age.

According to these results, BCS27 is younger with decades or even with centuries than grave no. 36. Besides, the end of the ninth and tenth century CE already belong to the Hungarian Conquest period of the Carpathian Basin. Therefore, based on the radiocarbon data, the grave of BCS27 cannot be considered as an Avar Age burial anymore. The new results allow researchers to open interdisciplinary discussions concerning the further analysis and evaluation of the Bélmegyer-Csömöki-domb cemetery.

Derekegyház-Ibolyásdomb, grave no. 27 (DI27, male, 35–39 years) (Fig. 7)

On the left parietal bone, an oval hole can be seen, which is 20 mm in length and 25 mm in width (Fig. 7a). The edges of the lesion show presumably advanced-stage healing. Two bony shards ossified to the dorsal part of the hole (Fig. 7b, c). On the margin of the wound, ante-mortem fracture lines can

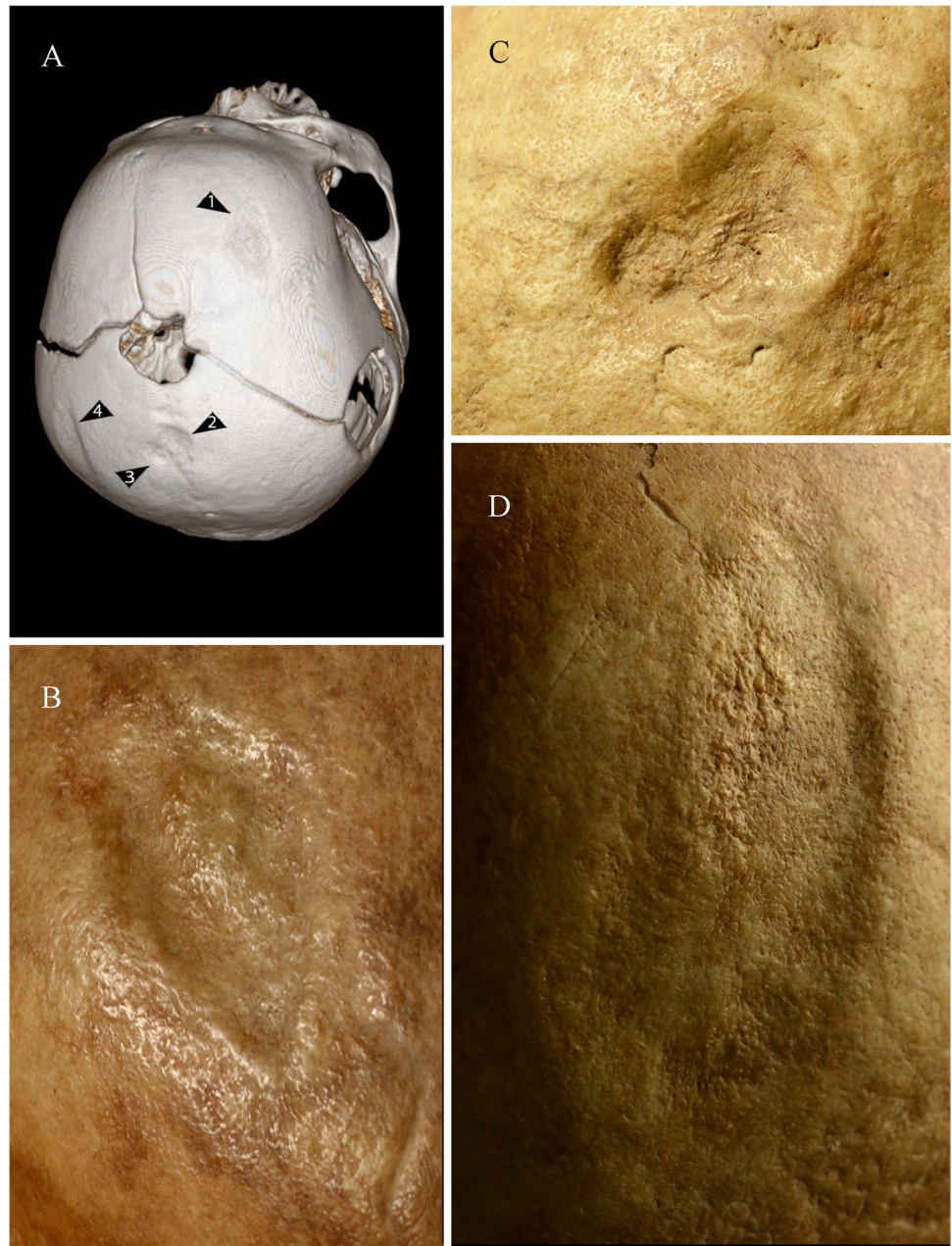be seen, which are running to the radial direction (Fig. 7c). The skull was post-mortem deformed. Several post-mortem cuts can be observed on the diaphysis of the examined long bones. These cuts are assumed to be made long before the excavation of the archaeological site. The lower part of the right humerus is missing. The distal quarter of the left radius and ulna is post-mortem cut. The distal third of both femurs and the left fibula is missing.

Hódmezővásárhely-Nagysziget, grave no. 76 (HN76, male, 40–50 years) (Fig. 8)

The skull is post-mortem deformed and presents a trepanation on the right parietal bone, which is 60 mm in length and 100 mm in width. The basically round-shaped hole continues in an amorphous hiatus towards the temporal region, with the rims appearing irregular and cracked (Fig. 8a, b).

The rims of the rounded region show possible signs of early bone healing, indicating a short survival; furthermore, the external surface adjacent to the irregular

Fig. 4 CT reconstruction and symbolic trepanations of Bélmegyer-Csömöki-domb grave no. 27: **a** 3D CT reconstruction of the cranium; **b** 1st symbolic trepanation on the frontal bone; **c** 2nd and 3rd symbolic trepanations on the sutura sagittalis; and **d** 4th symbolic trepanation on the left parietal bone



edges of the temporal region exhibits short scratches and cutmarks presumably made by a fine-bladed instrument (Fig. 8c). In earlier papers (Bereczki et al. 2003, 2007; Bereczki and Marcsik 2005), the lesion has been considered as the outcome of a glancing sword-cut with subsequent distal fractures, which were treated with trepanation to clear the wound.

Sárrétudvari-Hízófold grave no. 264 (SH264, male, 30–35 years) (Fig. 9)

At the junction of the left parietal, occipital, and temporal bones, a long-healed trepanation can be observed, which is

31 mm in length and 28 mm in width (Fig. 9a). The lesion is rounded or slightly rectangular (Fig. 9b), and externally beveling. The deformation of the circle might be caused by post-mortem distortion and inappropriate gluing of the cranial fragments. The inner margin of the lesion is post-mortem damaged. Besides GIs (Fig. 9c) seen posterior to the orbits, and on the occipital bone, abnormally pronounced digital impressions (APDIs) (Fig. 9d) can be observed on the frontal and parietal bones, suggesting increased intracranial pressure for a relatively long period of time (Spekker et al. 2021a, b). Abnormal blood vessel impressions (ABVIs) (Fig. 9c, d) were detected on the frontal bone, parietal bone,

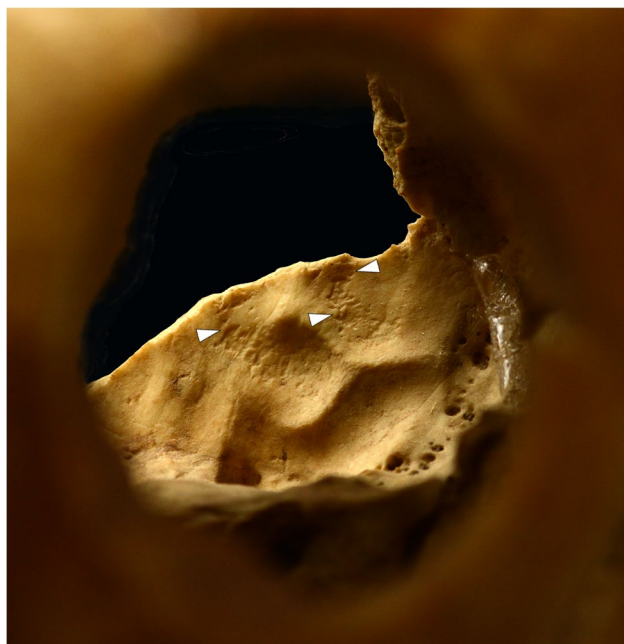

Fig. 5 Bélmegyer-Csömöki-domb grave no. 27: GIs on the endocranial surface of the left temporal bone (white arrows)

and occipital bone that could have developed during the healing of the formed hematomas (Spekker et al. 2020b, 2021b).

Szeged-Csongrádi út, grave no. 5 (SZCS5, female, 40–50 years) (Fig. 10)

On the skull, a large, shallow trepanation can be seen, which is 69 mm in length and 65 mm in width. In the middle part of the lesion, a little hole with natural margins (13 mm×12 mm) (Fig. 10) was observed. Its most anterior part involves the bregma. The surface of the lesion is fragmented and incomplete; therefore, it is not possible to decide with absolute certainty whether it is a symbolic or a surgical trepanation. However, the surface of the lesion shows definite signs of remodeling; therefore, survival.

Discussion

Differentiation of trepanations from other types of lesions that manifest as holes in the skull wall is essential during the investigation of cranial surgery cases. Among these, enlarged parietal foramina (Steinbock 1976; Aufderheide and Rodríguez-Martin 1998; Verano 2016), epidermal cysts (Verano 2016), metastatic carcinoma and multiple myeloma (Aufderheide and Rodríguez-Martin 1998; Verano 2016), infections, like syphilis (Aufderheide and

Rodríguez-Martin 1998), blunt force (BFT) and sharp force trauma (SFT), and fractures (Steinbock 1976; Aufderheide and Rodríguez-Martin 1998; Verano 2016) can all cause destructive changes or hiatuses in the skull vault. However, the size, shape, localization, and surface morphology of our cases facilitate relatively easy differentiation from most of these alterations, except for certain types of trauma.

BFTs have a wide variety of fracture patterns; and therefore, in most cases, do not reflect the size, shape, or impact velocity of the weapon (Byers 2005; Dirkmaat et al. 2008; Cohen et al. 2012). BFTs can be confused with healed symbolic trepanations but sometimes even surgical trepanations. SFTs, including all blade-induced lesions, can also mimic trepanations (Steinbock 1976; Byers 2005; Rodríguez-Martin 2006; Cohen et al. 2012). In the case of sword-cuts, if the blow is not perpendicular to the skull wall, one edge of the resulting hole will be sharp and flat, while the other edge will be irregular. On the flat cut rims, the fine grooves of the cutmarks will run parallel to each other (Cohen et al. 2012; Verano 2016). These features must be considered in all those cases, where trepanations and traumas may be confused. However, healing and remodeling can mask these signs (Ortner 2003; Verano 2016; González-Darder 2019), and on the other hand, primary traumas and trepanations may often have a causative relationship with each other (Stewart 1958; Zimmerman et al. 1981; Jørgensen 1988; Józsa 1996; Józsa and Farkas 2006; Józsa and Fóthi 2011; Verano 2016).

In the case of BP59, a healed fracture line and a dislocated bony shard can be observed next to the hole, which is suggesting that the triangular trepanation was made as a correction of fracture or, most likely, a cut. We suppose that all rims of the currently observable lesion are secondary margins, created during the trepanation process, which is corroborated by the fact that these rims are also externally beveling.

External beveling of the lesion on the skull of BCS27 is also apparent, and even more suggestive of trepanation. Based on the fine grooves of the clockwise cutmarks, the hole was probably created with a small, sharp blade, used by a right-handed individual with clockwise motions. Lesions created with this technique are very common in the Carpathian Basin (Nemeskéri et al. 1965). Short-term survival of intervention is implied by the dorsal rim morphology; however, other parts of the rim are very sharp, and the spongy cellae do not seem to be filled in the surface. Therefore, the time of survival may not be longer than a couple of weeks (González-Darder 2019). The four symbolic/incomplete trepanations may have been created for magico-therapeutic purposes in connection with tuberculosis that caused the GIs on the endocranial surface. The cause of the main surgery is not apparent based on the currently available symptoms.

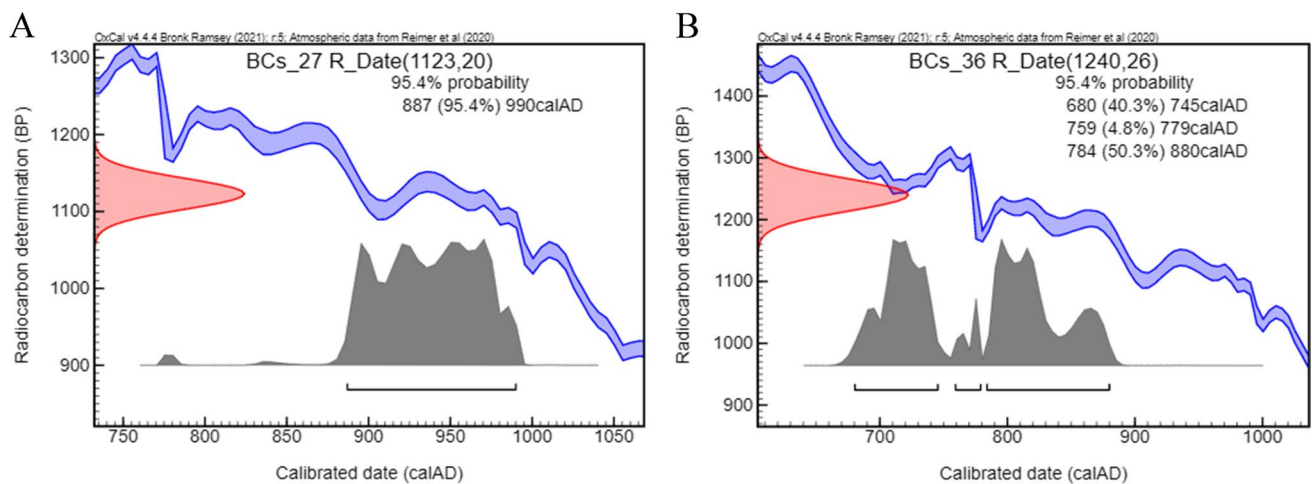


Fig. 6 Radiocarbon dating of the BÉlmegyer samples: **a** calibration graph of the radiocarbon data derived from BÉlmegyer-Csömöki-domb grave no. 27 (Oxcal 4.4 software with IntCal20 settings) and

b calibration graph of the radiocarbon data derived from BÉlmegyer-Csömöki-domb grave no. 36 (Oxcal 4.4 software with IntCal20 settings)

DI27 has a small, round-shaped lesion, with an attached bone splinter. Presumably, the trepanation was carried out as a treatment of a small-diameter blunt force trauma, probably that of a mace or hammer-axe. The remains of the DI27 individual were probably relocated twice in the cemetery. This is assumed based on the systematic, clean, oblique, single, and multiple cuts on the long bones that aged together with the natural bone surfaces. The surrounding surface of the cuts suggests that they occurred on the dry bones not immediately after the death of the individual. The church and the graveyard were built on an earlier cemetery, which is evidenced by the graves cut by the church wall. The trephined individual may have belonged to this earlier population. Some time after the burial, the bones must have been collected and placed in a bundle, probably in order to free up space in the cemetery. During a second instance of disturbance, probably during the building of the church wall, the DI27 long bones were cut through giving way to a building trench, resulting in the oblique cutmarks of the mid-shafts.

In the case of HN76, the virtual 3D reconstruction, made on the basis of the CT scans, clarified that although earlier reports attributed the rounded shape to a sword-cut, the overall geometry of the lesion does not necessarily fit that. The remaining surfaces

of the exposed trabecular bone and internal cortical sheet do not form a single plain that would be expected in a solitary sword-cut, but they appear more funnel-like. This geometry rather implies a surgical intervention as the reason for the rounded shape instead of an initial sword-cut (which might have still been present preceding the intervention). This also means that the traces of the original trauma had been mostly cleared by the surgical intervention, and both the circular top and the irregular bottom part of the currently observable lesion are affected by the trepanation.

On the endocranial surfaces of SH264, the co-occurrence of GIs, APDIs, and ABVIs strongly suggests a tuberculous pathological process in the body (Spekker et al. 2020a, b, 2021a, b). Since APDIs form as a result of increased intracranial pressure, presumably, the trepanation could have been used to reduce intracranial pressure, which may explain the unusual localization. The hole is a rounded, funnel-shaped lesion with external beveling, and well-healed wedge-shaped rims. This method of preparation is very common in the Carpathian Basin (Nemeskéri et al. 1965).

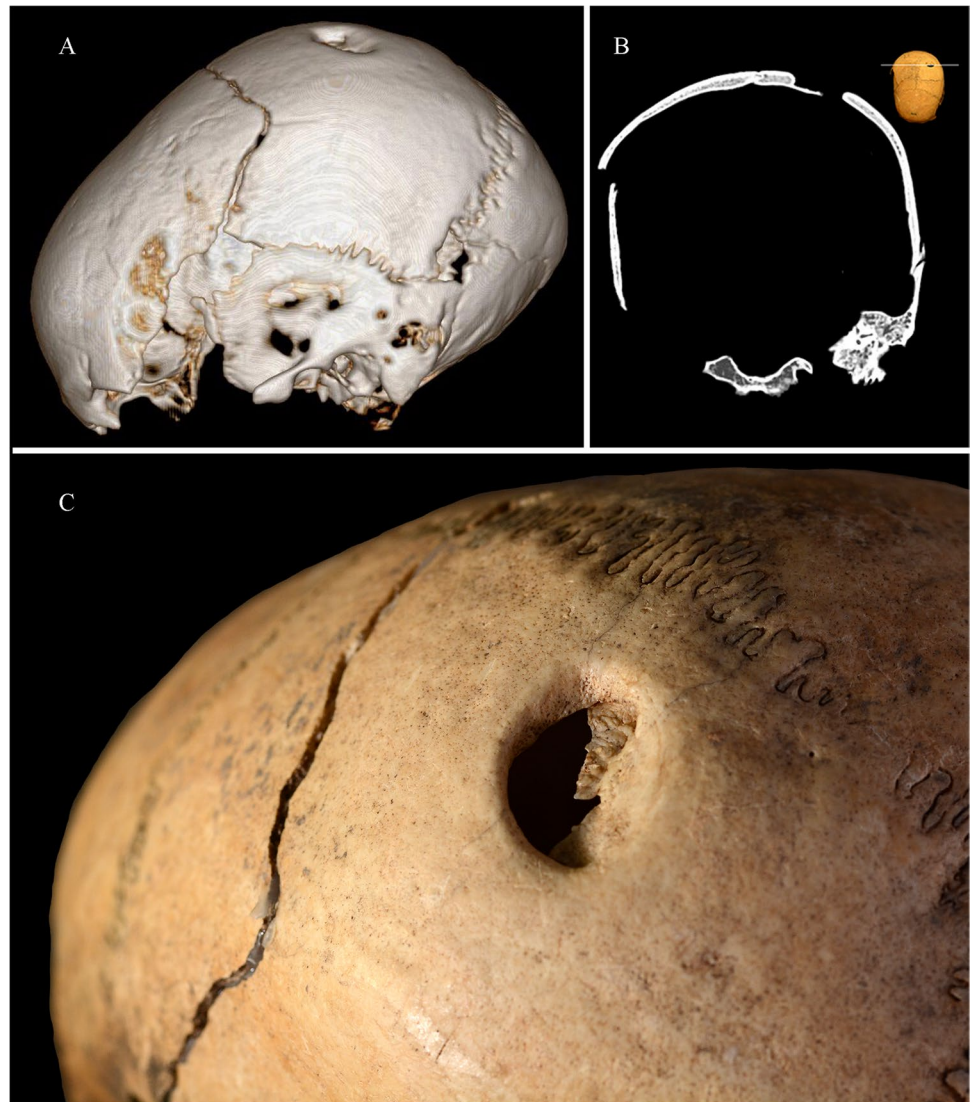
The middle part of the large trepanation of SZCS5 is post-mortem damaged and incomplete; hence, it is difficult to determine whether it is a symbolic or a surgical trepanation. However, comparing other large, flat-edged surgical trepanations,

Table 2 Results and calibration of the radiocarbon dating

Code	Site	Grave number	Type of sample	Uncalibrated BP	±	OxCal ¹ 95% cal	AMS Lab ID
BCs_27	BÉlmegyer-Csömöki-domb	27	Rib fragment	1123	20	887–990	DeA-20720
BCs_36	BÉlmegyer-Csömöki-domb	36	Rib fragment	1240	26	680–745; 759–779; 784–880	DeA-20685

Notes: ¹Software and settings: OxCal 4.4, IntCal20

Fig. 7 Derekegyház-Ibolyásdomb grave no. 27: **a** 3D CT reconstruction of the cranium; **b** frontal CT slice of the surgical trepanation with two ossified bony shards on the dorsal part of the hole; and **c** surgical trepanation on the left parietal bone surrounded by fracture lines



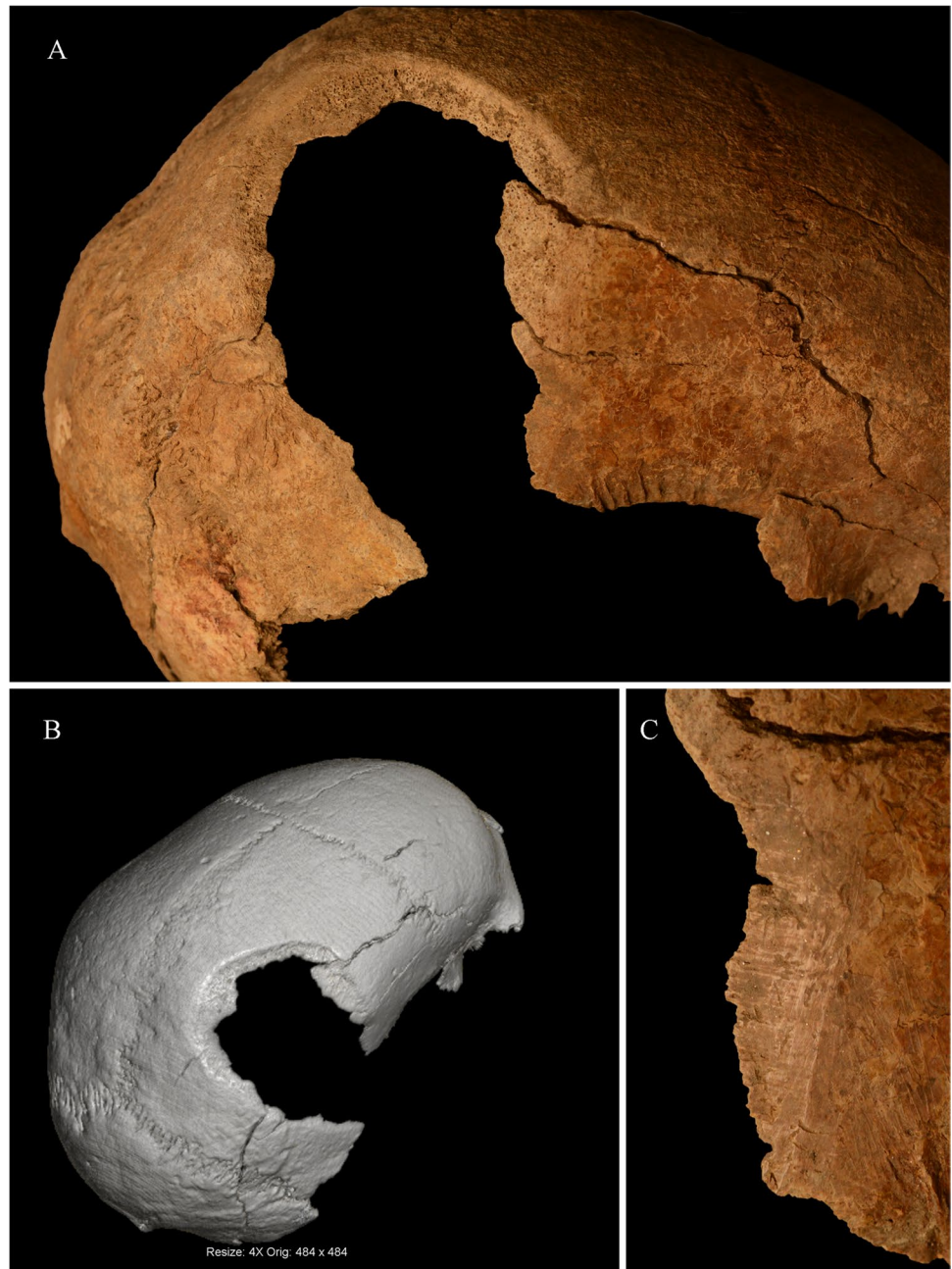
such as Karos 3294 (Anda 1951) (Fig. 11a) and Rétközberencs-Paromdomb 2 (Bartucz 1966; Éry 1977) (Fig. 11b), and the large symbolic trepanations of Karos-Eperjesszög II 11 (Kustár and Szikossy 1995) (Fig. 11c) and Tuzsér-Boszorkányhegy 5/6 (Éry 1977), we can draw the following conclusion. In the case of surgical trepanations, the surface of the lesion slopes towards the middle of the lesion, creating a hole in the deepest part, while in the case of symbolic ones, it follows the curvature of the skull wall without penetrating it (Fig. 11d). Based on the slope of the surface and the natural edge observed in the middle of the lesion, we presume that SZCS5 is a surgical trepanation case (Fig. 11e, f) that may have been created by scraping the surface to the point when the middle of the affected area was penetrated. However, signs of a primary cranial trauma or other pathology that could have induced trepanation have not been detected.

Summarizing the differential diagnoses and the indication of the interventions, trauma correction can be assumed in three

cases (BP59, DI27, and HN76), and in one further case, the trepanation might have been carried out to decrease high intracranial pressure (SH264). In other words, most of our cases show signs that refer to the cause of intervention being therapeutic, and not necessarily ritual. Of course, some mixed (magico-therapeutic) intentions may still lie in the background. Our team is already examining the validity of this assumption on the total sample of currently available early Hungarian trepanations.

Among the six introduced cases, four men and two women were found. This ratio follows the distribution described in the most recent literature that contains data collected from larger samples. In a study, focusing on prehistoric South American cases (with probably the biggest collection of trepanations published so far), the observed gender distribution of 621 trepanned individuals was as follows: 58.1% were males, 31.7% were females, and 7.6% were indifferent/subadults (Verano 2003). In an Italian study with the trepanation sample coming from the prehistory to modern times, males made up 74% of

Fig. 8 Hódmezővásárhely-Nagysziget grave no. 76: **a** surgical trepanation on the right parietal bone; **b** CT reconstruction of the skull with the surgical trepanation; and **c** signs of scratching and short cutmarks on the lower anterio-lateral margin of the trepanation

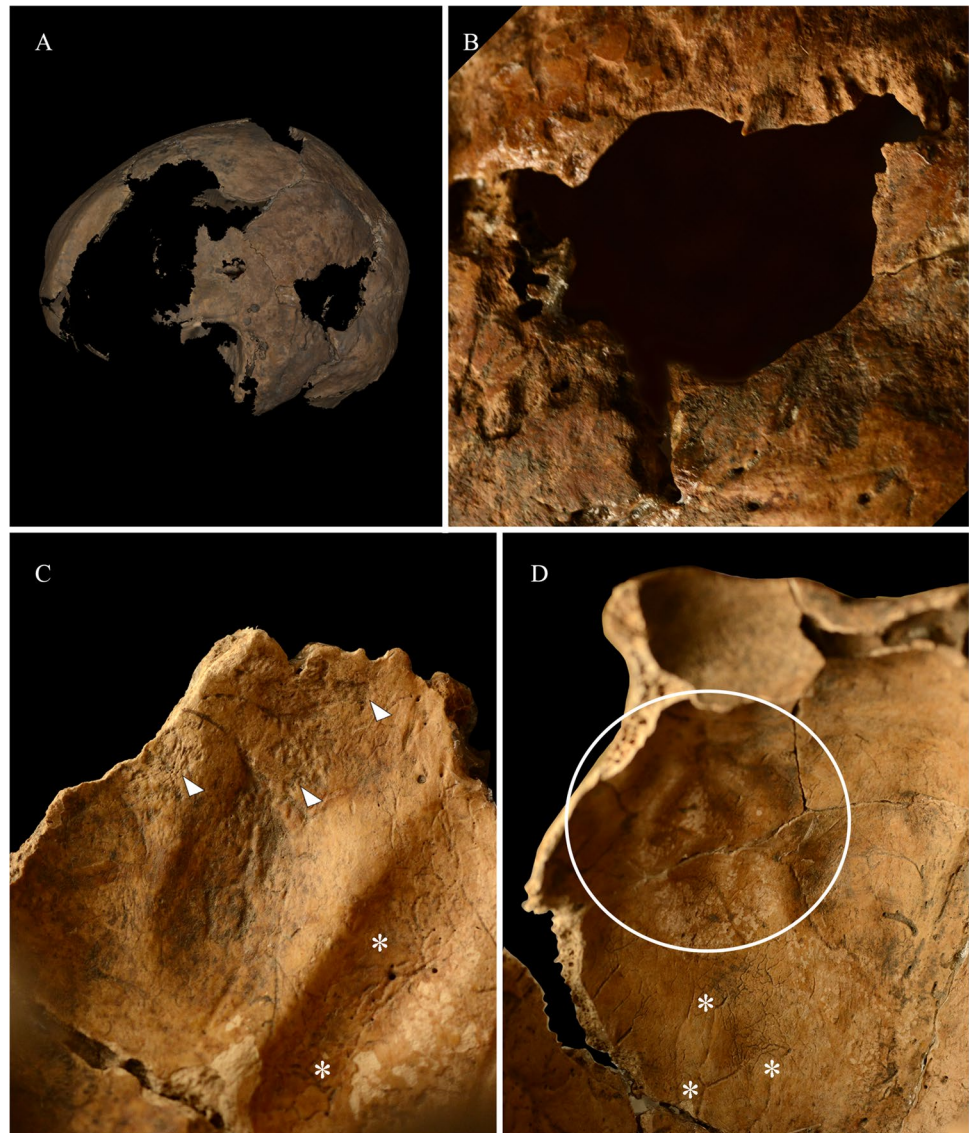


the total sample (Giuffra and Fornaciari 2017). An Anatolian study with a similar chronological span found that males make up 65% of the sample (Erdal and Erdal 2011). A British paper found almost the same ratio (64.5%) for males (Roberts and McKinley 2003). In a comprehensive Hungarian study, among 73 cases dated to the tenth to eleventh century CE, 76.9% of the individuals were males, 14.6% were females, and 8.5% were indifferent/subadults (Józsa and Fóthi 2007). It is important to note that our paper deals with only a handful of cases not sufficient for statistical analysis.

As for the localization of trepanations on the skull vault, 49.9% of the South American cases were oriented to the

left side, 33.6% to the right side, and 16.5% to the center of the skull (Verano 2003). In the Italian sample, 46.6% was located on the left side, 38.6% on the right side, and 14.8% in the midline (Giuffra and Fornaciari 2017). In the Anatolian collection, 41.5% was observed on the left side, 46.3% on the right side, and 12.2% in the midline (Erdal and Erdal 2011). In about the three-quarters of the Hungarian trephined cases, dated to the tenth to eleventh century CE, the lesions were found typically on the anterior left part of the skull (Józsa and Fóthi 2007). Among our six described cases, in two instances, the middle-posterior region of the left parietal bone, and in two further cases, the middle of the

Fig. 9 Sárrétudvari-Hízóföld grave no. 264: **a** 3D scan of the skull with surgical trepanation; **b** surgical trepanation on the left side of the skull; **c** GIs (white arrows) and ABVIs (white asterisk) on the endocranial surface of the occipital bone; and **d** APDIs (white ellipsis) and ABVIs (white asterisk) on the endocranial surface of the frontal bone



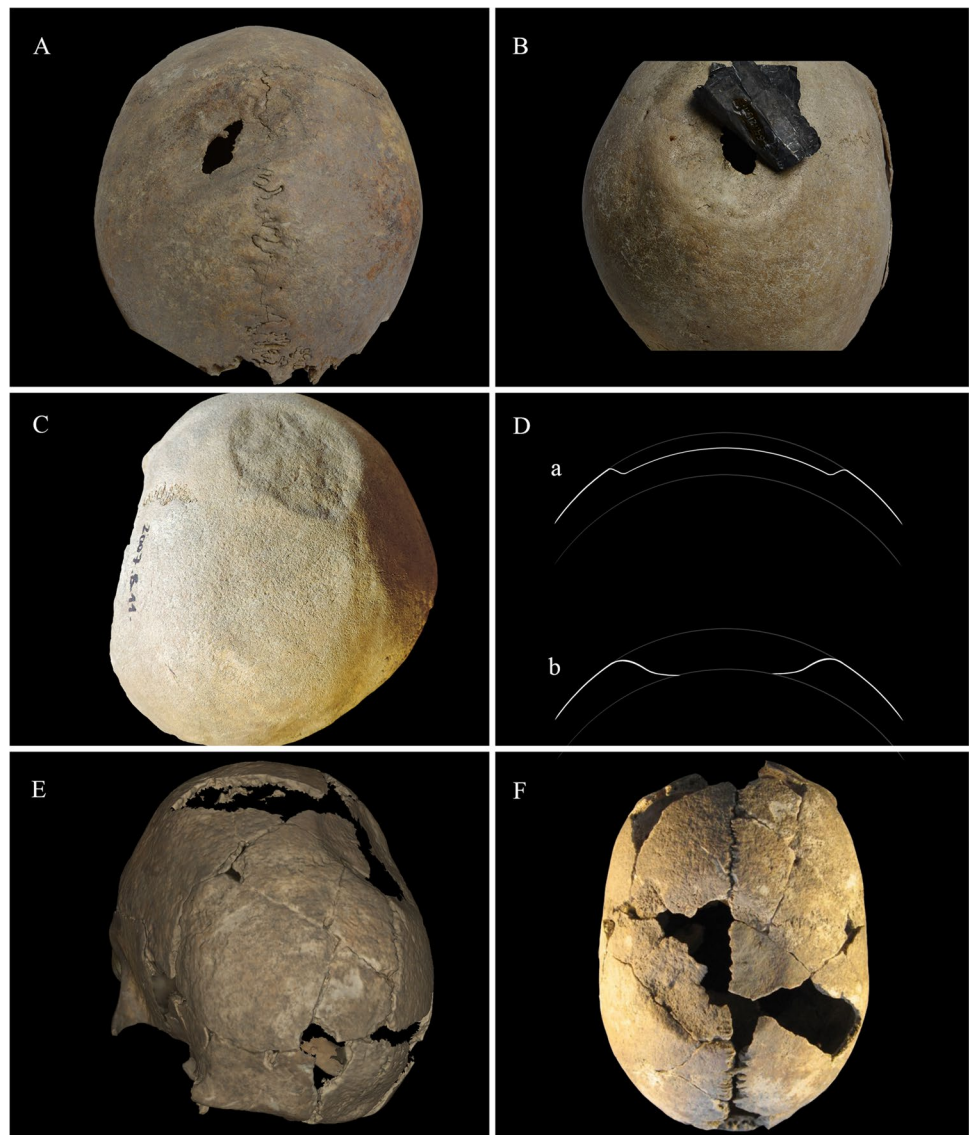
right parietal bone was affected. In one case, the lesion was located at the junction of the left parietal-temporal-occipital bones, and in another case, the intervention was carried out at the middle of the skull, around the bregma. The fact that the majority of trepanations can be found on the left side (though not on the anterior left region), and the apparent trauma-related signs in some cases (BP59, DI27, and HN76) may indicate that the procedure was used for surgical treatment of a primary trauma inflicted by interpersonal violence among right-handed individuals. However, skull traumas are most frequent on the frontal and parietal bones (Cohen et al. 2012), and even though the distribution of location presents a slightly higher prevalence on the left side, it is not statistically significant because of the small sample size, and our conclusion must also be corroborated by future research.

Among the described cases, we observed long survival after the intervention in four out of the six cases. This ratio is



Fig. 10 Surgical trepanation of the individual from the Szeged-Csongrádi út grave no. 5

Fig. 11 **a** surgical trepanation of Karos 3294 (Photo by Kitty Király with permission from the Hungarian Natural History Museum, Department of Anthropology); **b** surgical trepanation of Rétközberencs-Paromdomb grave no. 2 (with a corroded protective silver sheet glued to the surface of the skull) (photo by Kitty Király with permission from the Hungarian Natural History Museum, Department of Anthropology); **c** symbolic trepanation of Karos-Eperjesszög II grave no. 11 (Photo by Orsolya Váradi with permission from the Hungarian Natural History Museum, Department of Anthropology); **d/a** in case of symbolic trepanations, the central surface of the trepanned lesion follows the natural curve of the cranium (Artwork by Luca Kis); **d/b** in the case of surgical trepanations, the central surface of the trepanned lesion slopes towards the center penetrating the natural curve of the cranium (artwork by Luca Kis); **e** 3D scan of the skull from the Szeged-Csongrádi út grave no. 5; and **f** surgical trepanation of the individual from Szeged-Csongrádi út grave no. 5



consistent with the literature data (81%) regarding cases from the tenth to eleventh century CE in Hungary (Józsa and Fóthi 2007). Unfortunately, in many cases, the trepanation itself and the healing process obscure the traces of the original trauma.

The BCS27 case draws attention to another important point. The surgical lesion strengthens the earlier hypothesis concerning the ritual therapeutic purpose of the four symbolic trepanations (Nemeskéri et al. 1960a, 1965; Bartucz 1966; Zias and Pomeranz 1992; Aufderheide and Rodriguez-Martin 1998). Taking the pathological features and the possible timeline of the cranial interventions into consideration, we can formulate the following speculative scenario. There may have been an initial pathology that necessitated intervention. At first, the community may have tried ritual healing in the form of symbolic trepanations, and resorted to surgical trepanation after the symbolic ones “did not work.” As for the initial pathology, the surgical trepanation may have masked

a primary trauma as a preceding pathology, but endocranial lesions, possibly in connection with an infectious disease that increased the intracranial pressure and caused pain, are also a possible cause of intervention. However, we have to emphasize again that this explanation is highly speculative, since the indication of symbolic trepanations is up to now without any written or empirical evidence.

Here, we have to address the confusing nature of the current nomenclature concerning trepanation categories. Both surgical and symbolic cases involve the removal of bone material. Surgical trepanations are sometimes called complete, while symbolic ones are regarded as incomplete. However, any surgical intervention can obviously be incomplete, as in, interrupted and unfinished, regardless of the original intention of creating a hole in the skull or creating a hollowed depression on the surface.

On the other hand, the use of the expressions “surgical” and “symbolic” is also misleading. Surgical trepanations may

mostly be therapeutic in purpose, but might also be magico-therapeutic and magico-ritual in nature (e.g., Campillo 1984; Jørgensen 1988; Gresky et al. 2016). Symbolic trepanations obviously have some symbolic aspects, but a direct adaptation of these expressions from Eastern European osteoarchaeological practice to the international technical language remains problematic.

To overcome this issue, we propose the following nomenclature. The expression “trepanation” should remain in use for all forms of intentional, non-violent removals of all three layers of the cranial vault (cf. “surgical trepanations”), where the reason for intervention can be both therapeutic and/or ritual, and the subject may be alive or deceased at the time of the intervention.

To avoid confusion, the phenomena widely known in Eastern Europe as symbolic trepanations should be designated as “cranioglyphs,” referring to all forms of superficial interventions administered to the cranial vault that do not penetrate all three layers of the bone.

According to the Merriam-Webster dictionary, the word cranium comes from the Greek *kranion* meaning skull or braincase (Merriam-Webster 2022a) which conveniently refers to the usual location of these lesions being the calvarium. The word glyph is also of Greek origin (glyphē—carved work) with several meanings all related to carved signs or symbols (Merriam-Webster 2022b) that also matches up with the usual nature of these lesions altering the geometry of the skull surface. With the use of the term cranioglyph, we can avoid misinterpretations of these unique phenomena in Western osteological practice. However, the use of “symbolic trepanation” is so deeply rooted in the Eastern European osteological practice (where the majority of the cases occur) that the two denominations will most likely coexist for several decades to come.

During the identification of these surgical traditions, the possible intention of the operator must be kept in mind during the diagnosis. In case the available macromorphological and other types of data are insufficient to properly categorize the phenomenon, one should refrain from it, and simply describe the lesion as intentional cranial intervention.

This paper also pinpoints the importance of inductive thinking in trepanation-related studies, and the relevance of the examination of individual cases. Each new case can yield new information concerning these well-studied yet still poorly understood phenomena. And on the other hand, each case has its own unique features rooted in preceding pathologies, and the individuals’ culture and life history; therefore, overall observations and theories of earlier studies are not necessarily reflected in each new case.

In order to bring spotlight to the wide range of cranial interventions in the early medieval Carpathian Basin, our team is conducting several research projects, in order to contribute to a better understanding of trepanations and cranioglyphs in the future.

Supplementary Information The online version contains supplementary material available at <https://doi.org/10.1007/s12520-022-01548-9>.

Acknowledgements The authors wish to express their gratitude to Dr. Péter Zádori and the Kaposi Somogy County Teaching Hospital—Dr. Baka József Diagnostic, Radiation Oncology, Research and Teaching Center, Kaposvár, Hungary, for the radiological images, and Dr. Endre Neparáczki and the Research Centre for Archaeogenetics, Institute of Hungarian Research, Budapest, Hungary, for providing access to the 3D scanning equipment. The assistance of the staff of the Department of Biological Anthropology, University of Szeged, Szeged, Hungary, is also greatly appreciated.

Author contribution Not applicable.

Funding Open access funding provided by University of Szeged. The project was supported by the “Árpád-ház Program” of the Ministry of Human Capacities prepared with the professional support of the Doctoral Student Scholarship Program of the Co-operative Doctoral Program of the Ministry of Innovation and Technology financed from the National Research, Development and Innovation Fund, 1020404, and supported by the University of Szeged Open Access Fund, 5639.

Data availability All data are available in the manuscript and its supplementary files.

Code availability Not applicable.

Declarations

Ethics approval Not applicable.

Consent to participate All authors have approved the manuscript.

Consent for publication All authors agree with the submission to the Archaeological and Anthropological Sciences.

Conflict of interest The authors declare no competing interests.

Open Access This article is licensed under a Creative Commons Attribution 4.0 International License, which permits use, sharing, adaptation, distribution and reproduction in any medium or format, as long as you give appropriate credit to the original author(s) and the source, provide a link to the Creative Commons licence, and indicate if changes were made. The images or other third party material in this article are included in the article's Creative Commons licence, unless indicated otherwise in a credit line to the material. If material is not included in the article's Creative Commons licence and your intended use is not permitted by statutory regulation or exceeds the permitted use, you will need to obtain permission directly from the copyright holder. To view a copy of this licence, visit <http://creativecommons.org/licenses/by/4.0/>.

References

- Anda T (1951) Recherches archéologiques sur la pratique médicale des hongrois à l'époque de la Conquête de pays. *Acta Archaeol Acad Sci Hungaricae* 1:251–316
- Arnott R, Finger S, Smith CUM (eds) (2003) Trepanation: history, discovery, theory. Swets & Zeitlinger, Lisse

- Aufderheide AC, Rodriguez-Martin C (1998) The Cambridge Encyclopedia of Human Paleopathology. Cambridge University Press, Cambridge
- Bartucz L (1938) A magyar ember. Magyar föld – Magyar faj IV., Királyi Magyar Egyetemi Nyomda, Budapest.
- Bartucz L (1966) A praehistorikus trepanáció és orvostörténeti vonatkozású sírleletek. *Palaeopathologia III, Országos Orvostörténeti Könyvtár*, Budapest.
- Berezki ZS, Marcsik A, Paja L (2003) New cases of trephination from a 10–11th century Hungarian site. *Papers on Anthropol* 12:21–31
- Berezki ZS, Marcsik A (2005) Trephined skulls in ancient populations in Hungary. *Acta Med Litu* 12:65–69
- Berezki Zs, Tóth Z, Marcsik A (2007) Sebészi trepanációk Magyarországon – újabb esetek a szarmata és avar korból. *A Magyar Biológiai Társaság 5. Kárpát-medencei Szimpozitóriuma*, Budapest, Előadástétel, 21–31.
- Berezki ZS, Molnár E, Marcsik A, Pálfi GY (2015) Rare types of trephination from Hungary shed new light on possible cross-cultural connections in the Carpathian Basin. *Int J Osteoarchaeol* 25(3):322–333. <https://doi.org/10.1002/oa.2304>
- Berthon W, Rittetard C, Tihanyi B, Pálfi GY, Coqueugniot H, Dutour O (2015) Three-dimensional microarchitecture of enthesal changes: preliminary study of human radial tuberosity. *Acta Biol Szeged* 59(1):79–90
- Berthon W, Tihanyi B, Kis L, Révész L, Coqueugniot H, Dutour O, Pálfi GY (2019) Horse riding and the shape of the acetabulum: Insights from the bioarchaeological analysis of early Hungarian mounted archers (10th century). *Int J Osteoarchaeol* 29:117–126. <https://doi.org/10.1002/oa.2723>
- Byers SN (2005) Introduction to forensic anthropology. Pearson, Boston
- Broca P (1867) Cas singulier de trépanation chez les Incas. *Bulletins De La Société D'anthropologie De Paris* 2(2):403–408
- Campillo D (1984) Neurosurgical Pathology in Prehistory *Acta Neurochir (wien)* 70:275–290. <https://doi.org/10.1007/BF01406656>
- Cohen H, Sarie I, Medlej B, Bocquentin F, Toledano T, Hershkovitz I, Slon V (2012) Trauma to the skull: a historical perspective from the southern levant (4300BCE–1917CE). *Int J Osteoarchaeol* 24(6):722–736. <https://doi.org/10.1002/oa.2258>
- Dirkmaat DC, Cabo LL, Ousley SD, Symes SA (2008) New perspectives in forensic anthropology. *Yearb Phys Anthropol* 51:33–52. <https://doi.org/10.1002/ajpa.20948>
- Erdal YS, Erdal ÖD (2011) A review of trepanations in Anatolia with new cases. *Int J Osteoarchaeol* 21:505–534. <https://doi.org/10.1002/oa.1154>
- Érdy J (1858) A verebi pogány sír. *Régiségtani Közlemények II*. Buda. 14–27.
- Éry K, Kralovánzky A, Nemeskéri J (1963) Történeti Népeiségek Rekonstrukciójának Reprézntációja *Anthropol Köz* 7:41–90
- Farkas GY, Lotterhof EB, Marcsik A (1969) A HMVH-Nagyszigeten és a Kübekháza Újtelepen feltárt sírok antropológiai leleteinek ételkelése. *MFM Évkönyve* 1:123–130
- Farkas GY, Marcsik A (1986) Further trephined skulls in Hungary. *Acta Biol Szeged* 32:199–139
- Furnas DW, Sheikh MA, van den Hombergh P, Froeling E, Nunda IM (1985) Traditional craniotomies of the Kisii tribe of Kenya. *Ann Plast Surg* 15:538–556. <https://doi.org/10.1097/00000637-198512000-00014>
- Giuffra V, Fornaciari G (2017) Trepanation in Italy: a review. *Int J Osteoarchaeol* 27(5):745–767. <https://doi.org/10.1002/oa.2591>
- González-Darder JM (2019) Trepanation, Trephining and Craniotomy. *History and Stories*. Springer, Valencia. <https://doi.org/10.1007/978-3-030-22212-3>
- Gresky J, Batieva E, Kitova A, Kalmykov A, Belinskiy A, Reinhold S, Berezina N (2016) New cases of trepanations from the 5th to 3rd Millennia BC in Southern Russia in the context of previous research: possible evidence for a ritually motivated tradition of cranial surgery? *Am J Phys Anthropol* 160(4):665–682. <https://doi.org/10.1002/ajpa.22996>
- Gross CG (2009) A hole in the head: more tales in the history of neuroscience. MIT Press, Cambridge, Massachusetts, London
- Işcan YE, Loth SR, Wright RW (1984) Metamorphosis at the sternal rib end: a new method to estimate age at death in white males. *Am J Phys Anthropol* 65:147–156. <https://doi.org/10.1002/ajpa.1330650206>
- Jørgensen JB (1988) Trepanation as a therapeutic measure in ancient (pre-Inka) Peru. *Acta Neurochir (wien)* 93:3–5. <https://doi.org/10.1007/BF01409893>
- Józsa L (1996) A honfoglaló és Árpád-kori magyarság egészsége és betegségei. Gondolat Kiadó, Budapest.
- Józsa L, Farkas GY (2006) A fej védelme és a koponyasérülések a középkorban. *Orv Hetil* 147:1519–1521
- Józsa L, Fóthi E (2007) Trepanált Koponyák a Kárpát-Medencében *Folia Anthropol* 6:5–18
- Józsa L, Fóthi E (2011) Kísérlet a középkori trepanációk műtéti technikájának rekonstruálására. *Folia Anthropol* 10:5–16
- Katona F (1963) Az agysebészet története. Medicina Kiadó, Budapest.
- Kovács I (1979) 11. századi temető Hódmezővásárhely-Nagyszigeten. *Vásárhelyi Tanulmányok* 9:17–32
- Kovács L (1985) A Kárpát-medence IX–X. századi francia pénzei és a kiskunfélegyházi sírlelet. (Pièces de monnaies françaises du IXe et du Xe siècles dans le Bassin Carpathique et le mobilier funéraire de Kiskunfélegyháza. *Archaeol Ért* 112:36–51
- Kőhegyi M (1960) Az 1960. év régészeti kutatásai. In: *Régészeti Füzetek*, Sz. Burger Alice (ed) HNM-HM, Budapest 14:80–81.
- Kustár Á, Szikossy I (1995) A Karos-Eperjesszögi II-III. honfoglaláskori temetők előzetes embertani vizsgálatának eredményei. *Somogyi Múzeumok Közleményei* 1:209–226
- Kürti B (1996) Honfoglaló magyar sírok Szeged-Csongrádi úton. In: Pálfi GY, Farkas LGY, Molnár E (eds) *Honfoglaló magyarság - Árpád-kori magyarság* Szeged, 59–65.
- Lisowski FP (1967) Prehistoric and early historic trepanation. In: Brothwell DR, Sandison AT, WR Dawson (eds) *Diseases in Antiquity: a survey of the diseases, injuries, and surgery of early populations*. Charles C. Thomas, Springfield, 651–672.
- Lotterhof E (1968) Anthropological investigations of the skeletal material of a cemetery at Baja-Pető from the XI-XVI centuries. *Acta Biol Szeged* 14:81–88
- Lovejoy OC, Meindl S, Pryzbeck TR, Mensforrh RP (1985) Chronological metamorphosis of the auricular surface of the ilium: a new method for the determination of adult skeletal age at death. *Am J Phys Anthropol* 68:15–28
- Merriam-Webster (2022a) Online Dictionary copyright © 2021 by Merriam-Webster, Incorporated; <https://www.merriam-webster.com/dictionary/cranium>; retrieved: 27 Jan 2022a
- Merriam-Webster (2022b) Online Dictionary copyright © 2021 by Merriam-Webster, Incorporated; <https://www.merriam-webster.com/dictionary/glyph>; retrieved: 27 Jan 2022b
- Medgyesi P (1991) Késő avar kori temető BÉlmegyer-Csömöki dombon. (Előzetes jelentés) *MFM Évkönyve* 1984/85–2:241–256.
- Mednikova MB (2001) Trepanatsii u drevnikh narodov Evrazii. *Nauchny mir*, Moszkva.
- Mesterhazy K (1996) Vereb. In: I Fodor I, Révész L, Wolf M, M Nesper I (Eds.), *The ancient Hungarians*. Exhibition catalogue. Hungarian National Museum 375–376.
- Molnár M, Janovics R, Major I, Orsovskzi J, Gönczi R, Veres M, Leonard AG, Castle SM, Lange TE, Wacker L, Hajdas I, Jull AJT (2013) Status report of the new AMS C-14 preparation lab of the Hertelendi Laboratory of Environmental Studies. *Debreceen, Radiocarbon* 55(2–3):665–676. <https://doi.org/10.1017/S0033822200057829>

- M Nepper I (1994) Honfoglalók a Hortobágy-Berettyó vidékén. In: Kovács L (ed): Honfoglalás és régészet. Budapest, 151–161.
- M Nepper I (2002) Hajdú-Bihar megye 10–11. századi sírleletei I–II., Magyarország Honfoglalás-kori és kora Árpád-kori sírleletei 3. Budapest- Debrecen.
- Nemeskéri J, Éry K, Kralovánszky A (1960a) A Magyarországi Jelképes Trepanáció *Anthropol Köz* 4:3–30
- Nemeskéri J, Harsányi L, Acsádi GY (1960b) Methoden zur Diagnose des Lebensalters von Skelettfunden. *Anthropol Anz* 24:70–95
- Nemeskéri J, Kralovánszky A, Harsányi L (1965) Trephined skulls from the tenth century. *Acta Archaeol Acad Sci Hungaricae* 17:343–367
- Nerlich A, Peschel O, Zink A, Rösing FW (2003) The pathology of trepanation: differential diagnosis, healing and dry bone appearance in modern cases. In: Arnott R, Finger S, Smith C (eds) *Trepanation: History, Discovery, Theory*. Swets & Zeitlinger, Lisse, 43–51.
- Oláh, S (1990): Sárretudvari-Hízóföld honfoglalás kori temetőjének történeti embertani értékelése. PhD disszertáció. JATE, Szeged
- Ortner DJ (2003) Identification of pathological conditions in human skeletal remains. Academic Press, San Diego
- Parry TW (1940) A comparison between two roundels removed by surgical holing from two prehistoric skulls, lately excavated in the county of Dorset; together with a full description of the push-plough method of operation that was probably employed. *Man* 40:33–35. <https://doi.org/10.2307/2792279>
- Partiot C, Lepetit A, Dodré E, Jenger C, Maureille B, Liguoro D, Thomas A (2020) Cranial trepanation and healing process in modern patients - bioarchaeological and anthropological implications. *J Anat* 00:1–13. <https://doi.org/10.1111/joa.13266>
- Pálfi GY (1992) Traces des activités sur les anciens Hongrois. *Bull Mem Soc Anthropol Paris* 4:209–231. <https://doi.org/10.3406/bmsap.1992.2318>
- Pálfi GY, Marcsik A, Oláh S, Farkas GYL, Dutour O (1996) Sárretudvari-Hízóföld honfoglalás kori széria paleopatológiája. In: Pálfi GY, Farkas LGY, Molnár E (eds) *Honfoglaló magyarság - Árpád-kori magyarság Szeged*, 213–235.
- Reimer P, Austin W, Bard E, Bayliss A, Blackwell P, Bronk Ramsey C, Butzin M, Cheng H, Edwards R, Friedrich M, Grootes P, Guilderson T, Hajdas I, Heaton T, Hogg A, Hughen K, Kromer B, Manning S, Muscheler R, Palmer J, Pearson C, van der Plicht J, Reimer R, Richards D, Scott E, Southon J, Turney C, Wacker L, Adolphi F, Büntgen U, Capano M, Fahrni S, Fogtmann-Schulz A, Friedrich R, Köhler P, Kudsk S, Miyake F, Olsen J, Reinig F, Sakamoto M, Sookdeo A, Talamo S (2020) The IntCal20 Northern Hemisphere radiocarbon age calibration curve (0–55 cal kBP). *Radiocarbon* 62(4):725–757
- Roberts C, McKinley J (2003) Review of trepanations in British antiquity focusing on funerary context to explain their occurrence. In: Arnott R, Finger S, Smith C (eds) *Trepanation: History, Discovery, Theory*. Swets & Zeitlinger, Lisse, 55–78
- Rodríguez-Martín C (2006) Identification and differential diagnosis of traumatic lesions of the skeleton. In: Schmitt A, Cunha E, Pinheiro J (eds) *Forensic anthropology and medicine: complementary sciences from recovery to cause of death*. Humana Press, New Jersey, pp 197–221
- Spekker O, Hunt DR, Paja L, Molnár E, Pálfi GY, Schultz M (2020a) Tracking down the white plague: the skeletal evidence of tuberculous meningitis in the Robert. J Terry Anatomical Skeletal Collection *Plos ONE* 15(3):e0230418. <https://doi.org/10.1371/journal.pone.0230418>
- Spekker O, Schulz M, Paja L, Váradi OA, Molnár E, Pálfi GY, Hunt DR (2020b) Tracking down the white plague. Chapter two: the role of endocranial abnormal blood vessel impressions and periosteal appositions in the paleopathological diagnosis of tuberculous meningitis. *PLoS ONE* 15(9):e0238444. <https://doi.org/10.1371/journal.pone.0238444>
- Spekker O, Hunt DR, Berthon W, Paja L, Molnár E, Pálfi GY, Schulz M (2021a) Tracking down the white plague. Chapter three: revision of endocranial abnormally pronounced digital impressions as paleopathological diagnostic criteria for tuberculous meningitis. *PLoS ONE* 16(3):e0249020. <https://doi.org/10.1371/journal.pone.0249020>
- Spekker O, Hunt DR, Berthon W, Molnár E, Pálfi GY (2021b) Insights into the diagnostic efficacy and macroscopic appearance of endocranial bony changes indicative of tuberculous meningitis: three example cases from the Robert J. Terry Anatomical Skeletal Collection. *Int J Osteoarchaeol* <https://doi.org/10.1002/oa.3079>
- Steinbock RT (1976) *Paleopathological diagnosis and interpretation: bone diseases in ancient human population*. Thomas, Springfield, Illinois
- Stewart TD (1958) Stone age skull surgery: a general review, with emphasis on the new world. *Annu rep Board Regents Smithsonian Inst* 469–491.
- Szilvássy J (1978) Eine Methode zur Altersbestimmung mit Hilfe der sternalen Gelenksflächen der Schlüsselbeine. *Mitt Anthropol Ges Wien* 108:166–168
- Tihanyi B, Bereczki Zs, Molnár E, Berthon W, Révész L, Dutour O, Pálfi GY (2015) Investigation of Hungarian Conquest Period (10th c. AD) archery on the basis of activity-induced stress markers on the skeleton – preliminary results. *Acta Biol Szeged* 2015, 59(1):65–77.
- Tihanyi B, Berthon W, Kis L, Váradi OA, Dutour O, Révész L, Pálfi GY (2020) “Brothers in arms”: activity-related skeletal changes observed on the humerus of individuals buried with and without weapons from the 10th-century CE Carpathian Basin. *Int J Osteoarchaeol* 30(6):798–810. <https://doi.org/10.1002/oa.2910>
- Tomka P (2000) Régészeti kommentár a Lébény-Kaszás 10–11. századi temető 44. sírjának trepanált koponyaleletéhez. *Arrabona - Múz közl Győr* 38/1–2.
- Váradi OA, Horváth O, Marcsik A, Molnár E, Pálfi GY, Bereczki Zs (2015) Különlleges formájú jelképes trepanációk a Dél-Alföldről. *Anthropol Köz* 56:91–104. <https://doi.org/10.20330/AnthropolKozl.2015.56.91>
- Verano JW (2003) Trepanation in prehistoric South America: geographic and temporal trends over 2000 years. In: Arnott R, Finger S, Smith C (eds) *Trepanation: history, discovery, theory*. Swets & Zeitlinger, Lisse, 223–236
- Verano JW (2016) Differential Diagnosis: Trepanation *Int J Paleopathol* 14:1–9. <https://doi.org/10.1016/j.ijpp.2016.04.001>
- Wicker E (2004) Észak-Bácska a hódoltság korában. In: Bárth, J (ed) *Cumania, A Bács-Kiskun Megyei Önkormányzat Múzeumi Szervezetének Évkönyve, Kecskemét* 20:5–121.
- Zias J, Pomeranz S (1992) Serial craniectomies for intracranial infection 5.5 millenia ago. *Int J Osteoarchaeol* 2:183–186
- Zimmerman MR, Trinius E, Lemay M, Aufderheide AC, Reyman TA, Marrocco GR, Shultes RE, Coughlin EA (1981) Trauma and trepanation in a Peruvian mummy. *Am J Phys Anthropol* 55:497–501

Publisher's note Springer Nature remains neutral with regard to jurisdictional claims in published maps and institutional affiliations.