

Original Article

# The Diagnostic Value of a New Fecal Marker, Matrix Metalloprotease-9, in Different Types of Inflammatory Bowel Diseases

Klaudia Farkas,<sup>a</sup> Zoltán Saródi,<sup>a</sup> Anita Bálint,<sup>a</sup> Imre Földesi,<sup>a</sup> László Tiszlavicz,<sup>b</sup> Mónika Szűcs,<sup>c</sup> Tibor Nyári,<sup>c</sup> János Tajti,<sup>d</sup> Ferenc Nagy,<sup>a</sup> Zoltán Szepes,<sup>a</sup> Renáta Bor,<sup>a</sup> Anita Annaházi,<sup>a</sup> Richárd Róka,<sup>a</sup> Tamás Molnár<sup>a</sup>

<sup>a</sup>First Department of Medicine, University of Szeged, Hungary <sup>b</sup>Department of Pathology, University of Szeged, Hungary <sup>c</sup>Department of Medical Physics and Informatics, University of Szeged, Hungary <sup>d</sup>Department of Surgery, University of Szeged, Hungary

Corresponding author: Tamás Molnár, MD, PhD, First Department of Medicine, University of Szeged, H-6720, Korányi fasor 8, Szeged, Hungary. Tel: +36-62-545186; Fax: +36-62-545185; E-mail: molnar.tamas@med.u-szeged.hu

## Abstract

**Background:** Only limited data are available regarding the diagnostic accuracy of fecal matrix metalloprotease-9 [MMP-9] for inflammatory bowel disease [IBD]. The aims of our study were to assess the diagnostic accuracy of fecal MMP-9 in patients with active Crohn's disease [CD], ulcerative colitis [UC], and pouchitis, and to compare the diagnostic accuracy of fecal MMP-9 and fecal calprotectin [CP] in IBD.

**Methods** Stool and blood samples were collected in 50 CD, 54 UC, and 34 ileal pouch-anal anastomosis patients before control endoscopies were performed. Biopsies were taken for histologic purposes. The activities of CD, UC, and pouchitis were defined with the use of clinical, endoscopic, and histologic activity scores. Fecal CP and MMP-9 levels were quantified by enzyme-linked immunosorbent assay.

**Results** Active CD, UC, and pouchitis were detected in 38%, 54%, and 29% of the patients, respectively. A significant correlation was revealed between fecal CP and the clinical activities of CD and UC, and between fecal CP and the endoscopic activity of UC and pouchitis. Fecal MMP-9 did not correlate with any of the activity indices of CD; however, strong associations were shown between fecal MMP-9 and clinical, endoscopic, and histologic activities of both UC and pouchitis.

**Conclusions** This is the first study assessing the diagnostic accuracy of MMP-9 in different types of IBD. Our results showed that fecal MMP-9 has high sensitivity in the detection of endoscopically active UC and pouchitis. These non-invasive methods help assess intestinal inflammation.

**Keywords:** Crohn's disease; ulcerative colitis; pouchitis; calprotectin; matrix metalloprotease-9

## 1. Background

The two main types of inflammatory bowel diseases [IBD]—Crohn's disease [CD] and ulcerative colitis [UC]—are characterized by periods of remission and of relapse. Symptoms, laboratory parameters and the results of endoscopies and other imaging modalities are used

in the assessment of disease activity. For monitoring the course and the activity of the disease and the response to different therapies, laboratory and fecal markers proved helpful; however, a biomarker that is absolutely specific to CD or UC has still not been developed. Intestinal inflammation, typical to both diseases, is associated with an acute-phase reaction with the migration of leukocytes to the

affected area of the gut. The reason why fecal markers seem to be more specific to assess disease activity than laboratory markers in IBD is the fecal excretion of leukocytes, leukocyte products, and serum proteins.<sup>1</sup> The most commonly used fecal activity marker is calprotectin [CP]. CP, derived predominately from neutrophils, can differentiate between active and inactive IBD and between IBD and irritable bowel syndrome [IBS]. It correlates with the severity of symptoms and may predict relapse—especially in the case of UC.<sup>2,3</sup> Finally, it can be used as a surrogate marker for the endoscopic response during treatment, given that a normal value of CP is a reliable marker for mucosal healing.<sup>4</sup>

Matrix metalloproteases [MMPs] are also released from the neutrophil secretory granules. MMP 1, 2, 3, and 9 have been detected in significantly higher levels in colonic biopsies of UC patients than in controls.<sup>5</sup> MMP-9 has been shown to be significantly increased in the stool of UC patients compared with healthy controls and patients with IBS, and was found to correlate to a high degree with the clinical and endoscopic activity of UC, as well as with fecal CP.<sup>6</sup> A recently published paper on pediatric patients also confirmed the efficacy of fecal MMP-9 in the separation of IBD and non-IBD patients.<sup>7</sup> Since the role of this new fecal activity marker, MMP-9, has previously not been compared in different types of IBD, the aim of our prospective study was to assess the diagnostic accuracy of fecal MMP-9 in patients with active CD, UC, and pouchitis, assessed by clinical, endoscopic, and histologic scores, and to compare the diagnostic accuracy of fecal MMP-9 and fecal CP in IBD.

## 2.1 Patients and Methods

### 2.2. Study population

Overall, 50 CD (female/male ratio: 26/24; mean age at CD diagnosis: 30 years; disease location: ileal: 11, colonic: 15, ileocolonic: 24, upper gastrointestinal [GI]: 3), 54 UC [female/male ratio: 28/26; mean age at UC diagnosis: 36 years; disease extent: proctitis: 8, left-sided colitis: 24, extensive: 22] and 34 ileal pouch-anal

anastomosis [IPAA] [female/male ratio: 18/16; mean age at UC diagnosis: 28 years] patients were enrolled in the study. Demographics, duration, and characteristics of the diseases were recorded. The activities of CD, UC, and pouchitis were defined with the use of clinical, endoscopic, and histologic activity scores: Crohn's Disease Activity Index [CDAI],<sup>8</sup> Simplified Endoscopic Activity Score for Crohn's Disease [SES-CD],<sup>9</sup> and D'Haens score<sup>10</sup> in case of CD, Mayo score [including partial and endoscopic subscore]<sup>11</sup> and Riley score<sup>12</sup> in the case of UC, and Pouchitis Disease Activity Index [PDAI]<sup>13</sup> in the case of pouchitis, including the clinical, endoscopic, and histologic assessments of patients with IPAA. The D'Haens score is a widely used scoring system for histologic abnormalities in CD mucosal biopsy specimens that combines active inflammatory changes and chronic architectural changes.<sup>14,15</sup>

Clinically active CD and UC were defined as CDAI > 150 points and pMayo score > 2. Pouchitis was defined as PDAI > 7 points. SES-CD was defined as follows: inactive 0–3; mild 4–10; moderate 11–19; and high ≥ 20. The patients' demographic and clinical data are summarized in Table 1.

A colonoscopy was performed to evaluate the endoscopic activity in every patient. A day before endoscopy, we requested that patients provide fecal samples. Blood samples were also obtained within 13 days before endoscopy.

### 2.3. Blood inflammatory markers, fecal CP and MMP-9 measurements

Routine laboratory methods were used to determine C-reactive protein, serum iron level, leukocyte number, hematocrit, hemoglobin levels, and the thrombocyte number.

Stool samples were obtained and stored at -20°C until the determination of fecal CP and MMP-9 levels. For CP measurements, fecal specimens were thawed at 4°C. CP level was quantified by use of enzyme-linked immunosorbent assay [Quantum Blue, Bühlmann Laboratories, Schönenbuch] according to the manufacturer's

**Table 1.** Demographic data and clinical characteristics of patients enrolled in the study.

Characteristics	Patients with CD [n = 50]	Patients with UC [n = 54]	Patients with ileal pouch-anal anastomosis [n = 34]
Mean age at onset [years]	30	36	28
Mean age at present [years]	38	43	40
Female/male	26/24	28/26	18/16
Location/extension			
-Ileal	11	-	-
-Colonic	15	-	-
-Ileocolonic	24	-	-
-Upper GI	3	-	-
-Extensive	-	22	-
-Left-sided	-	24	-
-Proctitis	-	8	-
Behavior			
-Inflammatory	18	-	-
-Stenosing	18	-	-
-Penetrating	14	-	-
Treatment			
-No therapy	7	7	12
-Aminosalicylates	13	34	0
-Steroids	15	15	0
-Thiopurines	22	16	0
-Biologics	14	9	5
-Antibiotics	10	-	8
-Topical	2	12	2

CD, Crohn's disease; UC, ulcerative colitis; GI, gastrointestinal.

instructions. For MMP-9 measurements, 1g of fecal sample was diluted, mixed, homogenized in 4 mL of ice-cold Tris-buffer [0.15 M NaCl + 20 mM Tris-HCl, pH 8.3] and then centrifuged. MMP-9 was also measured by quantitative enzyme-linked immunosorbent assay [R&D Systems, Abingdon, UK].

## 2.4. Colonoscopy, histologic examination

The participants underwent a colonoscopy performed by two experienced endoscopists [TM, ZSZ], either for activity symptoms or simply for a control examination, to evaluate the macroscopic inflammation of the colon or the pouch. Biopsies were taken for histology during the endoscopy. Histologic variables were scored by a single pathologist [LT].

## 2.5. Statistical analyses

Correlations between fecal CP, MMP-9, and clinical, endoscopic and histologic activity scores were determined by analysis of variance [ANOVA]. The *p*-value of equal to or less than 0.05 was considered statistically significant. STATA 9 [StataCorp., TX, 2005] was used to analyze data. The cut-off levels, specificity, and sensitivity were calculated using the receiver operating characteristic [ROC] analysis. The cut-off level was calculated in the event that the value of the area under the ROC curve [AUC] was above 0.89, determined by the maximum value of Youden's index [sensitivity + specificity-1].

## 2.6. Ethical considerations

The study protocol was approved by the Ethical Committee of the University of Szeged. All subjects provided written and informed consent to participation.

# 3. Results

## 3.1 Endoscopic and disease activity

Endoscopically active CD was revealed in 70.7% of the patients [26.9% mild, 14.6% moderate, 29.2% severe activity]. In UC, endoscopic activity was detected in 83.3% [27.8% mild, 14.8% moderate, 40.7% severe]. The median value of SES-CD was 1 [interquartile range [IQR]: 0 to 1.25] in patients with endoscopically inactive and 14 [IQR: 8 to 24] in endoscopically active CD. In UC, the median value of the eMayo score was 0 in inactive and 2 [IQR: 1 to 3] in active patients. Pouchitis was detected in 50% of the patients; the median PDAI was 10, and the median endoscopic subscore of PDAI was 3 [IQR: 2 to 4]

in patients with pouchitis. The median values of the D'Haens and Riley scores in endoscopically active CD and UC patients were 8 [IQR: 7 to 9] and 13 [IQR: 6.5 to 14], respectively. The median of the histologic score of pouchitis was 4 [IQR: 2 to 5]. The median of the CDAI was 210 [IQR: 183 to 275] and 80 [IQR: 61 to 113] and the median of the pMayo score was 6 [IQR: 4 to 6] and 1 [IQR: 0 to 1] in the clinically active and inactive CD and UC patients, respectively.

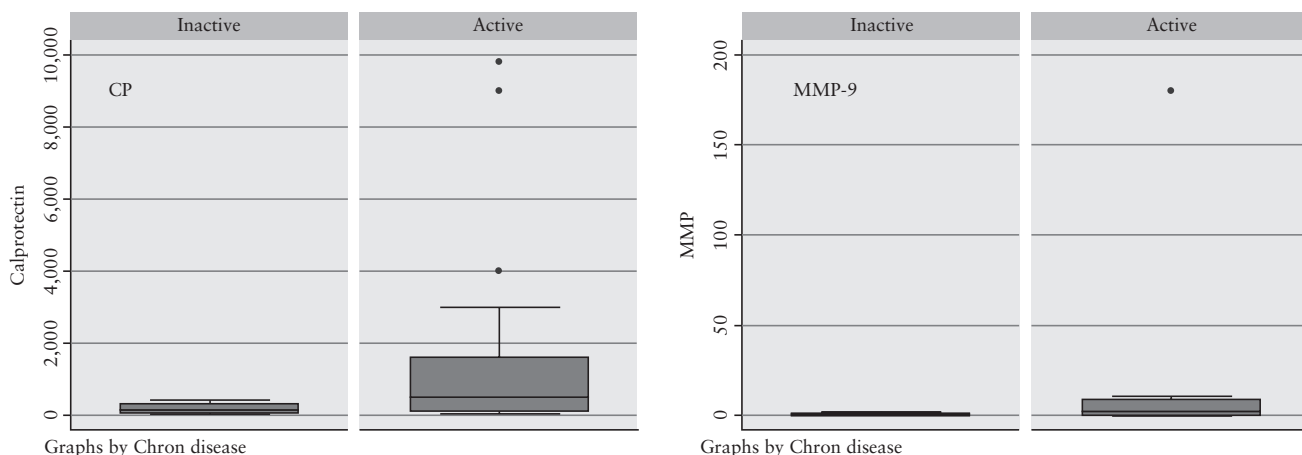
## 3.2 Fecal CP and MMP-9 levels in CD patients

Median fecal CP was 500 µg/g and MMP-9 was 1.53 ng/mL in endoscopically active and 142 µg/g and 0.61 ng/mL in endoscopically inactive patients, respectively. Median fecal CP concentrations were 650 and 159 µg/g in patients with clinically active and inactive disease, respectively. Fecal CP concentration significantly correlated with the CDAI [*p* = 0.012]. However, no correlation was found between fecal CP concentration and SES-CD and histologic activity. Interestingly, after analyzing the data in view of the disease location, a significant correlation was revealed between fecal CP concentration and the CDAI in patients with a colonic location, as opposed to those with ileal and ileocolonic locations [*p* = 0.03 vs 0.5 and 0.06, respectively]. Median MMP-9 concentrations were 1.53 and 0.95 ng/mL in patients with active and inactive disease, respectively. Fecal MMP-9 did not correlate with the CDAI, nor with the SES-CD or the D'Haens score. The cut-off value could not be calculated since the AUC was well below 0.89. Correlation between fecal CP and MMP-9 showed borderline significance [*r* = 0.39, *p* = 0.06]. Box-and-whisker plots for comparisons of fecal CP and MMP-9 medians between endoscopically active and non-active CD are shown in Figure 1.

## 3.3 Fecal CP and MMP-9 levels in UC patients

Median fecal CP was 300 µg/g and MMP-9 was 6.17 ng/mL in endoscopically active patients and 121 µg/g and 0.7 ng/mL in endoscopically inactive patients. Median fecal CP concentrations were 630 and 146 µg/g in patients with clinically active and inactive disease, respectively. Fecal CP correlated with the pMayo score [*p* = 0.05] and with the endoscopic Mayo score [*p* = 0.017], but not with the Riley score. The median MMP-9 concentrations were 6.62 and 0.81 ng/mL in patients with clinically active and inactive disease, respectively. Fecal MMP-9 concentration correlated with clinical [*p* = 0.05], endoscopic and histologic activity [*p* = 0.021 and *p* = 0.033, respectively] of the disease.

Although AUC could not reach the optimal 0.89 in the case of clinical nor in the case of endoscopic activity, the cut-off values could



**Figure 1.** Box-and-whisker plots for comparison of faecal CP and MMP-9 medians between endoscopically active and non-active CD

be determined. The best cut-off of MMP-9 for the separation of clinically active and inactive UC patients was 0.35 ng/mL, with a sensitivity of 93% and a specificity of 63% [AUC = 0.74]. In the case of endoscopic activity, the optimal cut-off value proved to be 0.20 ng/mL, with a sensitivity of 96% and a specificity of 75% [AUC = 0.806] [Figure 2]. Significant correlation was shown between fecal CP and MMP-9 levels [ $r = 0.73$ ,  $p < 0.001$ ]. Box-and-whisker plots for comparisons of fecal CP and MMP-9 medians between endoscopically active and non-active UC are shown in Figure 3.

### 3.4 Fecal CP and MMP-9 levels in patients with and without pouchitis

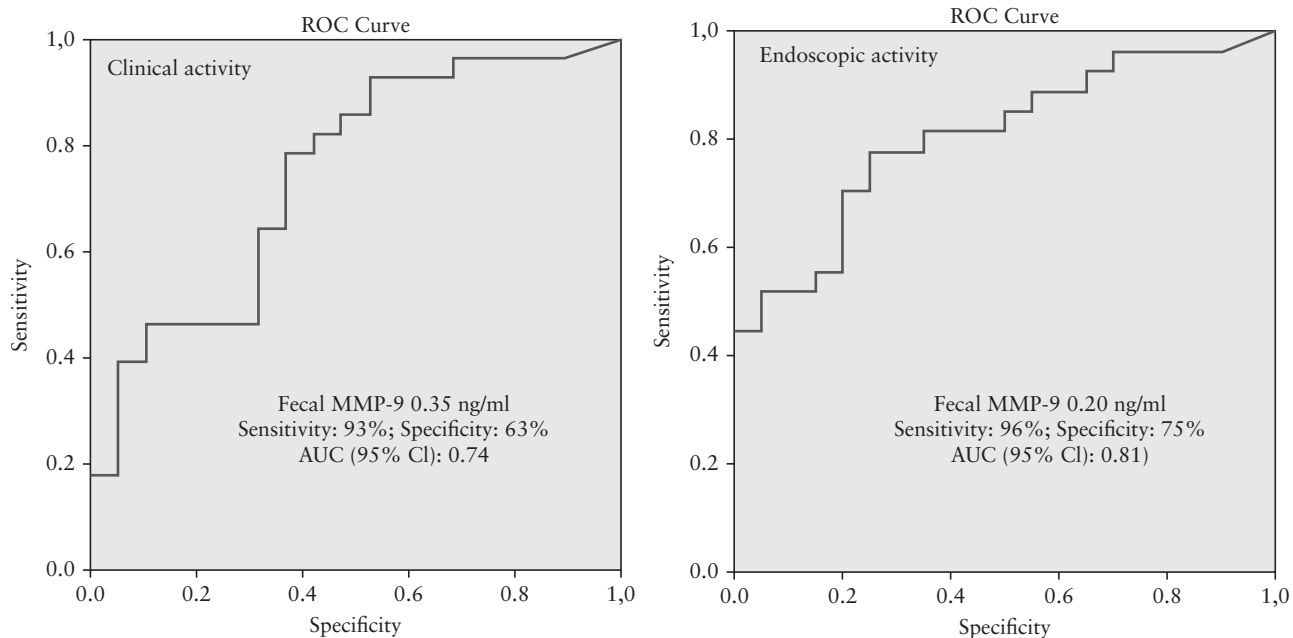
The median fecal CP concentration was 560 µg/g in patients with pouchitis and 96.5 µg/g in those without pouchitis. Statistically, the fecal CP correlated with the endoscopic and the histologic activity of pouchitis [ $p = 0.0001$ ,  $p = 0.0002$ ]. The median fecal MMP-9 level was significantly higher in patients with [16.9 ng/mL] vs without [1.34 ng/mL] pouchitis [ $p = 0.009$ ]. Fecal MMP-9 also correlated with the endoscopic and histologic activity of patients with IPAA

[ $p = 0.011$  and  $p = 0.002$ , respectively]. For MMP-9, the cut-off value was revealed to be 0.24 ng/mL with a sensitivity and specificity of 87% when examining both clinical and endoscopic activities [AUC = 0.73 and 0.76, respectively] [Figure 4]. Significant correlation was shown between fecal CP and MMP-9 levels [ $r = 0.55$ ,  $p = 0.009$ ]. Box-and-whisker plots for comparisons of fecal CP and MMP-9 medians between endoscopically active and non-active IPAA patients are shown in Figure 5.

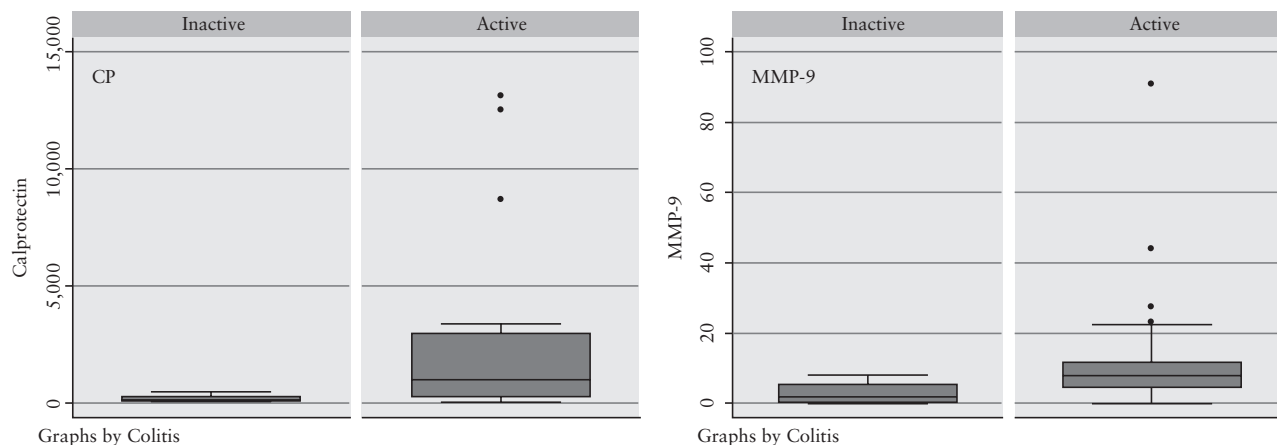
Correlation of fecal CP and MMP-9 with the clinical, endoscopic, and histologic activities in CD, UC, and pouchitis are summarized in Table 2.

### 3.5. Correlation between the inflammatory laboratory parameters and different types of IBD and between the therapy and the correlations of fecal markers

The median values of the CRP levels were 21 mg/L and 4.95 mg/L in clinically active and inactive CD, 8.6 mg/L and 2.15 mg/L in active and inactive UC, and 14.2 mg/L and 5 mg/L in patients with and without pouchitis, respectively. None of the laboratory markers correlated



**Figure 2.** ROC curves for faecal MMP-9 levels in UC



**Figure 3.** Box-and-whisker plots for comparisons of faecal CP and MMP-9 medians between endoscopically active and non-active UC

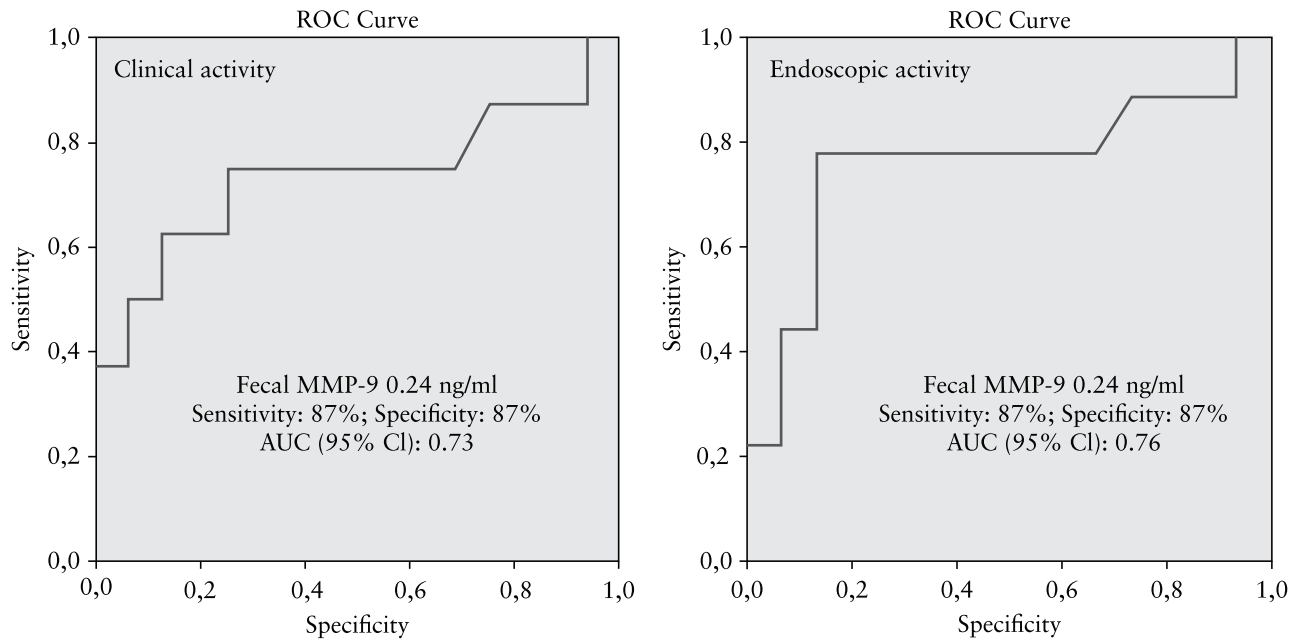


Figure 4. ROC curves for faecal MMP-9 in pouchitis

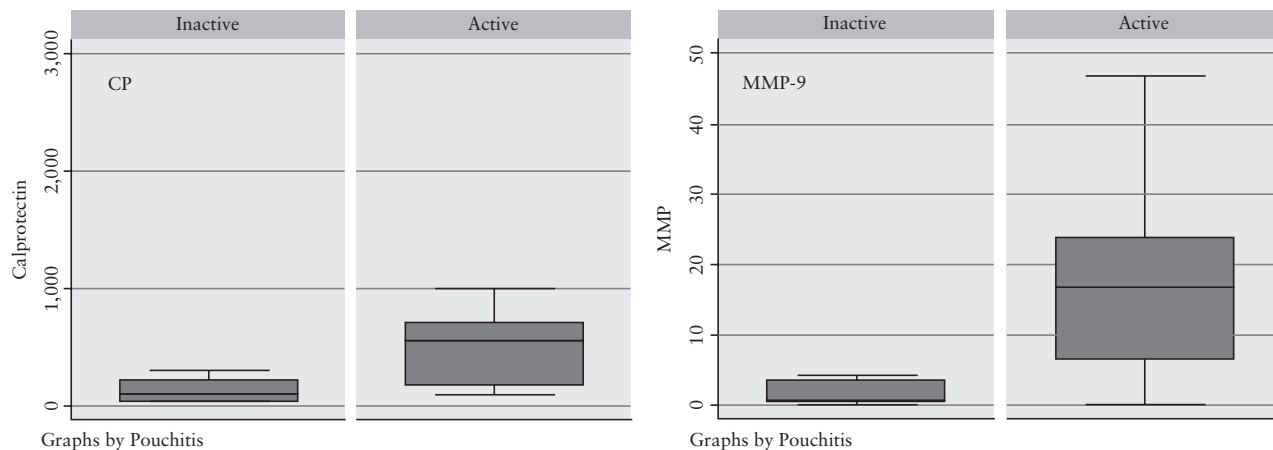


Figure 5. Box-and-whisker plots for comparisons of faecal CP and MMP-9 medians between endoscopically active and non-active IPAA patients

significantly with CP and MMP-9 in CD and UC. However, in pouchitis a significant correlation was shown between both CP and MMP-9 and an elevated thrombocyte level [the median thrombocyte number in pouchitis: 305.5 g/L;  $p = 0.012$  and  $p < 0.0002$ , respectively]. In this cohort no association was shown between the therapy and the different correlations of fecal activity markers.

#### 4. Discussion

This prospective study revealed significant correlation between fecal CP and the endoscopic activity of both UC and pouchitis. Strong association was revealed between fecal MMP-9 and clinical, endoscopic, and histologic activities of both UC and pouchitis. The assessment of mucosal inflammation is known to be crucial in optimizing therapy in patients with IBD. Therefore, non-invasive markers, substituting for endoscopy, play a very important role in the follow-up of the patients. CP is a widely studied fecal activity marker in IBD. It proved to be effective for measuring intestinal inflammation, since the fecal concentration of CP is elevated both

in CD and UC.<sup>16,17,18</sup> It appears to better reflect disease activity in UC than in CD, but fecal CP has not been found to be useful in distinguishing UC from CD.<sup>19,20</sup> Very few data are available regarding the role of fecal MMP-9 in diagnosing and predicting disease activity in IBD. MMPs partake in normal mucosal defence, as well as playing a role both in the evolution of the inflammatory processes and in the pathogenesis of inflammatory diseases.<sup>21</sup> The study of Mäkitalo *et al.* revealed that serum levels of MMP-7, 8, and 9 are elevated in active IBD. In this study, MMP-7 was the most prominent marker that indicated a response to steroid therapy.<sup>22</sup> Although the authors could not demonstrate alterations in MMP-9 levels following the therapy, serum MMP-9 levels were elevated at baseline in patients with active IBD. These results did not support a role for serum MMP-9 as a marker for disease activity; however, a previous study confirmed an increased expression of MMP-9 in the mucosa of IBD patients.<sup>23</sup> We previously confirmed that fecal MMP-9 is a reliable marker in separating UC and non-IBD patients, the higher levels being associated with more active disease.<sup>6</sup> The first study on fecal MMP-9 in pediatric patients revealed that MMP-9 levels were

**Table 2.** Correlation of fecal CP and MMP-9 with the clinical, endoscopic, and histologic activities in CD, UC, and pouchitis.

CD	CP [ $\mu\text{g/g}$ ]		Fecal MMP-9 [ $\text{ng/ml}$ ]	
	r	p-Value	r	p-Value
CDAI	0.304	0.012	0.572	0.129
SES-CD	0.453	0.062	0.002	0.450
D'Haens	0.264	0.182	0.556	0.178
UC	CP [ $\mu\text{g/g}$ ]		Fecal MMP-9 [ $\text{ng/ml}$ ]	
	R	P values	R	P values
pMayo score	0.402	0.05	0.287	0.05
eMayo score	0.391	0.017	0.381	0.021
Riley score	0.269	0.258	0.426	0.033
IPAA	CP [ $\mu\text{g/g}$ ]		Fecal MMP-9 [ $\text{ng/ml}$ ]	
	R	P values	R	P values
PDAI	0.188	0.091	0.595	0.009
Endoscopic subscore	0.138	0.001	0.384	0.011
Histological subscore	0.133	0.002	0.547	0.002

CP, fecal calprotectin; MMP-9, matrix metalloproteinase-9; CD, Crohn's disease; UC, ulcerative colitis; CDAI, Crohn's Disease Activity Index; SES-CD, Simplified Endoscopic Activity Score for Crohn's disease; IPAA, ileal pouch-anal anastomosis; PDAI, Pouch Disease Activity Index.

significantly lower in CD than in UC, whereas fecal CP was not useful in differentiating pediatric UC and CD.<sup>7</sup>

Our study aimed to examine fecal MMP-9, a very new fecal activity marker for such indication, and whether the diagnostic accuracy of fecal MMP-9 is comparable with fecal CP. The patient samples included some taken from patients on maintenance treatment, who were referred for a colonoscopy. As our results showed, fecal CP was not useful in differentiating patients with CD and UC, as the values were comparable, confirming the above mentioned data. However, fecal MMP-9 showed a stronger association with UC than with CD, and also correlated solely with the clinical symptoms of pouchitis in our cohort. It is also important to note that fecal MMP-9 correlated not only with clinical activities of UC and pouchitis, but also with endoscopic and histologic activities, and thus can be useful for assessing mucosal inflammation during the follow-up period.

Whereas the diagnostic role of fecal CP in pouchitis has previously been examined in some studies, limited data are available on the role of MMP-9 in pouchitis. In the case of pediatric-onset UC patients, most pouch samples showed an increased expression of MMP-3 and MMP-7 in pouchitis.<sup>24</sup> MMP-1 and MMP-2 concentrations in the mucosal biopsies were increased in pouchitis compared with uninfamed pouches of patients with UC, in the study of Stallmach *et al.*<sup>25</sup> Ullisse *et al.* revealed strong MMP-9 and MMP-2 activities in the inflamed pouch, reduced after antibiotic treatment.<sup>26</sup>

Our results revealed that none of the routinely used laboratory activity markers correlates significantly with fecal CP and MMP-9 levels in CD or UC. In pouchitis, fecal markers correlated only with thrombocytosis. Thrombocytosis is a common finding in IBD, suggestive of active disease. Correlation between thrombocytosis and elevated fecal markers can be explained by the fact that both are potential markers of clinical disease activity. The level of fecal CP significantly increased in clinically active colonic CD and UC, although fecal MMP-9 showed a significantly stronger correlation with the activity of UC than with that of CP, and this was the only marker correlating with the clinical symptoms of pouchitis. Significant correlation was also shown between fecal CP and MMP-9 levels in patients with UC and pouchitis.

The authors are aware of the limitations of the study. The main limiting factor of the study is the relatively low number of enrolled

patients with regard to the different types of the studied disease; however, the accurately performed diagnostic and scoring procedures and statistical analyses are strengths of this study.

## 5. Conclusion

This is the first study assessing the diagnostic accuracy of fecal MMP-9 in the different types of IBD. Our results showed that fecal MMP-9 has high sensitivity in the detection of endoscopically active UC and pouchitis, and these non-invasive methods help in assessing intestinal inflammation.

## Funding

This work was supported by the János Bolyai Research Scholarship of the Hungarian Academy of Sciences [BO/00632/14/5], and TAMOP-4.2.2.A-11/1/KONV-2012-0035, TAMOP-4.2.2.A-11/1/KONV-2012-0052 TAMOP-4.2.2.A-11/1/KONV-2012-0073, and OTKA PD 105948.

## Author contributions

Study design, data collection, supervision of patient selection, and manuscript preparation: KF, AB, TM; data collection: A, ZS, KF; endoscopic examinations: TM, ZS; histologic evaluation of the biopsy samples: LT; statistical analysis and manuscript preparation: TM, KF, MS, TN; data collection and manuscript preparation: KF, AB, FN, ZS, AA, RR; supervision of patient selection and manuscript preparation: TM T. All authors have approved the final draft submitted. TM is guarantor of the article.

*Conflict of interest:* None.

## References

- Desai D, Faubion WA, Sandborn WJ. Review article: biological activity markers in inflammatory bowel disease. *Aliment Pharmacol Ther* 2007;25:247–55.
- Schoepfer AM, Beglinger C, Straumann A, *et al.* Fecal calprotectin correlates more closely with the Simple Endoscopic Score for Crohn's disease [SES-CD] than CRP, blood leukocytes, and the CDAI. *Am J Gastroenterol* 2010;105:162–9.



3. De Vos M1, Louis EJ, Jahnsen J, *et al.* Consecutive fecal calprotectin measurements to predict relapse in patients with ulcerative colitis receiving infliximab maintenance therapy. *Inflamm Bowel Dis* 2013;19:2111–7.
4. Judd TA, Day AS, Lemberg DA, *et al.* Update of fecal markers of inflammation in inflammatory bowel disease. *J Gastroenterol Hepatol* 2011;26:1493–9.
5. Baugh MD, Perry MJ, Hollander AP, Davies DR, *et al.* Matrix metalloproteinase levels are elevated in inflammatory bowel disease. *Gastroenterology* 1999;117:814–22.
6. Annahazi A, Molnar T, Farkas K, *et al.* Fecal MMP-9: A new noninvasive differential diagnostic and activity marker in ulcerative colitis. *Inflamm Bowel Dis* 2013;19:316–20.
7. Kolho KL, Sipponen T, Valtonen E, *et al.* Fecal calprotectin, MMP-9, and human beta-defensin-2 levels in pediatric inflammatory bowel disease. *Int J Colorectal Dis* 2014;29:43–50.
8. Best WR, Becktel JM, Singleton JW, Kern F Jr. Development of a Crohn's disease activity index: National Cooperative Crohn's Disease Study. *Gastroenterology* 1976;70:439–44.
9. Daperno M, D'Haens G, Van Assche G, *et al.* Development and validation of a new, simplified endoscopic activity score for Crohn's disease: the SES-CD. *Gastrointest Endosc* 2004;60:505–12.
10. D'Haens G, Geboes K, Peeters M, *et al.* Early lesions of recurrent Crohn's disease caused by infusion of intestinal contents in excluded ileum. *Gastroenterology* 1998;114:262–7.
11. Schroeder KW, Tremaine WJ, Ilstrup DM. Coated oral 5-aminosalicylic acid therapy for mildly to moderately active ulcerative colitis. A randomized study. *N Engl J Med* 1987;317:1625–9.
12. Riley SA, Mani V, Goodmon MJ, *et al.* A reproducible grading scale for histological assessment of inflammation in ulcerative colitis. *Gut* 2000;47:404–9.
13. Sandborn WJ, Tremaine WJ, Batts KP, *et al.* Pouchitis after ileal pouch-anal anastomosis: a pouchitis disease activity index. *Mayo Clin Proc* 1994;69:409–15.
14. D'Haens G, Deventer S, Hogezaand R, *et al.* Endoscopic and histological healing with infliximab anti-tumor necrosis factor antibodies in Crohn's disease: A European Multicenter Trial. *Gastroenterology* 1999;116:1029–34.
15. Tytgat GN, Tytgat SHAJ. Grading and Staging in Gastroenterology. New York, NY: Thieme, 2008.
16. Røseth AG, Schmidt PN, Fagerhol MK. Correlation between fecal excretion of indium-111-labelled granulocytes and calprotectin, a granulocyte marker protein, in patients with inflammatory bowel disease. *Scand J Gastroenterol* 1999;34:50–54.
17. Tibble J, Teahon K, Thjodleifsson B, *et al.* A simple method for assessing intestinal inflammation in Crohn's disease. *Gut* 2000;47:506–13.
18. Costa F, Mumolo MG, Bellini M, *et al.* Role of fecal calprotectin as non-invasive marker of intestinal inflammation. *Dig Liver Dis* 2003;35:642–7.
19. Costa F, Mumolo MG, Ceccarelli L, *et al.* Calprotectin is a stronger predictive marker of relapse in ulcerative colitis than in Crohn's disease. *Gut* 2005;54:364–8.
20. Quail MA, Russell RK, Van Limbergen JE, *et al.* Fecal calprotectin complements routine laboratory investigations in diagnosing childhood inflammatory bowel disease. *Inflamm Bowel Dis* 2009;15:756–9.
21. Goetzl EJ, Banda MJ, Leppert D. Matrix metalloproteinases in immunity. *J Immunol* 1996;156:1–4.
22. Mäkitalo L, Rintamäki H, Tervahartiala T, *et al.* Serum MMPs 7–9 and their inhibitors during glucocorticoid and anti-TNF- $\alpha$  therapy in pediatric inflammatory bowel disease. *Scand J Gastroenterol* 2012;47:785–94.
23. Baugh MD, Perry MJ, Hollander AP, *et al.* Matrix metalloproteinase levels are elevated in inflammatory bowel disease. *Gastroenterology* 1999;117:814–22.
24. Mäkitalo L, Piekkala M, Ashorn M, *et al.* Matrix metalloproteinases in the restorative proctocolectomy pouch of pediatric ulcerative colitis. *World J Gastroenterol* 2012;18:4028–36.
25. Stallmach A, Chan CC, Ecker KW, *et al.* Comparable expression of matrix metalloproteinases 1 and 2 in pouchitis and ulcerative colitis. *Gut* 2000;47:415–22.
26. Ulisse S, Gionchetti P, D'Alò S, *et al.* Expression of cytokines, inducible nitric oxide synthase, and matrix metalloproteinases in pouchitis: effects of probiotic treatment. *Am J Gastroenterol* 2001;96:2691–99.