

Monika MIKLASZEWSKA<sup>1</sup>  
 Katarzyna ZACHWIEJA<sup>1</sup>  
 Dorota DROŹDŹ<sup>1</sup>  
 Éva PÁLLINGER<sup>2</sup>  
 Beáta TAKÁCS<sup>3</sup>  
 Ágnes SZILÁGYI<sup>3</sup>  
 Dorottya CSUKA<sup>3</sup>  
 Zoltán PROHÁSZKA<sup>3</sup>

<sup>1</sup>Department of Pediatric Nephrology,  
 Jagiellonian University Medical College,  
 Cracow, Poland;  
 Head:  
 Prof. Dorota Drożdż MD, PhD.

<sup>2</sup>Semmelweis University, Department of  
 Genetics, Cell- and Immunobiology, Budapest,  
 Hungary  
 Head:  
 Prof. Edit Buzás MD, DSc

<sup>3</sup>Semmelweis University, 3rd Department  
 of Medicine, Research Laboratory and Füst  
 György Complement Diagnostic Laboratory,  
 Budapest, Hungary  
 Head:  
 Prof. Zoltán Prohászka MD, DSc

**Additional key words:**  
 atypical hemolytic uremic syndrome  
 membrane cofactor protein  
 Mycoplasma pneumoniae infection

**Dodatkowe słowa kluczowe:**  
 atypowy zespół hemolityczno-mocznicowy  
 błonowy kofaktor białkowy  
 zakażenie Mycoplasma pneumoniae

Address for correspondence:  
 Dr. Monika Miklaszewska  
 Wielicka St. 265  
 30-663 Kraków, Poland  
 E-mail address: mmiklasz@wp.pl

## Hemolytic uremic syndrome with Mycoplasma pneumoniae infection and membrane cofactor protein mutation – case report

Zespół hemolityczno-mocznicowy w przebiegu zakażenia Mycoplasma pneumoniae oraz mutacją błonowego kofaktora białkowego - opis przypadku

**Background:** Thrombotic microangiopathies (TMA) are rare life-threatening diseases of various etiologies, making the identification of the specific forms and appropriate treatment difficult. The aim of this work is to present the history of a patient with atypical hemolytic uremic syndrome (aHUS) that developed in the context of Mycoplasma pneumoniae infection. **Case presentation:** A 5 - year old, Caucasian, previously healthy girl presented with symptoms of HUS, without preceding diarrhoea and with ongoing upper respiratory tract infection. ADAMTS13 deficiency and presence of Shiga-like toxin producing E. coli (STEC) was excluded, and the diagnosis of aHUS verified. She required peritoneal dialysis for 4 days and fresh frozen plasma (FFP) treatment was started with good clinical response. Serological investigation for Mycoplasma pneumoniae was positive (IgM) leading to the initiation of clarithromycin therapy. The complement profile (classical pathway activity, C3 and C4 serum levels were slightly decreased, no signs of alternative pathway dysregulation) was indicative for classical pathway activation and consumption. The genetic screening revealed a novel non-synonymous variation in the CD46 (MCP) gene in heterozygous form that causes a proline to leucine change at codon 155 of the MCP (P155L). The CD46 P155L variation was associated in the samples of the patient and family members with decreased MCP protein expression on the surface of granulocytes. In addition to the P155L mutation, multiple frequent aHUS risk variations were also identified. **Conclusion:** The diagnosis of aHUS is challenging and is based mainly on the exclusion of ADAMTS13 deficient thrombotic thrombocytopenic purpura (TTP) and typical HUS caused by STEC. Our patient had single-episodic HUS in the context of upper-airway infection, and finally a functionally relevant CD46 (MCP) mutation was identified. The complexity of aHUS,

**Wstęp:** Mikroangiopatie zakrzepowe są to rzadkie, zagrażające życiu choroby o zróżnicowanej etiologii, co sprawia, że szczegółowa ich diagnostyka oraz ustalenie optymalnego postępowania terapeutycznego są niezwykle trudne. Celem pracy jest przedstawienie przypadku dziewczynki z atypowym zespołem hemolityczno – mocznicowym (aZHM), do którego rozwoju doszło w trakcie zakażenia Mycoplasma pneumoniae. Opis przypadku: 5 – letnia, dotychczas zdrowa dziewczynka, rasy kaukaskiej została przyjęta do Kliniki Nefrologii Dziecięcej z objawami ZHM, bez poprzedzającej biegunki, z objawami trwającej infekcji górnych dróg oddechowych. Po wykluczeniu niedoboru ADAMTS13 oraz zakażenia STEC (Shiga-like toxin producing E. coli) - postawiono rozpoznanie aZHM. Dziewczynka przez 4 doby wymagała leczenia dializą otrzewnową, ponadto zastosowano wlewy świeżo mrożonego osocza (FFP) z dobrym rezultatem. W badaniach serologicznych stwierdzono obecność przeciwciał przeciwko Mycoplasma pneumoniae w klasie IgM i włączono leczenie klarytromycyną. Badanie składowych układu dopełniacza (stwierdzono nieznacznie obniżone aktywności C3c i C4, bez cech wskazujących na zaburzenia w drodze alternatywnej) - wskazywało na aktywację drogi klasycznej. Badanie genetyczne wykazało do tej pory nie opisaną, heterozygotyczną mutację w genie CD46 (MCP) powodującą zamianę proliny na leucynę w kodonie 155 białka MCP (P155L). Mutacja CD46 P155L jest związana z obniżeniem ekspresji błonowego kofaktora białkowego (membrane cofactor protein – MCP, CD46) na powierzchni granulocytów u pacjentki i członków jej rodziny. Ponadto, w tej rodzinie stwierdzono liczne dodatkowe polimorfizmy genetyczne będące czynnikami ryzyka aZHM. **Wnioski:** Diagnostyka aZHM jest trudna i w praktyce klinicznej opiera się na wykluczeniu niedoboru ADAMTS13 (czyli plamicy małopłytkowej

and the importance of the requirement for full differential diagnostic workup of all HUS cases is further highlighted by the current case history.

zkrzepowej - TTP) oraz typowego ZHM (STEC-ZHM). W opisanym przypadku - u dziecka miał miejsce jeden epizod ZHM w przebiegu zakażenia górnych dróg oddechowych, a szczegółowa diagnostyka genetyczna doprowadziła do identyfikacji mutacji w białku CD46. Złożoność etiologii aZHM oraz kliniczna waga problemu – wymagają rozważenia przeprowadzenia pełnej diagnostyki we wszystkich przypadkach aZHM.

### Background

Thrombotic microangiopathies (TMAs) are rare, life-threatening diseases with various etiologies. Clinical features that define HUS include the presence of acute kidney injury, microangiopathic hemolytic anemia and acute thrombocytopenia. Most cases of pediatric HUS (90% of cases) are associated with diarrhea and bacterial infections secreting Shiga-like toxins that provoke endothelial damage. Less frequently various other etiologies may lead to the development of HUS, including invasive *Streptococcus pneumoniae* infection and Influenza A infection.

According to the recently published consensus [1] the term aHUS should be reserved for patients with HUS without coexisting disease. However, the diagnosis of aHUS can be especially challenging, if aHUS triggering factors, such as infections, are also present.

In the majority of aHUS patients dysregulation of complement alternative pathway is based on mutations, risk variations or copy

number variations in the genes encoding membrane cofactor protein (CD46), factor I (CFI), factor B (CFB), C3 (C3), factor H (CFH), factor H related proteins 1-5 (CFHR1-5) or thrombomodulin (THBD); or is based on the presence of autoantibodies against factor H (DEAP-HUS) [2]. The diagnosis of aHUS is challenging and based on the exclusion of various clinical states. Here we present the differential diagnostic workup of a patient who presented with a single episode of HUS precipitated by an upper-airway infection caused by *Mycoplasma pneumoniae*.

### Case presentation

A 5 - year old, previously healthy, Caucasian girl presented to Department of Pediatric Nephrology with vomiting, petechiae on the lower extremities, yellowish sclera, systolic heart murmur, weakness, catarrhal infection and oliguria which had been present for 2 days. In the medical history there had been signs of upper airway infection for 3 days, but no diarrhea. On the admission day the

patient developed anuria which lasted for 1 day, there was no elevated blood pressure or signs of pneumonia present, vital parameters were stable, the general clinical state was satisfactory. Laboratory test results were suggestive for HUS: hemolytic anemia, thrombocytopenia, acute renal failure, elevated LDH activity, proteinuria and haematuria were recorded (see Tab. I). Ultrasound examination revealed slightly enlarged, hyperechogenic kidneys with maintained medullary – cortical differentiation. Microbiological, serological and additional specific investigations excluded STEC- or Influenza A infection and ADAMTS13 deficiency (Tab. I), but verified the presence of acute infection with *Mycoplasma pneumoniae* (MP) by IgM positivity on the second in-hospital day. The diagnosis of atypical HUS (aHUS) was set, the mild MP infection was considered as disease triggering factor, and FFP treatment introduced with clarithromycin therapy. Starting on the 5<sup>th</sup> day renal- and hematological parameters along with LDH activity improved. On the follow-up visit (11 months later) the

Table I

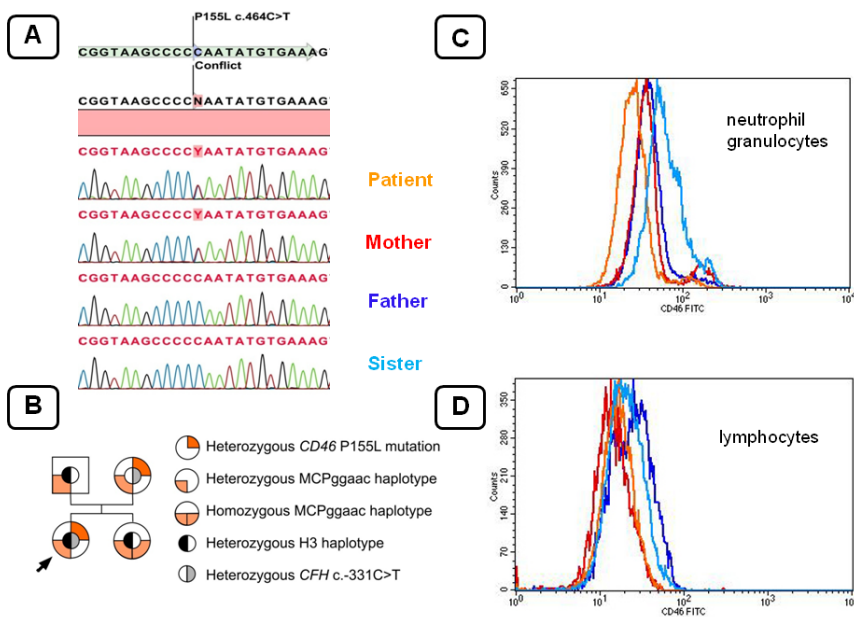
Detailed laboratory features and therapeutic activity during the whole disease course of the patient.

\*Further complement parameters, including alternative pathway activity and concentrations of C1q, factor H, factor I, factor B, anti-factor H IgG autoantibody were in the reference range (data not shown).

Wyniki badań laboratoryjnych oraz postępowanie terapeutyczne u Pacjentki w czasie trwania choroby.

\*Pozostałe parametry układu dopełniacza, w tym drogi alternatywnej oraz stężenia C1q, czynnika H, czynnika I, czynnika B, przeciwciał IgG przeciw czynnikowi H - mieściły się w zakresie wartości prawidłowych (dane nie zawarte).

Parameter/Follow-up day	1 (06-12-2014)	2	3	4	5	6	7	8	9	10	11	12	17	40	335
Hemoglobin [g/l]	97	91	81	79	69		110	116		116		121	124	113	127
Hematocrite [%]	28.9	25.2	27	24	20.8		32.4	35.2		35.5		37.6	36.8	33.3	38.8
White Blood Cells/ml	6000	8900	8800	9000	6700		8900	10800		8200		6600	6800	5100	6240
Platelet number x1000/ml	15	10	27	109	162		332	422		552		549	322	296	310
BUN [mmol/l]	30		22.8	17.8	9.2					6.8			5.8	5.1	4.7
Serum creatinine [μmol/l]	121.6	106.8	110	99.2	57.9	66.5	57	41.7		38		38.2	34.8	32.2	38.3
LDH [U/L]	7669		4403	2350	1735		1682			1266			819	655	627
Urine: Protein [g/l]		12.42	1.4		0	trace				0.71		trace	0	0	0
Urine: Erythrocytes/hpf		80-120	3 - 10		0-6	10-20				3 - 10		0 - 3	0-3	0-3	0-4
Urine: volume [ml]	0	590	750	1330	880	1200	1410	1150	1030	1080	1349	1050	870	normal	normal
CystatinC [mg/l]			1.76	0.75										0.64	0.72
CRP [mg/l]	12.4		28			9.6							<5.0		<5.0
Direct antiglobulin test	negative														
Blood Pressure	116/ 78	107/ 68	102/ 63	111/ 79	108/ 64	138/ 85	102/ 65	139/ 89	143/ 66	132/ 94	124/ 86	131/ 93	112/ 74	95/ 59	86/ 68
FFP transfusion [ml]			240	240	240	240									
RBC transfusion [ml]					220										
RRT		CAPD	CAPD	CAPD	CAPD										
<b>Complement measurements*:</b>															
CH50 (48-103 CH50/ml)	47														56
C3 (0.9-1.8 g/l)	0.87														1.0
C4 (0.15-0.55 g/l)	0.10														0.13



**Figure**  
Molecular genetic and surface expression analysis of membrane cofactor protein (MCP, CD46) in the patient (arrow) and in her family members. Panel A: Parts of chromatograms showing the localization of the CD46 P155L (c.464C>T) variation. Panel B: Family tree with inheritance of the CD46 P155L mutation and additional frequent aHUS risk variations. Panels C (neutrophil granulocytes) and D (lymphocytes) show histograms of MCP protein expression as determined by fluorescence activated cell sorter (FACS) analysis.

Genetyczna analiza molekularna oraz ekspresja błonowego kofaktora białkowego (membrane cofactor protein – MCP, CD46) u Pacjenta (strzałka) oraz u jej członków rodziny.

Panel A. Obrazy chromatografii obrazujące lokalizację mutacji CD46 P155L (c.464C>T).

Panel B. Drzewo genealogiczne obrazujące dziedziczenie mutacji CD46 P155L oraz dodatkowe, częste czynniki ryzyka aHUS.

Panel C, D. Histogramy obrazujące ekspresję MCP na granulocytach (C) oraz limfocytach (D) oznaczone metodą FACS (fluorescence activated cell sorter - cytometria sortowania komórek w polu elektrycznym).

patient was in a good clinical condition and her laboratory results are within normal limits. Detailed investigation of the complement profile revealed slightly decreased classical pathway activity, lower C3 and C4 serum levels, whereas alternative pathway components and regulators were in reference range (Tab. I). Disorders in the complement profile were considered as infection related, but since the diagnosis of aHUS was established, detailed genetic analysis of complement components was initiated.

The genetic analyses revealed a novel missense variation in the CD46 gene in heterozygous form (c.464C>T) that causes a proline to leucine amino acid change (P155L) in the MCP protein (Figure 1). Family screening revealed that the P155L mutation was inherited maternally while the healthy sister and the father did not carry the mutation. Since all of the applied *in silico* prediction tools (SIFT, PROVEAN, PolyPhen-2, MutationTaster) predicted this novel variation as damaging, the functional consequences of this mutation were explored by fluorescence-activated cell sorter analysis (FACS). MCP expression was examined on the white blood cells of the patient and on the cells of her family members proving that the P155L mutation is linked to decreased MCP expression, especially on granulocytes (Fig. 1).

Furthermore, the MCPggaac aHUS risk haplotype [3] was present in the patient

and in her parents (all heterozygous) as well as in the healthy sister (homozygous). In addition, the patient was found to be homozygous variant for the c.-331C>T polymorphism and heterozygous for the CFH H3 risk haplotype [4].

### Discussion

In 10-15% of aHUS patients mutations are found in the transmembrane alternative pathway regulator MCP [2]. MCP is expressed on the surface of most nucleated cells including the kidney and endothelial cells, and is protecting cells from complement damage. MCP binds C3b through its extracellular domains, and acts as a cofactor of factor I in the inactivation of C3b into iC3b [5]. Mutations and polymorphisms in CD46 gene may affect the function or expression of the protein, most of them are located in the four extracellular SCR domains and result in reduced MCP surface expression [1]. In the present case the mutation affects the SCR2 domain of MCP, and seems to be functionally relevant causing decreased cell surface expression of MCP.

There are a number of considerations on the patient history. First, a complement profile without characteristic disorders of alternative pathway dysregulation in the acute disease stage - does not exclude complement mediated aHUS. Second, the complex genetic analysis of all aHUS patients and

also the family members is indicated to identify predisposing factors and to allow planning of management. Third, this patient had single episodic HUS that developed after *Mycoplasma pneumoniae* infection, and had multiple genetic predisposing factors in complement regulators. Hence, we classify the disease as complement mediated aHUS, precipitated by an infection. The therapeutic response was prompt and complete in response to plasma therapy complying with previous experiences [5].

*Mycoplasma pneumoniae* is a common etiologic agent of community-acquired pneumonia. Some patients may experience extrapulmonary manifestations but HUS as a complication of this infection is extremely rare. It could involve various possible mechanisms, such as direct effects of pro-inflammatory cytokines induced by lipoproteins in the bacterial cell and vascular occlusion due to vasculitis or thrombosis.

### Conclusions

Our case history exemplifies the necessity of genetic analysis for all patients having clinically diagnosed aHUS, even if no complement dysregulation can be identified. Remarkably, rare genetic alterations are not the only factors responsible for the development of aHUS, but risk variations or haplotypes are important determinants. Our case history also demonstrates the requirement for an additional environmental factor (infection in our case) to act as disease precipitating trigger in the presence of genetic predisposition.

### References

- Loirat C, Fakhouri F, Ariceta G, Besbas N, Bitzan M. et al: An international consensus approach to the management of atypical hemolytic uremic syndrome in children. *Pediatr Nephrol.* 2016; 31: 15-39.
- Sanchez-Corral P, Melgosa M: Advances in understanding the aetiology of atypical Haemolytic Uraemic Syndrome. *Brit J Haematol.* 2010; 150: 529-542.
- Esparza-Gordillo J, Goicoechea de Jorge E, Buil A, Carreras Berges L, López-Trascasa M. et al: Predisposition to atypical hemolytic uremic syndrome involves the concurrence of different susceptibility alleles in the regulators of complement activation gene cluster in 1q32. *Hum Mol Genet.* 2005; 14: 703-712.
- Córdoba SR, Jorge EG: Translational mini-review series on complement factor H: genetics and disease associations of human complement factor H. *Clin Exp Immunol.* 2008; 151: 1-13.
- Fremaux-Bacchi V, Moulton EA, Kavanagh D, Dragon-Durey MA, Blouin J. et al: Genetic and functional analyses of membrane cofactor protein (CD46) mutations in atypical hemolytic uremic syndrome. *J Am Soc Nephrol.* 2006; 17: 2017-2025.

**Acknowledgements:** We thank I. Szigeti, M. Kókai, Zs Szendrei for technical assistance. This study was supported by Hungarian National Research Fund (OTKA 100687 (ZP)).

**Financial Disclosure:** The authors have no financial relationships relevant to this article to disclose.

**Competing Interest:** The authors have no competing interest to disclose.

**Consent to publish:** Authors confirm that they have obtained consent to publish from the participant's parents to report individual patient data.