

THE EMERGENCE OF TUBERCULOSIS IN LATE NEOLITHIC TRANS-DANUBIA

KITTI KÖHLER, BALÁZS MENDE¹
ANNAMÁRIA PÓSA²

Between 2006 and 2009, during the excavations pursued prior to the construction of the M6 motorway, a large settlement and nearly 2400 burials of the Late Neolithic-Early Copper Age Lengyel culture were unearthed at Alsónyék-Bátaszék (Fig. 1) in Tolna County, South East Transdanubia.³ According to our present knowledge the site is the most extensive Neolithic settlement and cemetery from the 5th millennium BC (Fig. 2) regarding the Carpathian Basin, as well as Central Europe.⁴ In the course of the still ongoing anthropological and thorough paleopathological examination of the human skeletal finds of the graves, a case showing the classic symptoms of tuberculosis (TB) has been found.

Tuberculosis is one of the oldest infectious diseases, which has been hitting the human race for several millennia. It took its heaviest toll at the time when industrialization gained speed in the 18th–19th century, among physical workers living in poverty at a low level of hygiene, but it did not spare the higher social classes either. The disease, an endemic, was also represented in the art – music and literature – of the age as a tragic phenomenon that broke the career of talented youths (e.g. the novel *The Magic Mountain* by Thomas Mann, or Erich Maria Remarque's *Three Comrades*). After Robert Koch discovered the pathogen of the disease in 1882, the introduction of different antibiotics and the BCG vaccine, as well as the effective propaganda and the establishment of TB clinics and medical examination centers contributed towards overcoming the disease by the second half of the 20th century (Figs 3–4). However, by the turn of the millennium the number of infected people grew significantly, so

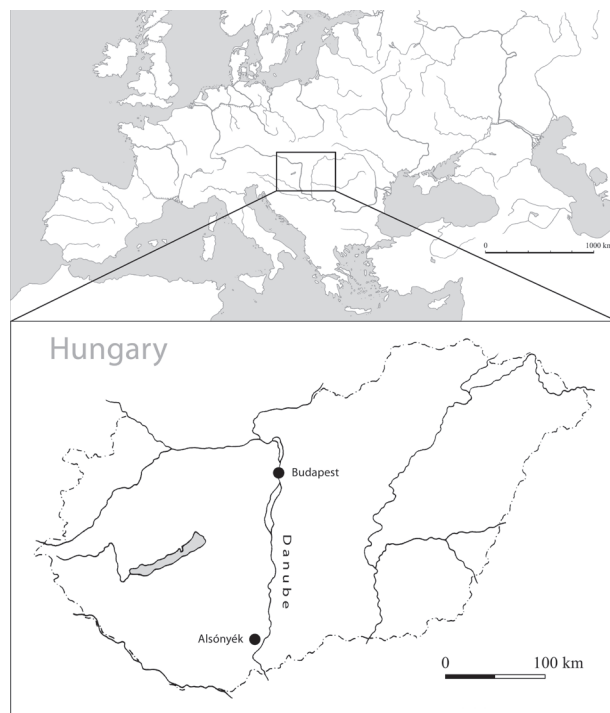

Fig. 1: Alsónyék-Bátaszék (made by Zsolt Réti)



Fig. 2: Aerial photograph of the site (photo by Archeosztráda Ltd)

¹ Archaeological Institute of the HAS

² SZTE TTIK Department of Anthropology

³ The excavations were executed by members of the Institute of Archaeology, Research Center for the Humanities, Hungarian Academy of Sciences – Archeosztráda Ltd, and Ásatárs Ltd. as well as the Service of Cultural Heritage Protection.

⁴ Zalai-Gaál, István – Osztás, Anett: A Lengyeli kultúra települése és temetője Alsónyék-Kanizsa-dűlőben [A settlement and cemetery of the Lengyel culture in Alsónyék-Kanizsa-dűlő]. In: *Medínától Etéig*, szerk. Bende, Livia – Lőrinczy, Gábor (Szeged: Móra Ferenc Múzeum, 2009), 245–254; Gallina, Zsolt – Hornok, Péter – Paluch, Tibor – Somogyi, Krisztina: Előzetes jelentés az M6 AP TO 10/B és 11. számú lelőhelyrészen végzett megelőző feltárásról. *Alsónyék-Bátaszék (Tolna megye) 2006–2009. A Wosinsky Mór Múzeum Évkönyve* 32 (2010), 7–100.

the research on the history of the TB has become sadly timely again. The main reason of the upsurge of the disease is the excellent evolutionary ability of *Mycobacteria*. The known human pathogenic *Mycobacterium* genera present themselves with new and newer multiresistant strains impervious to antibiotic treatment, among them to those anti-tubercular drugs that were earlier used against them.⁵

The pathogens of tuberculosis are bacterial species belonging to the *Mycobacterium tuberculosis* complex. Human infections today are usually caused by *M. tuberculosis*, which spreads among humans by aerosol droplets. In earlier times, however, a greater proportion of infections were caused by *M. bovis*, which spread by the consumption of the milk and meat of infected bovine species.⁶

It is characteristic of TB that after inhaling the pathogen those infected with primer tuberculosis recover spontaneously, but the infection can remain in the body of the seemingly recovered people. The pulmonary nodules containing the TB bacteria often encyst for years, and clinical symptoms only recur in the case of a repeated infection, superinfection, or as a result of the weakening of the immune system. The onset of the illness can frequently be mistaken for a cold, influenza, indigestion, or exhaustion. General symptoms are fatigability, exhaustion, loss of appetite, malfunction of digestion, apathy, weight loss, sleeping disorder, night sweats. Coughing with the accompanying bloody sputum occurs solely when the lungs are affected.

The affection of the skeleton is only observable at 3–7% of the people suffering from tuberculosis. The osseous system gets infected primarily through the bloodstream and the lymphatic system. The characteristic traits of advanced osteoarticular tuberculosis can be observed with a simple morphological method as well. Its “classic” symptoms occur on the spine (*spondylitis tuberculosa*), most often in the lower thoracic and lumbar region. Typical osteological lesions may also develop at the joints exposed to serious strain, or on the skull, on the petrous part of the temporal bones and on the facial bones, and it can also leave rather characteristic marks on the fingers in the form of circular bone loss.⁷

The paleopathological recognition of the early stage of the disease is far more difficult. In the last decades of diagnostics progress has resulted from the observation of atypical osteological syndromes characteristic of the early stages of infections (such as traces of periostitis on the inner surface of the ribs, multiple cavities occurring on the anterior surface of the vertebral bodies, characteristic deformations on the inner surface of the skull),⁸ as well as from examinations finding evidence of *M. tuberculosis* infection on the basis of DNA analysis.⁹

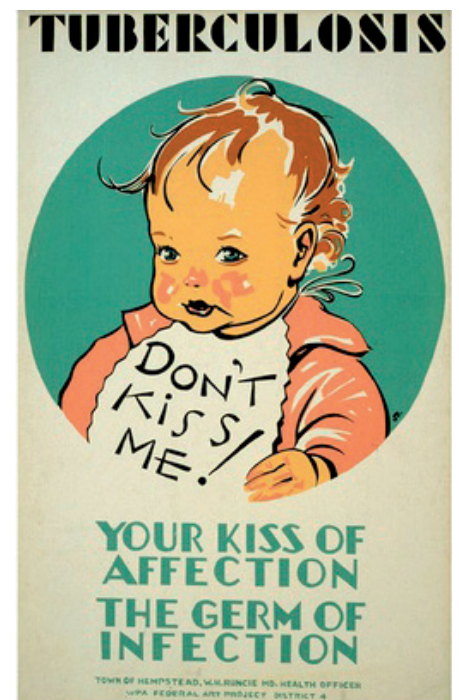


Fig. 3–4: Campaign against tuberculosis between the two world wars. Posters by Erik Hans Krause

⁵ WHO 2011. Global tuberculosis control: surveillance, planning, financing. WHO Report, Geneva.

⁶ Marcsik, Antónia – Molnár, Erika – Ösz, Brigitta: *Specifikus fertőző megbetegedések csontelváltozásai történeti népességek körében* [Bone distortions of specific infectious diseases in historical populations]. (Szeged: Szegedi Egyetem Kiadó, 2006).

⁷ Ibid.; Ortner, Donald J.: *Identification of pathological conditions in human skeletal remains*. Second Edition. (San Diego: Academic Press, 2003).

⁸ Baker, Benda J.: Early manifestations of tuberculosis in the skeleton. In: *Tuberculosis. Past and present*, eds Pálfi, György – Dutour, Olivier – Deák, Judit – Hutás, Imre (Budapest-Szeged: Golden Book Publishers and Tuberculosis Foundation, 1999), 301–311.

⁹ Donoghue, Helen D.: Human tuberculosis – an ancient disease, as elucidated by ancient microbial biomolecules. *Microbes and Infection* 11 (2009), 1156–1162.



Fig. 5: “In situ” excavation photo of the man buried in grave No. 4027. (photo by Archeosztráda Ltd)

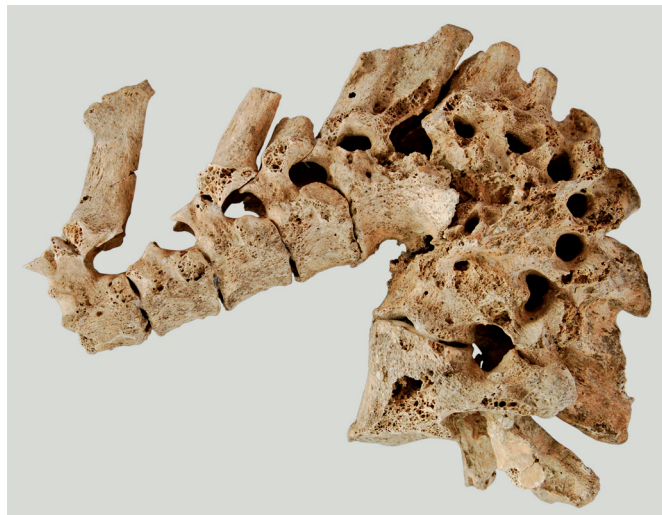

Fig. 6: The classic Pott's curvature observed on the spinal column of the man (photo by Fanni Fazekas)




Fig. 7: Synostosis at the 8th and 9th thoracic vertebrae (photo by Fanni Fazekas)



Fig. 8: Tuberculous bone loss at the lower part of the 9th thoracic vertebra (photo by Fanni Fazekas)

In the Alsónyék series the “classic” deformations typical of tuberculosis were found on the remains of an adult male skeleton buried in grave No. 4027 resting on four wooden pillars.¹⁰ The severe vertebral damage was already well visible during the excavation (Fig. 5). The most characteristic alterations occurred on the segment between the 4th lumbar and 10th thoracic vertebrae. On this segment of the spinal column the decay, collapse and fusion of vertebrae are observable, which lead to the characteristic wedge-shaped bending in the arch of the spinal column, leading to the development of the so-called Pott's curvature (Fig. 6). Further synostosis occurred at the 8th and 9th thoracic vertebrae (Fig. 7). Deep cavities are observable at the lower part of the body of the 9th thoracic vertebra, which destroyed about half of the body (Fig. 8). Macroscopic observation was completed with radiological examinations (Fig. 9), clearly showing the total destruction of

¹⁰ Köhler, Kitti – Pálfi, György – Molnár, Erika – Zalai-Gaál, István – Oszás, Anett – Bánffy, Eszter – Kirinó, Katalin – Kiss, K. Katalin – Mende, Balázs Gusztáv: A Late Neolithic Case of Pott's Disease from Hungary. *International Journal of Osteoarchaeology* (2012), doi: 10.1002/oa.2254.

the bone structure of the affected vertebral bodies; the spaces between the vertebrae are not visible.¹¹

The Alsónyék case is certainly of outstanding importance from the perspective of the history of epidemics. The oldest (ca. 11–10 000-year-old) skeletal finds showing traces of TB are known from the Pre-Neolithic period of the Middle East, from the territories of Iraq, Jordan and Israel.¹² From Neolithic Europe a small, but progressively growing number of case histories have been known. In Hungary, five cases showing atypical symptoms have been recorded from the Hódmezővásárhely-Gorzsa site of the Late Neolithic Tisza Culture.¹³ In the Late Neolithic period of the Carpathian Basin the appearance of the disease can be connected to the demographic changes, the progressively increasing number of population, hence to the greater density of population at the settlements, which is the main breeding ground of infectious diseases.

It is observable in the cemeteries of the Lengyel culture, thus in Alsónyék as well, that the graves are arranged in groups (Fig. 10), yet it has not been established whether the groups were based on family ties, according to domestic units, or whether they were created simply by burying those who died around the same time at the same place.

Further on, apart from the person showing the classic symptoms of the disease buried in grave No. 4027, we are going to examine the presence of the atypical syndrome on all of the skeletal finds excavated in this group of graves, in cooperation with the Department of Anthropology of the University of Szeged. We are also going to investigate whether the DNA remnants of the pathogen can be detected on the bones. Thus, the infection will be possible to confirm even in those skeletons where it could not be established with the methods of traditional anthropology.¹⁴

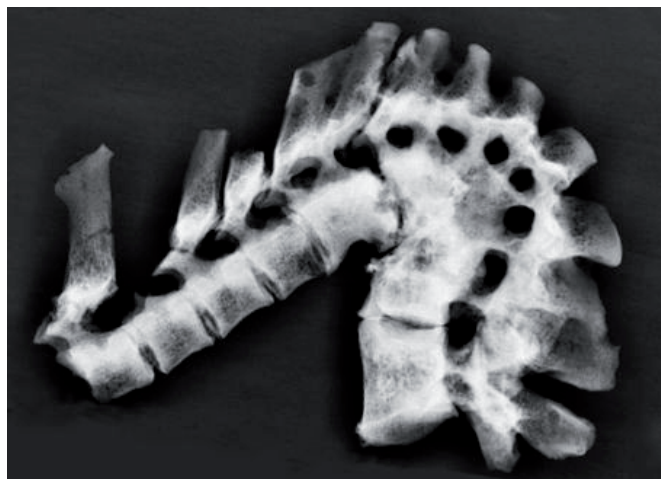

Fig. 9: X-ray image of the spinal column (taken by Katalin K. Kiss)



Fig. 10: Photo of a group of graves (photo by Archeosztráda Ltd)

¹¹ The examinations were carried out by K. Katalin Kiss at the Radiology and Oncotherapy Clinic of Semmelweis University.

¹² Hershkovitz, Israel – Donoghue, Helen D. – Minnikin, David E. – Besre, Gurdyal S. – Lee, Oona-Y-C. – Gernaey, Angela M. – Galili, Ehud – Eshed, Vered – Greenblatt, Charles L. – Lemma, Eshetu – Bar-Gal, Gila Kahila – Spigelman, Mark: Detection and Molecular Characterization of 9000-Year-Old Mycobacterium tuberculosis from a Neolithic Settlement in the Eastern Mediterranean. *PLoS ONE* 3 (2008), e3426.

¹³ Masson, Muriel: Tuberculosis at the Late Neolithic site of Hódmezővásárhely-Gorzsa, Hungary. *13th Annual Conference of the British Association for Biological Anthropology and Osteoarchaeology. Programme and Abstracts* (University of Edinburgh, 2011), 27–28.

¹⁴ The ongoing DNA research is realized in the framework of the OTKA K 81230 project at the EURAC Institute for Mummies and the Iceman in Bolzano. According to its preliminary results, further TB-infected individuals occur.

RECOMMENDED LITERATURE

ROBERTS, CHARLOTTE A. – BUIKISSTRA, JANE E.

The Bioarchaeology of Tuberculosis. A Global View on a Reemerging Disease. Gainesville: University Press of Florida, 2003.

DORMANDY, THOMAS

The White Death: A History of Tuberculosis. New York University Press, 2000.

KÖHLER, KITTI – PÁLFI, GYÖRGY – MOLNÁR, ERIKA – ZALAI-GAÁL, ISTVÁN – OSZTÁS, ANETT – BÁNFFY, ESZTER – KIRINÓ, KATALIN – KISS, K. KATALIN – MENDE, BALÁZS GUSZTÁV

A Late Neolithic Case of Pott's Disease from Hungary. *International Journal of Osteoarchaeology* (2012), doi: 10.1002/oa.2254.

MARCSIK, ANTÓNIA – MOLNÁR, ERIKA – SZATHMÁRY, LÁSZLÓ

The antiquity of tuberculosis in Hungary: the skeletal evidence. *Memória do Instituto Oswaldo Cruz* 101 (2006)/2, 67–71.