

# The year in cardiovascular medicine 2022: the top 10 papers in cardiovascular imaging

Chiara Bucciarelli-Ducci<sup>1,2</sup>, Nina Ajmone-Marsan<sup>3</sup>

<sup>1</sup>Royal Brompton and Harefield Hospitals, Guys' and St Thomas NHS Foundation Trust  
London, UK

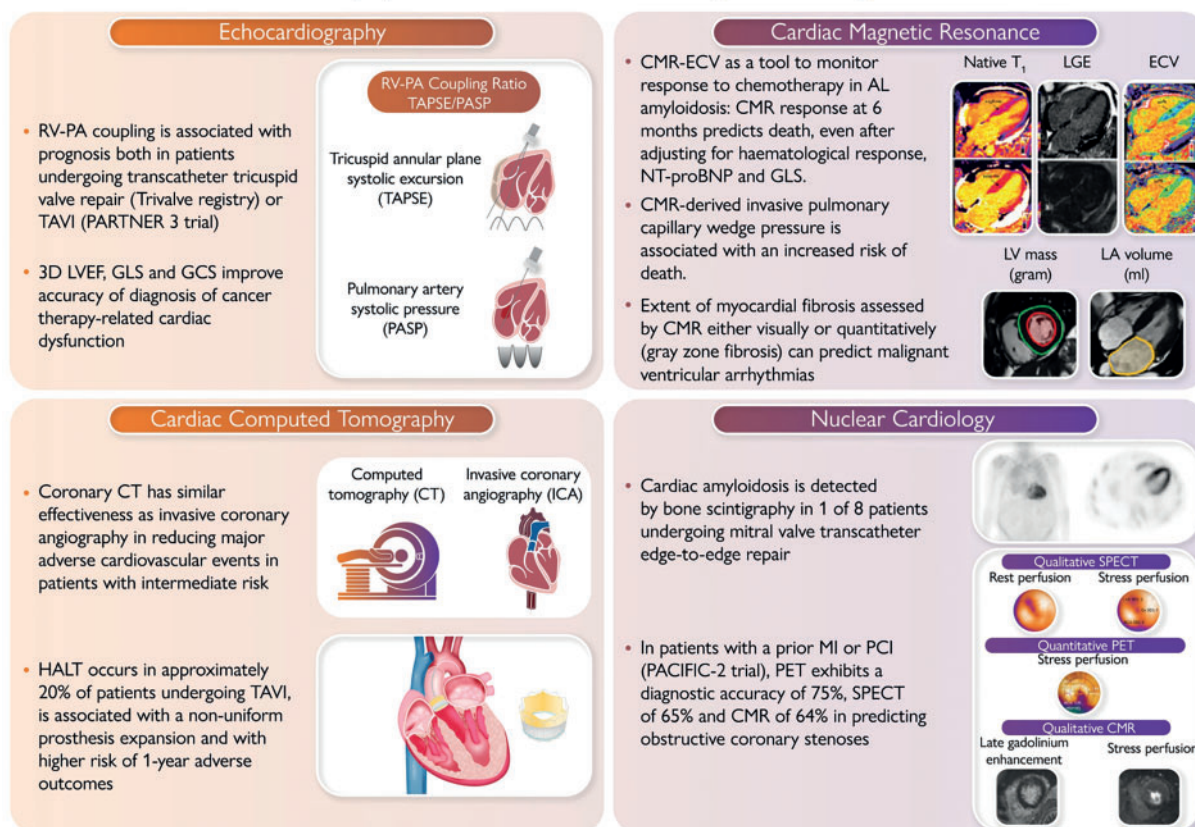
<sup>2</sup>School of Biomedical Engineering and Imaging Sciences, Faculty of Life Sciences and Medicine, Kings College  
London, UK

<sup>3</sup>Department of Cardiology, Leiden University Medical Center, Leiden, Netherlands

Corresponding author.

Chiara Bucciarelli-Ducci, MD, Tel: + 44 (0) 207 351 8800, E-mail: c.bucciarelli-ducci@rbht.nhs.uk

## The Year in Imaging: ten papers that could become game changers



**GRAPHICAL ABSTRACT** The year in imaging: 10 papers that could become game changers. RV: right ventricle; PA: pulmonary artery; TAVI: transcatheter aortic valve implantation; LVEF: left ventricular ejection fraction; GLS: global longitudinal strain; GCS: global circumferential strain; CT: computed tomography; HALT: hypoattenuating leaflet thickening; CMR: cardiac magnetic resonance; ECV: extracellular volume of distribution; NT-proBNP: Nterminal pro B-type natriuretic peptide; LV: left ventricular; LA: left atrial; MI: myocardial infarction; PCI: percutaneous coronary intervention; SPECT: single photon emission computed tomography

Received 17 November 2022; revised 29 November 2022; accepted 20 December 2022

## Echocardiography

The global Trivalve registry tested the use of right ventricle-pulmonary artery (RV-PA) coupling to optimize risk-stratification in 444 patients undergoing transcatheter tricuspid valve repair or replacement (TTVR) (1). At the multivariable Cox regression analysis, a TAPSE/PASP ratio  $< 0.406$  was independently associated with an increased risk of all-cause mortality [hazard ratio (HR): 0.57; 95% confidence interval (CI): 0.35–0.93;  $P = 0.023$ ]. TAPSE and PASP were not correlated, suggesting that RV-PA coupling may depict the cardiopulmonary haemodynamics better than the other two parameters alone, thus improving TTVR patient selection. Similar results were also observed from 570 patients with severe aortic stenosis (AS) included in the Placement of Aortic Transcatheter Valves Trial (PARTNER) 3 trial (2). Baseline RV-PA uncoupling (TAPSE/PASP  $\leq 0.55$ ) was independently associated (with E/E') with a two-fold increase in the primary composite endpoint at 2 years (all-cause mortality, stroke, rehospitalization). It maintained its prognostic value across multiple subgroups based on the treatment cohort, clinical factors, and echocardiographic parameters.

A recent study in 136 women with human epidermal growth factor 2 (HER2)-positive breast cancer identified a sequential algorithm to diagnose cancer therapy related cardiac dysfunction (CTRCD) [using cardiac magnetic resonance (CMR) as reference] by combining echocardiographic 3D left ventricular ejection fraction (LVEF), global longitudinal strain (GLS), and global circumferential strain (GCS) (3). This approach showed to provide a timely diagnosis of CTRCD during routine surveillance with greater accuracy than using the three measures individually or biomarkers and a probability of CTRCD of only 1.0% when results for all three tests were negative.

## Cardiac MRI

Chemotherapy is prolonging survival in systemic light-chain amyloidosis, but improved biomarkers of re-

sponse to treatment are warranted. Changes of extracellular volume fraction (ECV) (novel CMR biomarker) as a response to chemotherapy were evaluated in 176 patients diagnosis, 6, 12, and 24 months after starting chemotherapy (4). CMR regression ( $\geq 0.05$  decrease in ECV) was observed in 3% at 6 months, in 22% at 1 year, and 38% at 2 years. CMR progression ( $\geq 0.05$  increase in ECV) was seen in 32% at 6 months, in 22% at 1 year, and 14% at 2 years. CMR response at 6 months predicted death (progression HR 3.82; 95% CI: 1.95–7.49;  $P < 0.001$ ), even after adjusting for haematological response, N-terminal pro B-type natriuretic peptide (NT-proBNP), and GLS ( $P < 0.01$ ).

Garg *et al.* (5) challenged this notion that LV filling pressure cannot be estimated by CMR by investigating 835 patients with suspected heart failure. CMR-derived LV mass and left atrial size were associated with invasive pulmonary capillary wedge pressure (PCWP). The CMR-derived PCWP showed moderate correlation with right heart catheterization (HR = 0.55; 95% CI: 0.41–0.66,  $P < 0.0001$ ), good specificity (92%), and negative predictive value (78%), whilst filling pressure by echocardiography was concordant with invasive PCWP in only 25% of cases. CMR-derived PCWP was prognostic, associated with an increased risk of death (HR = 1.77,  $P = 0.001$ ), comparable to invasive PCWP ( $\geq 15$  mmHg).

Implantable cardioverter-defibrillators (ICDs) are recommended both in primary and secondary prevention, but improved patients' selection is warranted. In 700 patients undergoing CMR, visual myocardial fibrosis predicted sudden cardiac death (SCD) (HR: 26.3; 95% CI: 3.7–3337; negative predictive value:100%) but also arrhythmic endpoints (sub-distribution HR: 19.9; 95% CI: 6.4–61.9; negative predictive value:98.6%) (6). Quantitative grey zone fibrosis  $>17$  g was associated with highest risk of SCD (HR: 44.6; 95% CI: 6.12–5685) and the arrhythmic endpoint (sub-distribution HR: 30.3; 95% CI: 9.6–95.8). Adding visual and quantitative myocardial fibrosis led to reclassification of 39% patients for SCD and 50% for the arrhythmic endpoint, whilst LVEF was not predictive.

Reproduced from: European Heart Journal, Volume 44, Issue 7, 14 February 2023, Pages 554–556.  
<https://doi.org/10.1093/eurheartj/ehac812>

### Drug and Material Disclaimer:

The mention of trade names, commercial products organizations, and the inclusion of advertisements in the journal does not imply endorsement by the European Heart Journal, the editors, the editorial board, Oxford University Press or the organization to which the authors are affiliated. The editors and publishers have taken all reasonable precautions to verify drug names and doses, the results of experimental work and clinical findings published in the journal. The ultimate responsibility for the use and dosage of drugs mentioned in the journal and in interpretation of published material lies with the medical practitioner, and the editors and publisher cannot accept liability for damages arising from any error or omissions in the journal. Please inform the editors of any errors.

The opinions expressed in the European Heart Journal are those of the authors and contributors, and do not necessarily reflect those of the European Society of Cardiology, the editors, the editorial board, Oxford University Press or the organization to which the authors are affiliated.

Published on behalf of the European Society of Cardiology. © The Author(s) 2023.

For Permissions, please e-mail: [journals.permissions@oup.com](mailto:journals.permissions@oup.com)

All rights reserved; no part of this publication may be reproduced, stored in a retrieval system, or transmitted in any form or by any means, electronic, mechanical, photocopying, recording, or otherwise without the prior written permission of the Publishers.

## Cardiac computed tomography

Coronary computed tomography (CT) is changing the clinical pathway of patients with chest pain. The diagnostic imaging strategies for patients with stable chest pain and intermediate risk of artery disease trial (DISCHARGE) (7) investigated the effectiveness of cardiac CT vs. invasive coronary angiography (ICA) to reduce the frequency of major adverse cardiovascular events in patients with intermediate risk of coronary artery disease. In 3561 patients, the risk of major adverse cardiovascular events was similar in the CT vs. ICA (2.1% vs. 3%) (HR = 0.70; 95% CI: 0.46–1.07; P = 0.10), whilst the frequency of major procedure-related complications was lower with an initial CT vs. ICA strategy (0.5% vs. 1.9%) (HR = 0.26; 95% CI: 0.13–0.55).

Transcatheter aortic valve implantation (TAVI) is a widely used therapy for AS, but there are concerns on the occurrence of hypoattenuating leaflet thickening (HALT) and possible associated risk of reduced long-term prosthesis durability. In 565 patients undergoing cardiac CT for HALT screening at 30 days after TAVI implantation (8), HALT incidence was ~20% (9% anticoagulated patients), independently associated with a non-uniform prosthesis expansion (frame deformation, smaller neosinus volume) and also associated with a higher risk of 1-year adverse outcomes.

## Nuclear cardiology

Direct comparison of ischaemia testing is scarce. The prospective head to head comparison of coronary CT angiography, myocardial perfusion SPECT, PET and hybrid imaging for diagnosis of ischemic heart disease using fractional flow reserve as index for functional severity of functional stenosis-2 (PACIFIC-2) study (9) investigated the diagnostic performance of qualitative <sup>99m</sup>Tc-tetrofosmin single-photon emission CT (SPECT) vs. quantitative [15O]H<sub>2</sub>O positron emission tomography (PET) vs. qualitative CMR in patients with a prior myocardial infarction or percutaneous coronary intervention (PCI). When using as reference fractional flow reserve (FFR) ≤ 0.80, SPECT had a sensitivity 67%, specificity 65% vs. PET sensitivity 81%, specificity 65%. CMR's sensitivity was 66% and specificity 62%. PET diagnostic accuracy was 75% (68%–81%), not significantly different than SPECT (65%, 58%–72%, P = 0.03) or CMR (64%, 57%–72%, P = 0.052).

Consecutive patients undergoing transcatheter edge-to-edge repair (TEER) were screened for concomitant

cardiac amyloidosis using bone scintigraphy (10). The prevalence of CA was of 1 in 8 (significantly higher than reported in general referral for bone scintigraphy) and associated with disproportionately increased troponin values, thicker LV posterior wall, conduction abnormalities, and carpal tunnel syndrome. Despite CA may pose anatomical challenges, TEER was technically feasible with good magnetic resonance (MR) reduction. However, CA was associated with 2.5-fold higher risk for developing heart failure at mid-term follow-up after TEER.

## References

1. Brener MI, Lurz P, Hausleiter J, Rodés-Cabau J, Fam N, Kodali SK, et al. Right ventricular-pulmonary arterial coupling and afterload reserve in patients undergoing transcatheter tricuspid valve repair. *J Am Coll Cardiol* 2022;79:448–461. <https://doi.org/10.1016/j.jacc.2021.11.031>
2. Cahill TJ, Pibarot P, Yu X, Babaliaros V, Blanke P, Clavel MA, et al. Impact of right ventricle-pulmonary artery coupling on clinical outcomes in the PARTNER 3 trial. *JACC Cardiovasc Interv* 2022;15:1823–1833. <https://doi.org/10.1016/j.jcin.2022.07.005>
3. Smaeilzadeh M, Urzua Fresno CM, Somerset E, Shalmon T, Amir E, Fan CS, et al. A combined echocardiography approach for the diagnosis of cancer therapy-related cardiac dysfunction in women with early-stage breast cancer. *JAMA Cardiol* 2022;7:330–340. <https://doi.org/10.1001/jamacardio.2021.5881>
4. Martinez-Naharro A, Patel R, Kotecha T, Karia N, Ioannou A, Petrie A, et al. Cardiovascular magnetic resonance in light-chain amyloidosis to guide treatment. *Eur Heart J* 2022;43:4722–4735.
5. Garg P, Gosling R, Swoboda P, Jones R, Rothman A, Wild JM, et al. Cardiac magnetic resonance identifies raised left ventricular filling pressure: prognostic implications. *Eur Heart J* 2022;43:2511–2522. <https://doi.org/10.1093/eurheartj/ehac207>
6. Leyva F, Zegard A, Okafor O, Foley P, Umar F, Taylor RJ, et al. Myocardial fibrosis pre-dicts ventricular arrhythmias and sudden death after cardiac electronic device implantation. *J Am Coll Cardiol* 2022;79:665–678. <https://doi.org/10.1016/j.jacc.2021.11.050>
7. DISCHARGE Trial Group, Maurovich-Horvat P, Bossert M, Kofoed KF, Rieckmann N, Benedek T, et al. CT or invasive coronary angiography in stable chest pain. *N Engl J Med* 2022;386:1591–1602. <https://doi.org/10.1056/NEJMoa2200963>
8. Fukui M, Bapat VN, Garcia S, Dworak MW, Hashimoto G, Sato H, et al. Deformation of transcatheter aortic valve prostheses: implications for hypoattenuating leaflet thickening and clinical outcomes. *Circulation* 2022;146:480–493. <https://doi.org/10.1161/CIRCULATIONAHA.121.058339>
9. Driessen RS, van Diemen PA, Raijmakers PG, Knuuti J, Maaniitty T, Underwood SR, et al. Functional stress imaging to predict abnormal coronary fractional flow reserve: the PACIFIC 2 study. *Eur Heart J* 2022;43:3118–3128. <https://doi.org/10.1093/eurheartj/ehac286>
10. Donà C, Nitsche C, Koschutnik M, Heitzinger G, Mascherbauer K, Kammerlander AA, et al. Unveiling cardiac amyloidosis, its characteristics, and outcomes among patients with MR undergoing transcatheter edge-to-edge MV repair. *JACC Cardiovasc Interv* 2022;15:1748–1758. <https://doi.org/10.1016/j.jcin.2022.06.009>