

Rapid BRAF mutation detection in melanoma patients by immunohistochemistry

László FÜLÖP¹, Katalin GÖTZER¹, Erzsébet CSERNÁK¹,
Danyil Szergejevics KUZNYECOV¹ and Erika TÓTH^{1*}

¹National Institute of Oncology, Surgical and Molecular Pathology Center, Ráth Gy. u. 7-9, Budapest, H-1122 Hungary

*Corresponding Author; e-mail: erika66toth@gmail.com

Received: 11 March 2017 / Revised: 3 April 2017 / Accepted: 29 April 2017

Keywords: melanoma, BRAFVE1, immunohistochemistry

ABSTRACT

The V600E mutation is the most common (~90%) activating mutation of the BRAF gene. *BRAF* mutations have been frequently investigated in melanoma, colorectal cancer and papillary thyroid carcinoma. The importance of the detection of *BRAF* mutations has been rising by the routine use of Braf inhibitor therapy.

We evaluated the usefulness of the *BRAF* V600E mutation-specific monoclonal antibody (VE1) in metastatic melanoma patients. To confirm the results of immunohistochemistry (IHC), we used COBAS 4800 *BRAF* V600 mutation test and PCR amplification followed by Sanger sequencing. 36 of 105 patients have wild-type *BRAF* gene, 64 have V600E mutation and 5 of 105 have V600K mutation. Predicting the mutation only by IHC using VE1 antibody, all 58 positively scored specimen were V600E mutant. The V600K, the wild-type patients and 7 patients from the V600E mutant group scored as negative. Thus the specificity is 100% and the positive predictive value is 1 of the IHC method. After processing our data we could establish a cheaper diagnostic algorithm for rapid detection of *BRAF* mutation.

Introduction

Approximately 30 connections of the *BRAF* gene with human cancers have been identified. (1–3% *non-small-cell lung cancer* [1], 5% in *colorectal cancer papillary thyroid carcinoma* [2], 57% of Langerhans cell histiocytosis, 100% of *hairy cell leukaemia* [3], ameloblastoma, papillary *craniopharyngioma*, high grade gliomas in children [4], Metanephric adenoma [5, 6].

Hyperactivation of growth signal is usually a key factor in the development of these malignomas. Beside the mutations affecting the first steps of the signal (GFR and Ras) about 60% of the melanomas carrying an

activational mutation in the BRAF gene [6]. In 90% of the mutant cases, thymine is substituted with adenine at nucleotide 1799. This leads to valine (V) being substituted for by glutamate (E) at codon 600 (now referred to as V600E mutation).

In metastatic melanoma patients B-Raf inhibitor therapy is accepted in 2011 [7], and more selective inhibitors approved by FDA in 2013 [8]. Braf inhibitor treatment is suggested to be applied even beyond progression [7, 9].

Detection of the presence of BRAF mutation is the requirement of treatment and so in the given cases fast and reliable

mutation detection is very important. VE1 antibody recognises only V600E mutant Braf but not the wild form or other mutant variant [10]. Despite of the works demonstrating the relevance of the Braf V600E mutation specific antibody VE1 [11, 12, 13, 14, 15] it is still not accepted in the everyday routin.

Material and methods

Formalin fixed paraffin embedded (FFPE) blocks of 104 metastatic melanoma patients were analyzed. Anti-BRAFV600E staining was performed on the same blocks used for molecular analysis, using the VE1 mouse monoclonal antibody (Ventana Medical Systems, Roche, CN: 790-4855) diluted 1/100.

Results

We examined 104 patients with metastatic melanoma. In 50 cases analysis were made from the metastasis, and the rest of the cases were primary melanomas.

Table 1. Discordant cases in detail

ID Number	IHC	COBAS	Sanger	percentage of tumor cells	Origin	Probable cause of negativ IHC
10	negative	V600	V600E	80%	primer tumor	low positivity
31	negative	V600	V600E	90%	metastasis	low positivity
35	negative	V600	V600E	90%	primer tumor	low positivity
37	negative	V600	V600E	80%	metastasis	low positivity
40	negative	V600	V600E	70%	primer tumor	low positivity
41	negative	V600	V600K	80%	primer tumor	V600K
64	negative	V600	V600E	90%	metastasis	low positivity high staining noise
72	negative	V600	V600E	90%	metastasis	high staining noise
82	negative	V600	V600K	80%	primer tumor	V600K
83	negative	V600	V600K	80%	primer tumor	V600K
84	negative	V600	V600K	>5%	metastasis	V600K
85	negative	V600	V600K	80%	primer tumor	V600K
92	negative	V600	V600E	80%	metastasis	low positivity

We performed Braf IHC and COBAS 4800 V600 mutation test on all specimens, and Sanger sequencing on the discordant cases. Regarding these discordant cases COBAS and Sanger sequencing were 100% congruent. 48 patients were counted as

negative and 56 as positive with Braf IHC. All the positively scored patients turned out to be BRAF mutants with COBAS. Five specimens of the 48 IHC negatively scored group had V600K mutation and 8 happened to be false negative (Figure 1). Detailed

Despite of the few analytical difficulties here we show a diagnostic procedure in wich immunohistochemistry has a reliable role. The importance of the VE1 antibody is highlighted by the faster diagnosis and lower procedure costs.

BRAF mutation analysis

Cobas® 4800 BRAF V600 Mutation Test was performed according to manufacturer instructions (Supplementary material 1).

In house method were also used. PCR amplification with mutation specific primer followed by Sanger sequencing was performed as described before [16].

information of the discordant cases are shown in Table 1. Representative pictures are shown in Figure 2. Age of the BRAF mutation

carrying patients were significantly lower (average: 58.42 years and 66.13 years resp., $p=0.005$).

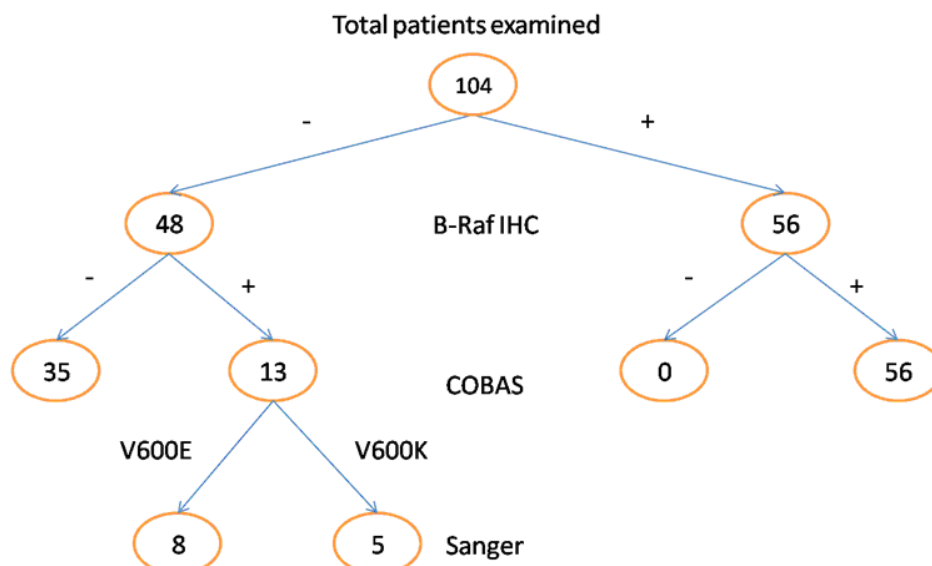


Fig. 1. Analysis sequence. IHC: immunohistochemistry

Discussions

In this study we further asserted the role of Braf VE1 immunohistochemistry in the diagnosis of BRAF mutations. Foremost we verified BRAF mutation status by COBAS or in house method. Discordant cases were

analysed by Sanger sequencing, revealing V600K mutations in the majority of false negative cases. Since intra-observer variability was negligible the false negative cases were re-analysed.

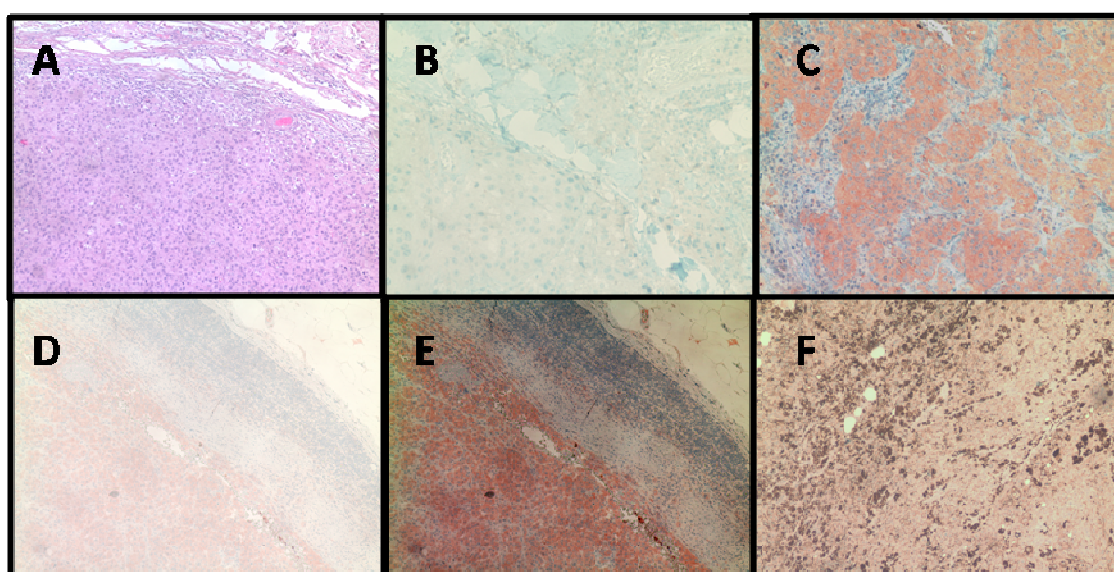


Fig. 2. Representative pictures. A: standard hematoxylin-Eosin staining. B: True negative (negative IHC, wild type). C: True positive (positive IHC, V600 mutant). D: False negative (negative IHC, V600K mutant) E: False negative after image processing. F: Highly pigmented area, counted as negative.

This showed that true negative cases were reliably negative, but false negative cases had usually problematic IHC due to the highly pigmented areas, high background

Braf VE1 IHC is an easy method that doesn't require DNA isolation and can be performed during short time. Positive immuno-histochemistry means the presence of BRAF mutation [11, 12, 13]. But we cannot rely on negative or uncertain Braf VE1 IHC, because of the V600K mutants and regarding the therapeutic consequences we shall be completely sure about the mutation.

noise or very low positivity. These can highlight potential positive cases but still recommended to count as negative and perform DNA tests.

So we strongly suggest BRAFVE1 immunohisto-chemistry as a primary screening method and to evaluate every negative or uncertain cases by further molecular methods.

Pre-screening melanoma with Braf VE1 IHC can shorten the time for the appropriate therapy in the majority of cases, due to the excellent positive predictive value.

References

1. Sasaki H, Maekawa M, Tatematsu T, et al. (2015) Increased BRAF copy number in lung adenocarcinoma. **Oncol Lett** 9:709–712. doi: 10.3892/ol.2014.2719
2. Lu J, Gao J, Zhang J, et al. (2015) Association between BRAF V600E mutation and regional lymph node metastasis in papillary thyroid carcinoma. **Int J Clin Exp Pathol** 8:793–9.
3. Arora N, Nair S, Pai R, et al. V-raf murine sarcoma viral oncogene homolog B (BRAF) mutations in hairy cell leukaemia. **Indian J Pathol Microbiol** 58:62–5. doi: 10.4103/0377-4929.151190
4. Mistry M, Zhukova N, Merico D, et al. (2015) BRAF Mutation and CDKN2A Deletion Define a Clinically Distinct Subgroup of Childhood Secondary High-Grade Glioma. **J Clin Oncol** 33:1015–22. doi: 10.1200/JCO.2014.58.3922
5. Udager AM, Pan J, Magers MJ, et al. (2015) Molecular and Immunohistochemical Characterization Reveals Novel BRAF Mutations in Metanephric Adenoma. **Am J Surg Pathol** 39:549–57. doi: 10.1097/PAS.0000000000000377
6. Davies H, Bignell GR, Cox C, et al. (2002) Mutations of the BRAF gene in human cancer. **Nature** 417:949–54. doi: 10.1038/nature00766
7. Chapman PB, Hauschild A, Robert C, et al. (2011) Improved survival with vemurafenib in melanoma with BRAF V600E mutation. **N Engl J Med** 364:2507–16. doi: 10.1056/NEJMoa1103782
8. Thompson CA (2013) FDA approves two new drugs against advanced melanoma. **Am J Health Syst Pharm** 70:1094. doi: 10.2146/news130045
9. Scholtens A, Geukes Foppen MH, Blank CU, et al. (2015) Vemurafenib for BRAF V600 mutated advanced melanoma: results of treatment beyond progression. **Eur J Cancer** 51:642–52. doi: 10.1016/j.ejca.2015.01.009
10. Capper D, Preusser M, Habel A, et al. (2011) Assessment of BRAF V600E mutation status by immunohistochemistry with a mutation-specific monoclonal antibody. **Acta Neuropathol** 122:11–9. doi: 10.1007/s00401-011-0841-z
11. Liu H, Li Z, Wang Y, et al. (2014) Immunohistochemical detection of the BRAF V600E mutation in melanoma patients with monoclonal antibody VE1. **Pathol Int** 64:601–6. doi: 10.1111/pin.12215
12. Løes IM, Immervoll H, Angelsen J-H, et al. (2014) Performance comparison of three BRAF V600E detection methods in malignant

- melanoma and colorectal cancer specimens.
Tumor Biol 36:1003–1013.
doi: 10.1007/s13277-014-2711-5
13. Pearlstein M V, Zedek DC, Ollila DW, et al. (2014) Validation of the VE1 immunostain for the BRAF V600E mutation in melanoma. **J Cutan Pathol** 41:724–32.
doi: 10.1111/cup.12364
14. Tetzlaff MT, Pattanaprichakul P, Wargo J, et al. (2015) Utility of BRAF V600E Immunohistochemistry Expression Pattern as a Surrogate of BRAF Mutation Status in 154 Patients with Advanced Melanoma. **Hum Pathol** 46:1101–1110.
doi: 10.1016/j.humpath.2015.04.012
15. Manfredi L, Meyer N, Tournier E, et al. (2015) Highly Concordant Results Between Immunohistochemistry and Molecular Testing of Mutated V600E BRAF in Primary and Metastatic Melanoma. **Acta Derm Venereol.**
doi: 10.2340/00015555-2326
16. Sanger F, Nicklen S, Coulson AR (1977) DNA sequencing with chain-terminating inhibitors. **Proc Natl Acad Sci U S A** 74:5463–7.