

A call for observations of birds with sublingual oral fistulas in central and eastern Europe, and beyond

S. James REYNOLDS^{1,2}



Received: October 21, 2021 – Revised: October 24, 2021 – Accepted: October 26, 2021

Reynolds, S. J. 2021. A call for observations of birds with sublingual oral fistulas in central and eastern Europe, and beyond. – Ornis Hungarica 29(2): 188–194. DOI: 10.2478/orhu-2021-0030

Abstract Birds with major physical abnormalities do not live for extended periods and, therefore, are rarely observed in the wild. This is particularly the case for birds with defects in their feeding apparatus that succumb to mortality rapidly through precipitous declines in their foraging efficiency and body condition. Sublingual oral fistulas are such an abnormality and involve the development of an opening (or fistula) in the floor of the oral cavity through which the tongue extends, resulting in its permanent exclusion from the mouth. The tongue dehydrates and dies. First described in the 2000s in Stitchbirds (*Notiomystis cincta*) in New Zealand, it has rarely been reported in other species. However, following our recent discovery of two seabird species on Ascension Island in the South Atlantic displaying oral fistulas, in 2016 I launched a citizen science research project requesting reports of birds with the condition in the world's avifauna. To date, I have received 188 reports of birds of 82 different species with many contributed from western Europe. However, with only one report from central and eastern Europe, I am now requesting the assistance of birders in the region and in other parts of the world to contribute to this ongoing research project.

Keywords: abnormality, body condition, defect, foraging efficiency, predation and starvation risks

Összefoglalás A komoly fizikai elváltozásokat szenvedett madarak élettartama jelentősen csökken, ezért ilyen elváltozások ritkán figyelhetők meg a vadon élő egyedek körében. Ez különösen igaz olyan madaraknál, ahol táplálkozást nehezítő hiányosságok jelennek meg, ezért az elhullás mértéke a csökkent táplálkozási hatékonyság és a gyorsan romló egészségi állapot következtében megnő. A nyelv alatt megjelenő szájtajéki sipolyok (oral fistulas) épp ilyen rendellenességek, amelyek egy nyílást képeznek az alsó csőrkáván, amelyen keresztül a nyelv kizáródik a szájüregből. Ennek következtében a nyelv kiszárad és elhal. A jelenséget először a 2000-es években írták le új-zélandi őrvös maorimadaraknál (*Notiomystis cincta*), míg más fajoknál ritkán jelentették. Azonban a dél-atlanti Ascension-szigeten további két madárfajnál figyelték meg a jelenséget, amit követően 2016-ban elindítottam azt a citizen science programot, amelynek keretében adatokat gyűjtök az ismertett rendellenességről, a világ teljes madárfaunájára vonatkozóan. Eddig 192 bejelentés érkezett 82 madárfajról, főként Nyugat-Európából. Mivel csupán egyetlen adat származik Európa középső és keleti országaiból, ezért ösztönözni szeretném a régió és a világ más területeinek madarászait, hogy megfigyeléseikkel járuljanak hozzá ehhez a tudományos munkához.

Kulcsszavak: rendellenesség, egészségi állapot, hiányosság, táplálkozási hatékonyság, zsákmányolás és éhezés, kockázatok

¹ Centre for Ornithology, School of Biosciences, College of Life & Environmental Sciences, University of Birmingham, Edgbaston, Birmingham B15 2TT, UK

² Army Ornithological Society (AOS), c/o Prince Consorts Library, Knollys Road, South Camp, Aldershot, Hampshire GU11 1PS, UK
e-mail: J.Reynolds.2@bham.ac.uk

The physiological requirements of powered flight mean that compared with other classes of higher vertebrates, birds are heavily impacted by major physical abnormalities. Most of the world's 10,912 extant bird species (www.worldbirdnames.org) are volant and, therefore, most cannot carry excess (i.e. surplus to requirements) nutritional and energetic reserves because of the need to minimise body mass for effective and efficient flight (Ellington 1991). Excess body mass negatively impacts the ability of birds to evade predators in response to perceived mass-dependent predation risk (e.g. Witter *et al.* 1994, Gentle & Gosler 2001). Similarly, reduced body mass can lower survival of birds through a different (non-predatory) mechanism, namely that of starvation risk (Houston & McNamara 1993). Therefore, this delicately balanced trade-off between predation and starvation risks results in body mass dynamics in most bird species that are especially sensitive to any physical abnormalities that negatively influence their body condition (Brown 1996). Assessment of body condition is traditionally made by calculating mass per unit (structural) length in birds (Rising & Somers 1989), a derived metric that quantifies somatic reserves scaled by the overall body size of a bird. Although major physical abnormalities are seen in free-living birds (e.g. Sutton 1973, Durell *et al.* 1996), they are rare, perhaps because usually the body condition of birds declines rapidly as a result of deterioration in their foraging abilities (e.g. Sharp & Neill 1979, Murza *et al.* 2000). Precipitous declines in body condition inevitably



Figure 1. Two Western Jackdaws (*Corvus monedula*) in Woolacombe, North Devon, UK, where they were feeding at the edge of a woodland on the 4th of April 2018. The bird on the right displays an oral fistula where the tongue extends through an opening (fistula) in the floor of the bird's oral cavity from where it is permanently excluded (photo: Carl Bovis)

1. ábra Erdőszélen táplálkozó csókák (*Corvus monedula*) Woolacombe, North Devon, UK területén 2018. április 8-án. A jobb oldali madáron jól látható az a rendellenesség – szájtejéki sipoly (oral fistula) –, ami elsősorban az alsó csőrkvát érinti, azon egy nyílást képezve, melyen keresztül a madár nyelve a csőrön kívülre záródik (Fotó: Carl Bovis)

result in mortality of birds, sometimes from increased susceptibility to predation (Temple 1987), rather than from starvation *per se*.

Body condition of birds declines dramatically as a result of abnormalities of their feeding apparatus (i.e. bill, tongue, oropharynx) (e.g. Clayton *et al.* 1999, Van Hemert *et al.* 2012). Given the rarity of free-living birds exhibiting such major abnormalities, we were surprised to observe a number of Sooty Terns (*Onychoprion fuscatus*) (Reynolds *et al.* 2009) and a Masked Booby (*Sula dactylatra*) (Hughes *et al.* 2013) with sublingual oral fistulas (hereafter referred to as ‘oral fistulas’) on Ascension Island in the South Atlantic. This is an abnormality of the oropharynx of birds in which an opening (or fistula) develops in the floor

Table 1. Details of species observed with oral fistulas and recorded in the research project database (as of the 23rd of October 2021). Taxonomy follows del Hoyo (2020)

1. táblázat A kutatási adatbázisban 2021. október 23-ig rögzített, szájtájéki sipollyal (oral fistula) megfigyelt madárfajok és rendszertani besorolásuk (del Hoyo 2020)

Order	Family	Number of:	
		species	oral fistulas
Galliformes	Megapodiidae	1	1
Anseriformes	Anatidae	7	9
Podicipediformes	Podicipedidae	2	2
Gruiformes	Rallidae	1	1
	Gruidae	1	2
Gaviiformes	Gaviidae	2	3
Sphenisciformes	Spheniscidae	2	2
Ciconiiformes	Ardeidae	9	16
	Pelecanidae	1	1
Suliformes	Sulidae	1	1
	Phalacrocoracidae	2	2
Charadriiformes	Scolopacidae	5	5
	Laridae	31	111
	Stercorariidae	1	1
Accipitriformes	Accipitridae	2	5
Falconiformes	Falconidae	1	1
Passeriformes	Tyrannidae	1	1
	Meliphagidae	2	2
	Corvidae	1	2
	Notiomystidae	1	12
	Sylviidae	1	1
	Certhiidae	1	1
	Mimidae	1	1
	Turdidae	2	2
	Muscicapidae	3	3

of the oral cavity (*Figure 1*). As the condition progresses, the tongue of the bird protrudes through the fistula where eventually it remains permanently excluded from the oral cavity, drying and becoming necrotic with increasing exposure. We were not the first to observe and describe this condition in free-living birds because it had been seen initially in Stitchbirds (or ‘hihi’) (*Notiomystis cincta*) on Kapiti Island in New Zealand in 1992. The condition in free-living birds was first described in Stitchbirds in the scientific literature by Castro and Taylor (2001).

While the progression of oral fistulas in birds is well described in Stitchbirds (Low *et al.* 2007), its aetiology remains a mystery in this species and others. Since the publication of observations of oral fistulas in a Masked Booby, and in Sooty Terns and Stitchbirds, the condition has been reported in only a few other species to date: Audouin’s Gull (*Larus audouinii*) (Greño *et al.* 2017), Franklin’s Gull (*Larus pipixcan*) (Rintoul & Reynolds 2019), Griffon Vulture (*Gyps fulvus*) (Camiña & Guerrero 2013), and Swinhoe’s Snipe (*Gallinago megala*) (Melville *et al.* 2019).

As a result of limited knowledge about the condition in the world’s free-living birds, in May 2016 I launched a citizen science research project requesting global observations of birds with the condition. Its objectives are to document the occurrence of oral fistulas in temporal, spatial, phylogenetic and foraging niche ‘spaces’. Through this global survey, it is hoped to understand: how long historically the condition has impacted birds; where in the world birds are most heavily impacted by the condition; whether the condition ‘targets’ particular avian taxa; and, through considering phylogenetic relationships between species, whether some taxa are more predisposed to developing the condition than others by virtue of sharing ensembles of foraging traits. The research project ultimately sets out to determine: which species might be expected to develop the condition in the future, thereby allowing us to target surveillance efforts in the field to detect its occurrence rapidly; at what life stage(s) birds develop the condition so we can target our field surveillance efforts; the chronic impacts of the condition on birds living with the condition; and the causes of the condition so that we can prevent it from occurring in birds in the future.

It is particularly important to increase the number of observations of birds with the condition because, along with other researchers connected to this project, I plan to carry out statistical analysis on data that especially uses phylogenetic comparative methods (where possible) to predict the occurrence of oral fistulas in birds.

Details of my research project can be found at: <https://www.birmingham.ac.uk/research/activity/ornithology/oral-fistula-project.aspx>. This webpage contains a link to a reporting form that I hope contributors will download and complete before sending it to me via e-mail (J.Reynolds.2@bham.ac.uk), together with accompanying high resolution digital images of birds in the field with oral fistulas. If potential contributors are in any doubt about whether the bird observed has an oral fistula, please send to me an e-mail to which images of the bird are attached so that I can view them and confirm that it has an oral fistula. Following confirmation, I am requesting that contributors complete the reporting form and send it to me for each observation of a bird with an oral fistula, whether it be a novel sighting or a re-sighting.

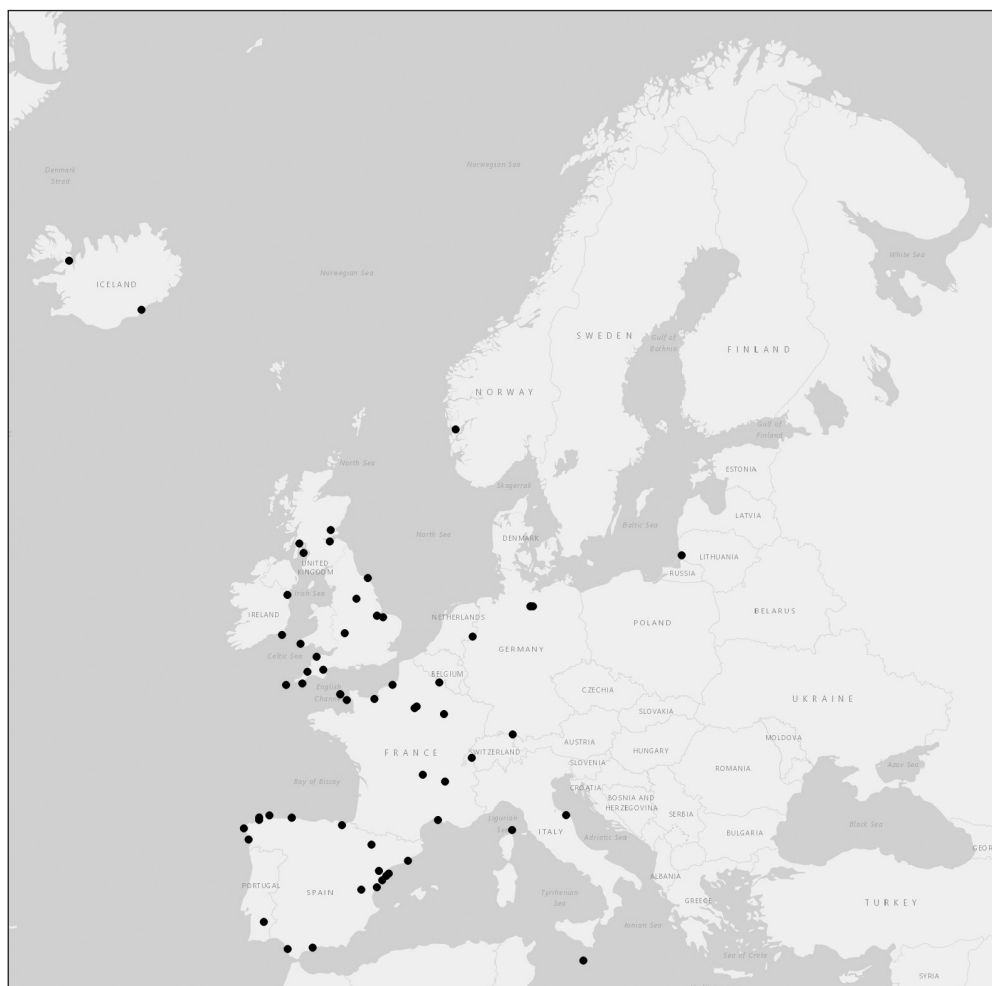


Figure 2. The European distribution of free-living birds with oral fistulas observed between the 3rd of October 2005 and the 27th September 2021

2. ábra Európa térképe olyan vadon élő madarak előfordulásának feltüntetésével, amelyeket a szövegben részletezett rendellenességgel (oral fistula) figyeltek meg 2005. október 7. és 2021. szeptember 27. között

I am appealing to readers (irrespective of whether they be birdwatchers, ornithologists, photographers or ringers) for help in collating records of free-living birds with oral fistulas in eastern Europe and also worldwide. To date, I have received 188 novel records of birds of 82 different species (Table 1) but the project database contains only one record of a bird with an oral fistula from eastern Europe (Figure 2), a White-tailed Eagle (*Haliaeetus albicilla*) in Lithuania observed in January in 2016. As can be seen in Figure 2, observations of birds are concentrated in western Europe with clusters of birds appearing in north-eastern and eastern Spain, and south-western England, including the Western Jackdaw (*Corvus monedula*) photographed in Figure 1. The scarcity of observations from eastern Europe is

notable; rather than it being indicative of an absence of birds with the condition, however, I conclude that readers who have detected oral fistulas in birds when watching, photographing and/or ringing them are unaware of my research project and that it is ongoing. Therefore, I urge readers please to consider connecting with me in the future if birds with oral fistulas are observed or if notes and images of such birds in some archived field notebooks are available. This would be a great opportunity for me to extend this project to eastern Europe and to other parts of the world.

Acknowledgements

I would like to thank numerous citizen scientists from many countries for contributing sightings of birds with oral fistulas to my research project to date. I thank Jenő Nagy for inviting me to submit this article to the journal.

References

- Brown, M. E. 1996. Assessing Body Condition in Birds. – In: Nolan, V. & Ketterson, E. D. (eds.) *Current Ornithology*, Vol. 13. – Springer, Boston, MA, USA. DOI: 10.1007/978-1-4615-5881-1_3.
- Camiña, A. & Guerrero, L. M. 2013. An Eurasian Griffon *Gyps fulvus* disadvantaged for feeding. – *Vulture News* 64: 66–68.
- Castro, I. & Taylor, J. 2001. Survival and reproductive success of Stitchbird (hihi, *Notiomystis cincta*) suffering from a bill abnormality (oral fistula). – *Notornis* 48: 241–244.
- Clayton, D. H., Lee, P. L. M., Tompkins, D. M. & Brodie, E. D. 1999. Reciprocal natural selection on host-parasite phenotypes. – *The American Naturalist* 154: 261–270. DOI: 10.1086/303237.
- del Hoyo, J. (ed.) 2020. *All the Birds of the World*. – Lynx Edicions, Barcelona
- Durell, S. E. A. Le V. dit, Ormerod, S. J. & Dare, P. J. 1996. Differences in population structure between two Oystercatcher *Haematopus ostralegus* roosts on the Burry Inlet, South Wales. – *Ardea* 84A: 383–388.
- Ellington, C. P. 1991. Limitations on animal flight performance. – *Journal of Experimental Biology* 160: 71–91. DOI: 10.1242/jeb.160.1.71.
- Gentle, L. K. & Gosler, A. G. 2001. Fat reserves and perceived predation risk in the Great Tit, *Parus major*. – *Proceedings of the Royal Society B: Biological Sciences* 268: 487–491. DOI: 10.1098/rspb.2000.1405.
- Greño, J. L., Bertolero, A., Bort, J., Howard, R., Luque, E., Oro, D. & Sánchez, A. 2017. Audouin's Gulls *Larus audouinii* affected by sublingual fistulas. – *Ardeola* 64: 67–73. DOI: 10.13157/arta.64.1.2017.sct.
- Houston, A. I. & McNamara, J. M. 1993. A theoretical investigation of the fat reserves and mortality levels of small birds in winter. – *Ornis Scandinavica* 24: 205–219. DOI: 10.2307/3676736.
- Hughes, B. J., Martin, G. R., Wearn, C. P. & Reynolds, S. J. 2013. Sublingual fistula in a Masked Booby (*Sula dactylatra*) and possible role of ectoparasites in its etiology. – *Journal of Wildlife Diseases* 49: 455–457. DOI: 10.7589/2012-03-085.
- Low, M., Alley, M. R. & Minot, E. 2007. Sub-lingual oral fistulas in free-living Stitchbirds (*Notiomystis cincta*). – *Avian Pathology* 36: 101–107. DOI: 10.1080/03079450601142570.
- Melville, D. S., Davaasuren, B. & Erdenechimeg, T. 2019. First sub-lingual oral fistula reported in a Swinhoe's Snipe *Gallinago megala*. – *Wader Study* 126: 64–66. DOI: 10.18194/ws.00133.
- Murza, G. L., Bortolotti, G. R. & Dawson, R. D. 2000. Handicapped American Kestrels: Needy or prudent foragers? – *Journal of Raptor Research* 34: 137–142.
- Reynolds, S. J., Martin, G. R., Wearn, C. P. & Hughes, B. J. 2009. Sub-lingual oral fistulas in Sooty Terns (*Onychoprion fuscatus*). – *Journal of Ornithology* 150: 691–696. DOI: 10.1007/s10336-009-0377-3.
- Rintoul, D. A. & Reynolds, S. J. 2019. Sublingual oral fistula in a Franklin's Gull (*Leucophaeus pipixcan*). – *Kansas Ornithological Society Bulletin* 70: 53–56.

- Rising, J. D. & Somers, K. M. 1989. The measurement of overall body size in birds. – *The Auk* 106: 666–674. DOI: 10.1093/auk/106.4.666.
- Sharp, M. S. & Neill, R. L. 1979. Physical deformities in a population of wintering Blackbirds. – *The Condor* 81: 427–430. DOI: 10.2307/1366976.
- Sutton, R. R. 1973. Harrier without feet. – *Notornis* 20: 74.
- Temple, S. A. 1987. Do predators always capture substandard individuals disproportionately from prey populations? – *Ecology* 68: 669–674. DOI: 10.2307/1938472.
- Van Hemert, C., Handel, C. M. & O'Brien, D. M. 2012. Stable isotopes identify dietary changes associated with beak deformities in Black-capped Chickadees (*Poecile atricapillus*). – *The Auk* 129: 460–466. DOI: 10.1525/auk.2010.10111.
- Witter, M. S., Cuthill, I. C. & Bonser, R. H. C. 1994. Experimental investigations of mass-dependent predation risk in the European Starling, *Sturnus vulgaris*. – *Animal Behaviour* 48: 201–222. DOI: 10.1006/anbe.1994.1227.



FORM FOR REPORTING ORAL FISTULAS IN BIRDS

(NOTE: Please complete a separate form for each bird observed with condition)

Record # (for use by SJR) (please ignore)	
Date	
Time	
Species' name (common, scientific or both)	
Was the bird alive (A) or dead (D) ?	
Age of bird ([A] adult or [C] chick)	
Location (GPS coordinates, county or region, country etc.)	
Where was the bird seen (e.g. woodland, farmland, urban, landfill, harbour, river, lake, canal, on the coast, at-sea etc.)?	
Behaviour of bird (e.g. feeding, resting, incubating or brooding, fighting with another etc.)	
Was the bird ringed? (Y/N) (If 'Y' please also supply the ring number if you have it)	
Is this the only time that you have seen this bird? (Y/N) (If 'N' please provide further details including how many times in total you have seen it and at which sighting you first noted the oral fistula)	
Was the protruding tongue extended and coloured OR constricted, dry and discoloured?	
Did you photograph the bird? (Y/N) (If 'Y' please send me the photograph(s) via e-mail. You will retain copyright and I will seek permission from you if I would like to use for an output)	
Were you ringing/banding, birdwatching, on a walk, photographing birds or something else when you made the observation?	
Your name and contact details	
Any other relevant information?	

NOTE: Please return to Dr Jim Reynolds via e-mail: J.Reynolds.2@bham.ac.uk