

Radiodiagnostic method for studying the dynamics of *Anguillicola crassus* (Nematoda: Dracunculoidea) infection and pathological status of the swimbladder in Lake Balaton eels

Csaba Székely*, Kálmán Molnár, Orsolya Z. Rác

Veterinary Medical Research Institute, Hungarian Academy of Sciences, 1143 Budapest, Hungária krt. 21, Hungary

ABSTRACT: Swimbladder changes resulting from *Anguillicola crassus* infection of the European eel *Anguilla anguilla* have been the subject of several studies reported in the literature. These investigations, however, studied exclusively the status of infection at a given point in time and did not deal with changes in swimbladder infection in eels suffering from anguillicolosis over a period of time. In this study, *A. crassus*-induced pathological changes were monitored in 78 eels naturally infected in Lake Balaton and subsequently kept in the laboratory, thus excluding the possibility of further infection. During the 3 mo study, the status of the swimbladder was checked by radiographic examination on 4 occasions. At the end of the study the eels were dissected and the gross pathological changes in the swimbladders were compared with the radiographic findings. As compared to their starting condition, by the end of the study the pathological status of the swimbladder had deteriorated in 55% and remained the same in 37% of the cases. Tendency to improvement (1%) and variable findings (7%) were recorded in a low percentage of cases only. With the help of the radiographs presented, the dynamics of *A. crassus* infection and of changes in the swimbladder of individual eel specimens can be monitored easily.

KEY WORDS: European eel · *Anguillicola crassus* · Swimbladder infection · Pathological changes · Repeated conventional X-ray · Temporal effect · Dynamics of infection in individuals

—Resale or republication not permitted without written consent of the publisher—

INTRODUCTION

The eel is a valuable fish species both for fisheries and pisciculture, but recently its population has started to diminish to an alarming extent (Dekker 2003). Therefore, numerous wide-ranging programmes, including a project supported by the European Union, EELREP Q5RS-2001-01836 (2001), have been launched to save this fish species, protect its naturally reproducing stock and possibly develop a method for its artificial reproduction. One of the principal objectives of the programme is to determine the influence of certain pathogens, among them *Anguillicola crassus*, on the success of spawning. The swimbladder nematode *A. crassus*, the original host of which was the Japanese eel *Anguilla japonica*, causes much more intensive infection in the European eel *A. anguilla*

stocks than in its original host (Egusa 1979). Anguillicolosis has become an important disease well studied in all of its aspects (Moravec 1992, Nagasawa et al. 1994, Würtz & Taraschewski 2000, Kirk 2003).

The eel swimbladder, which is a pressure-balancing organ which might also have an influence on the oxygen metabolism, may play an important role in the migration of eels to their spawning area in the Sargasso Sea. The correlation between infection and the viability of eels was demonstrated by the experiment of Sprengel & Luchtenberg (1991), according to which the swimming speed of infected fish decreased in proportion to the severity of infection. A study by Barus & Prokes (1996) indicated that infection also affected the length-weight relationship of the fish. Molnár (1993) pointed out that the natural resistance of eels decreased as the number of worms colonising the swim-

*Email: szekely@vmri.hu

bladder increased as did the severity of swimbladder wall thickening which these caused. They observed further that more severely affected eels died in deoxygenated water. In the framework of the above-mentioned EU project, studies were carried out, among other things, on the effect of anguillicolosis on the swimming performance and pressure tolerance of eels (Vettier et al. 2003). Classification of the *Anguillicola crassus* infection of eels used for swimming performance and pressure tolerance experiments based on the severity of swimbladder changes was made using the radiodiagnostic method of Beregi et al. (1998). Dissection of the fish used to be the only means of diagnosing swimbladder changes, but Beregi et al. (1998, 2001) have established that radiodiagnostic methods are suitable for monitoring swimbladder changes and provide reliable data on the number of nematodes, the air content and, indirectly, on the wall thickness of the swimbladder. The wide-ranging potential for using radiodiagnostic methods in fish medicine has also been suggested by the studies of Böttcher & Böttcher (2000, 2003a,b). Conventional X-ray methods and X-ray computerised tomography have recently been compared by Székely et al. (2004) to determine their value in the diagnosis of swimbladder infection in eels.

The objective of this study was to determine whether the severity of swimbladder infection or the pathological status of the swimbladder change substantially during a long-term swimming speed or pressure tolerance experiment. To answer this question, the dynamics of the swimbladder status of individually marked eels were studied by a radiodiagnostic method at monthly intervals over a 3 mo period.

MATERIALS AND METHODS

Anguilla anguilla used in this study were 41 to 65 cm long and at least 13 yr old. They were collected from Lake Balaton, in the region of Tihany, by electrofishery on 1 September 2003. The eels examined were specimens older than 13 yr, as there is no natural migration into the lake, and the introduction of eels had not been carried out since 1991. After collection, the eels were transported to the laboratory in oxygen-filled foil bags, and maintained without feeding in concrete basins supplied with flow-through water throughout the study. Water temperature in the basins was initially 16°C; it was subsequently gradually decreased to 10°C and then again raised to 16°C. A total of 78 eels were used in the experiment. The fish were individually marked by injecting Trovan® tags under the skin of the back in the part behind the head, about 0.5 cm deep. The tags were read with an AEG ID ARE H5-ISO

apparatus. After a 10 d adaptation period following collection, the eels were X-rayed using the method of Beregi et al. (1998, 2001) and Székely et al. (2004). The examination was repeated 3 times (4, 8 and 12 wk after the first X-ray examination). For the period of the radiographic examinations, the eels were anaesthetised by adding a few drops of essential oil of cloves (*Syzygium aromaticum*) to the water. The eel specimens were identified at every examination on the basis of the implanted tags. Of the 78 eels, 2 died soon after the first X-ray examination. These fish were excluded from further study. Seven days after the last X-ray examination 38 eels were euthanised, then killed, and the remaining 38 eels were dissected during the subsequent 2 mo (1 to 5 specimens at a time). The eels were killed by decapitation after previous narcosis with essential oil of cloves. After opening the abdominal cavity, the swimbladder was removed together with the pneumatic duct, and carefully cleared from all adhering tissues, if any were present. The swimbladders were photographed with an Olympus C-120 type digital camera both before and after incision. Subsequently, the entire mass of the unopened swimbladder as well as the total mass of worms and worm debris located in the swimbladder lumen were determined. The number of pre-adult and adult worms in each swimbladder and the thickness of the swimbladder wall were determined under a stereomicroscope. After the first X-ray examination, the eels were classified into 3 categories based upon the status of their swimbladder: eels with severe, moderate or mild swimbladder changes were distinguished.

The above categories were determined according to the following criteria. The group of eels with mild swimbladder changes included individuals with a swimbladder showing a full radiographic shadow or those in which the occurrence of only smaller worms was suspected. Eels with moderate swimbladder changes were those having a well-demarcated swimbladder, showing the outlines of larger worms or covered areas in some places. On the basis of the first X-ray examination, those eels were classified as having severe swimbladder changes when the swimbladder did not show any radiographic shadow or when a radiographic shadow (air content) could be discovered only in a small part of the swimbladder.

On the basis of further radiographs and the dissection findings, the above groups were divided into subgroups, depending on whether the condition of the swimbladder deteriorated, remained unchanged, or improved during the period of study (12 wk). The radiographs taken of each fish and the pictures of the swimbladders taken after dissection were arranged on plates. From these, the radiographs and swimbladder pictures of 9 representative eels are shown.

Table 1. *Anguillicola crassus* infecting *Anguilla anguilla*. Changes in the swimbladder (SB) status of 76 Lake Balaton eel specimens over a 12 wk period on the basis of X-ray examination methods

SB status at first X-ray	SB status at fourth X-ray (12 wk after first X-ray)			
	Same	Worse	Better	Variable
Severe 8	2	5	1	0
Moderate 31	8	19	0	4
Mild 37	18	18	0	1
Total 76	28	42	1	5

RESULTS

On the basis of the first radiograph, 8 out of the 76 individuals surviving until the end of the study were assigned to the category of eels with severe swimbladder changes, 31 were regarded as having moderate swimbladder changes and 37 proved to have relatively mild infection. (As a consequence of *Anguillicola crassus* infection persisting in the Lake Balaton eel population, eels with an intact swimbladder, free from pathological changes can no longer be found in that lake).

The findings of the 3 further X-ray examinations and the dissection results indicated that in 37% of the cases the swimbladder status found at the first radiography had not changed markedly by the completion of the study, i.e. by the end of the third month. In the majority of cases (55%) the status of the swimbladder deteriorated. As compared to the diagnosis established at the first X-ray examination, a tendency towards improvement was found in only 1% of the eels, and a variable condition was diagnosed in 7% of the cases (Table 1).

In some of the eels diagnosed as having mild swimbladder changes at the first X-ray examination, the air-filled swimbladder also reflected the original condition at the time of dissection (Fig. 1), and no worms could be found in it. In other individuals, the outlines of growing worms gradually became more and more distinct in the swimbladder in the course of the repeated X-ray examinations, and one or several worms were found to be present in it at the time of dissection (Fig. 2). Other individuals which originally had an air-filled swimbladder exhibited gradual reduction of swimbladder air content at the subsequent radiographic examinations, and at dissection, the swimbladder was practically devoid of air and contained large numbers of worms (Fig. 3).

Figs. 1–9. (a) First X-ray examination; (b) second X-ray taken 4 wk after first X-ray; (c) third X-ray taken 8 wk after first X-ray; (d) fourth X-ray taken 12 wk after first X-ray; (e) unopened swimbladder of eel killed after fourth X-ray; (f) opened swimbladder

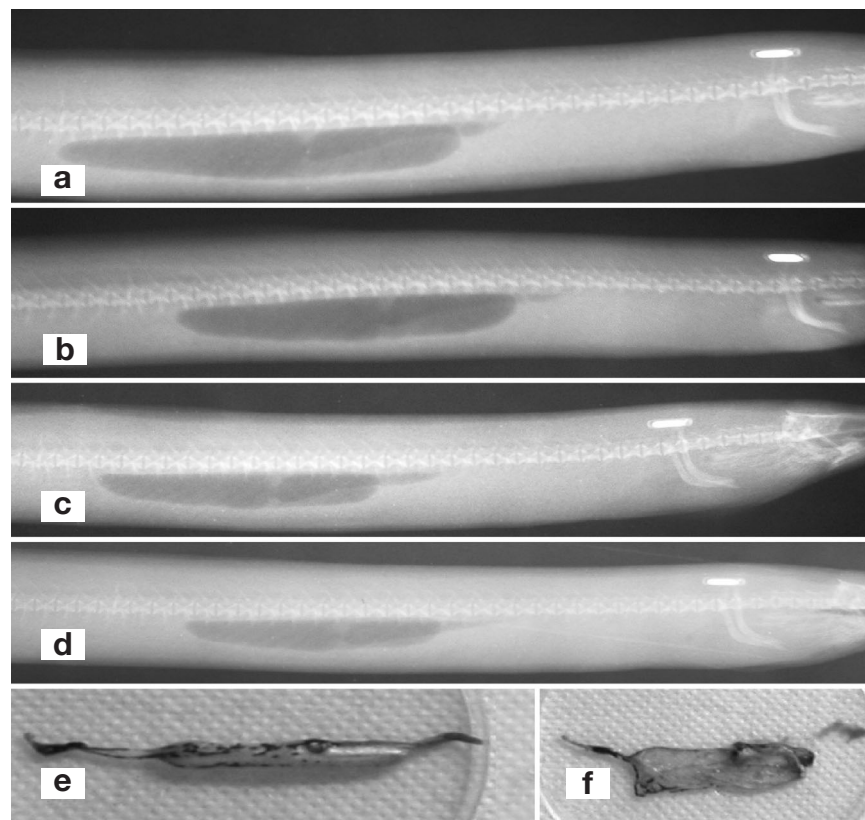


Fig. 1. *Anguillicola crassus* infecting *Anguilla anguilla*. Radiograph of Lake Balaton eel classified in the 'mild swimbladder changes' category at the first X-ray and showing unchanged swimbladder status up to the end of the study. (a–d) Swimbladder is filled with air and no worms are visible. (e) Wall of the swimbladder is transparent but pigmented spots can be seen on the serosa. (f) The swimbladder is thin-walled and worm-free.

Reductions: (a,b) $\times 0.55$, (c–f) $\times 0.5$

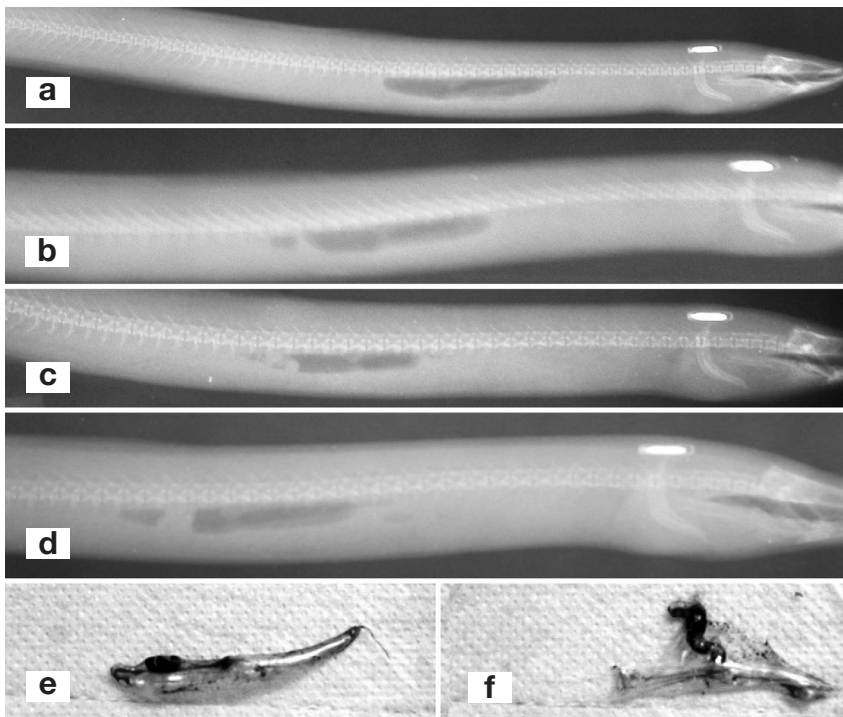


Fig. 2. *Anguillicola crassus* infecting *Anguilla anguilla*. Radiograph of Lake Balaton eel in the 'mild swimbladder changes' category at the first X-ray and seeming to be free of *A. crassus* in the swimbladder lumen. (b–d) Radiographic shadow of 1 worm is clearly visible in a part of the lumen. (e) Swimbladder is filled with air; the serosa is only slightly pigmented, and an adult worm is located in the pneumatic duct. (f) Lumen of the swimbladder does not contain worms; the swimbladder wall is thin, and there is a single worm in the pneumatic duct. Reductions: (a) $\times 0.4$, (b) $\times 0.6$, (c–f) $\times 0.7$

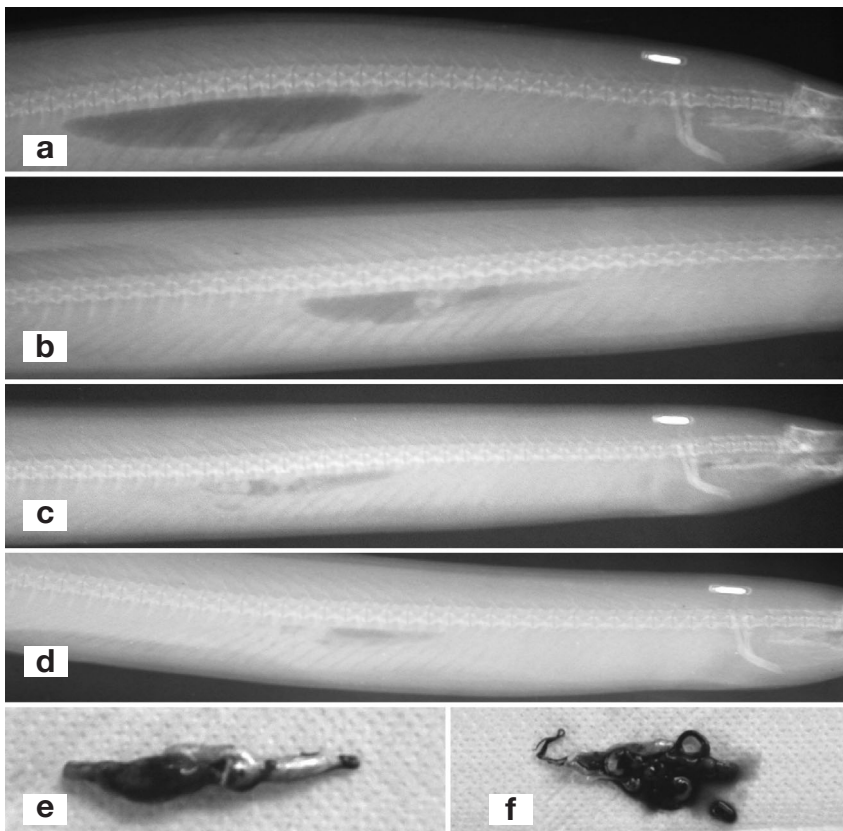


Fig. 3. *Anguillicola crassus* infecting *Anguilla anguilla*. Radiograph of eel in the 'mild swimbladder changes' category, with intact swimbladder at the first X-ray. (a–d) Status of the swimbladder gradually deteriorated during the study due to constriction of the lumen, thickening of the swimbladder wall and the growth of worms living in the lumen. (e) Swimbladder does not contain air; its wall is fibrotic, and the dilated pneumatic duct contains worms. (f) Lumen of the opened swimbladder, which has a thickened wall (2 mm), contains worm debris, and the pneumatic duct is completely filled by 3 worms. Reductions: (a,b) $\times 0.55$, (c–f) $\times 0.5$

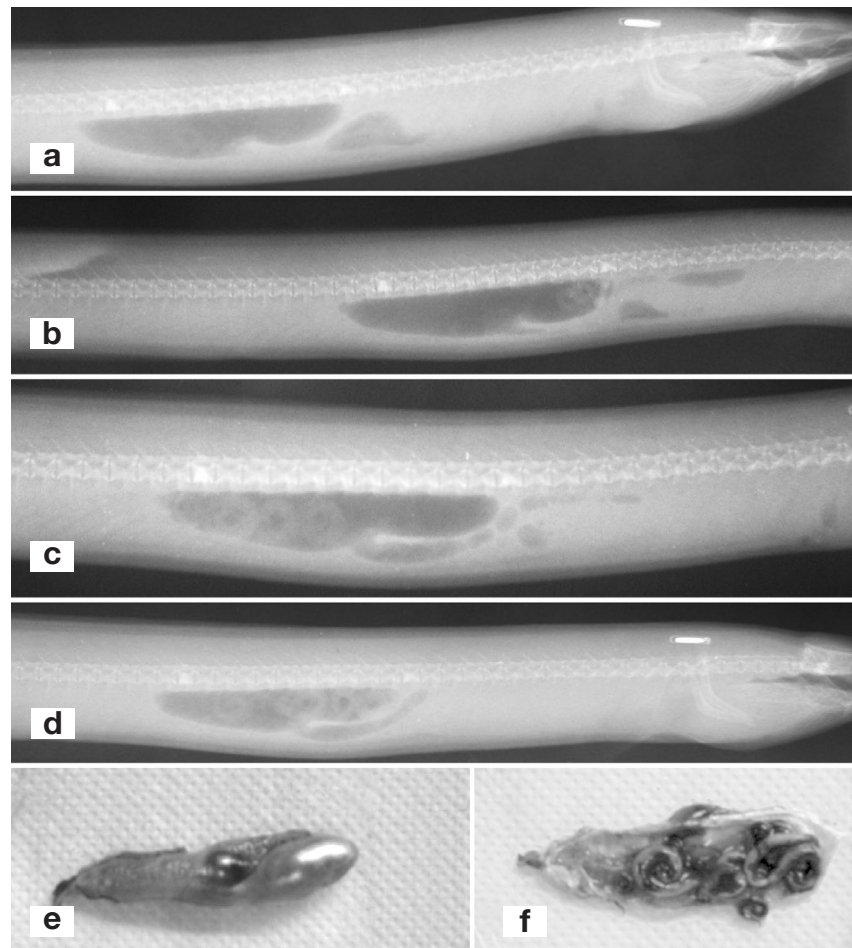


Fig. 4. *Anguillicola crassus* infecting *Anguilla anguilla*. Radiograph of Lake Balaton eel in the 'moderate swimbladder changes' category at the first X-ray. Swimbladder is intact and contains a few worms. (a–d) Number of worms present in the swimbladder lumen has increased as compared to the initial status. (e) Swimbladder is filled with air and its wall is 1 mm thick and haemorrhagic. (f) Swimbladder is half filled by 12 adult worms. Reductions: (a,b,d) $\times 0.5$, (c,e,f) $\times 0.6$

Similar processes could be observed in individuals diagnosed as having moderate swimbladder changes at the first X-ray examination. In several cases, a few worms were also discernible in the lumen of the swimbladder on the first radiograph. The contours of these worms gradually became more and more distinct by the time of the subsequent X-ray examinations, and at dissection large numbers of worms were found in the still relatively thin-walled, air-containing swimbladder (Fig. 4). In some individuals the infection took a more acute course: in these cases, the air had disappeared from the swimbladder by the time of the third and fourth radiographic examination, and at the time of dissection some worms could be found in the thick-walled swimbladder and occasionally also in the pneumatic duct (Fig. 5). There were cases when the swimbladder was found to have moderate changes at the first X-ray examination, then after a transient deterioration its condition improved, and finally, during dissection a few worms were detected in the swimbladder, which presented a slightly thickened wall (Fig. 6).

In some of the eels classified in the category of severe swimbladder changes on the basis of the first radiograph, the radiographic shadow of the swimbladder was not discernible at the first X-ray examination or at any subsequent examinations. In 1 of these eels the swimbladder could not be found at all upon dissection (Fig. 7). In other cases, when a small volume of air was still present at the beginning of the study and the less marked contours were suggestive of a thickened swimbladder wall and the presence of worms, the loss of contour found at the repeated radiographic examinations was explained by a further thickening of the swimbladder wall (3 to 4 mm) and the complete absence of air from the swimbladder, as well as by the presence of worms (Fig. 8). In a swimbladder found to be severely changed and showing no radiographic shadow at the first examination the contour of the swimbladder had appeared by the time of the third X-ray examination; these contours had shrunk slightly by the time of the fourth examination. On dissection, a few smaller worms were found in the fibrotic swimbladder of this eel (Fig. 9).

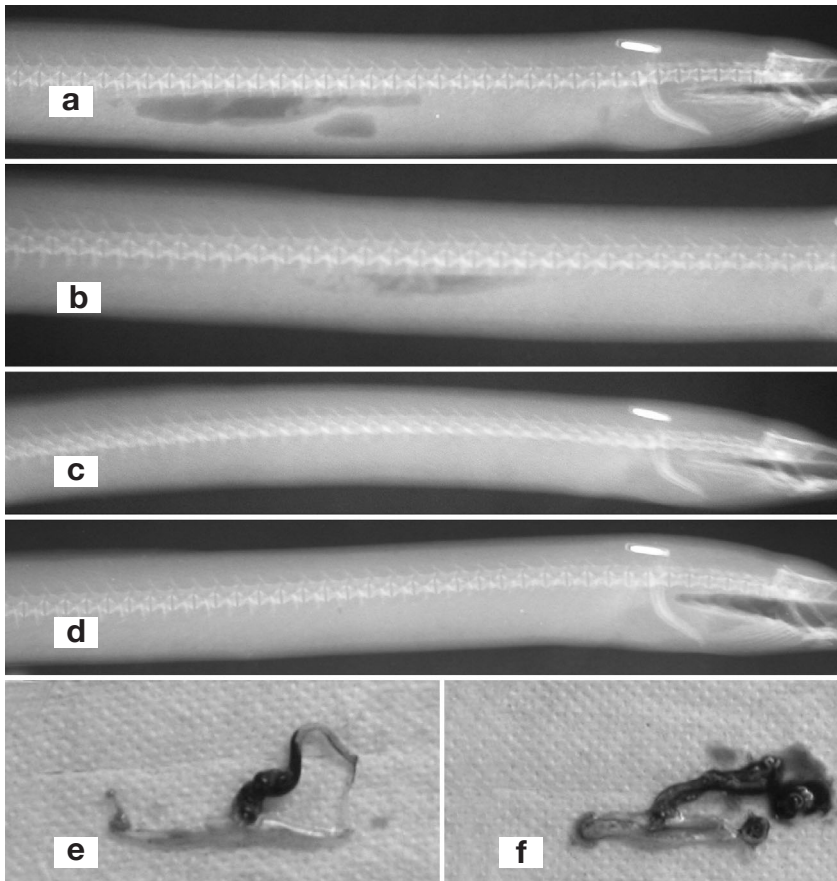


Fig. 5. *Anguillicola crassus* infecting *Anguilla anguilla*. Radiograph of Lake Balaton eel in the 'moderate swimbladder changes' category, with a relatively intact swimbladder, at the first X-ray. (a–b) Only some parts of the swimbladder give a radiographic shadow and worms can be seen in the swimbladder lumen. (c–d) Radiographic shadow of the swimbladder is no longer discernible. (e) Swimbladder does not contain air and the worms are located in the pneumatic duct. (f) Wall of the swimbladder is markedly thickened (2 mm). Pneumatic duct contains 3 worms and debris of disintegrated worms. Reductions: (a,b,e,f) $\times 0.55$, (c) $\times 0.45$, (d) $\times 0.5$

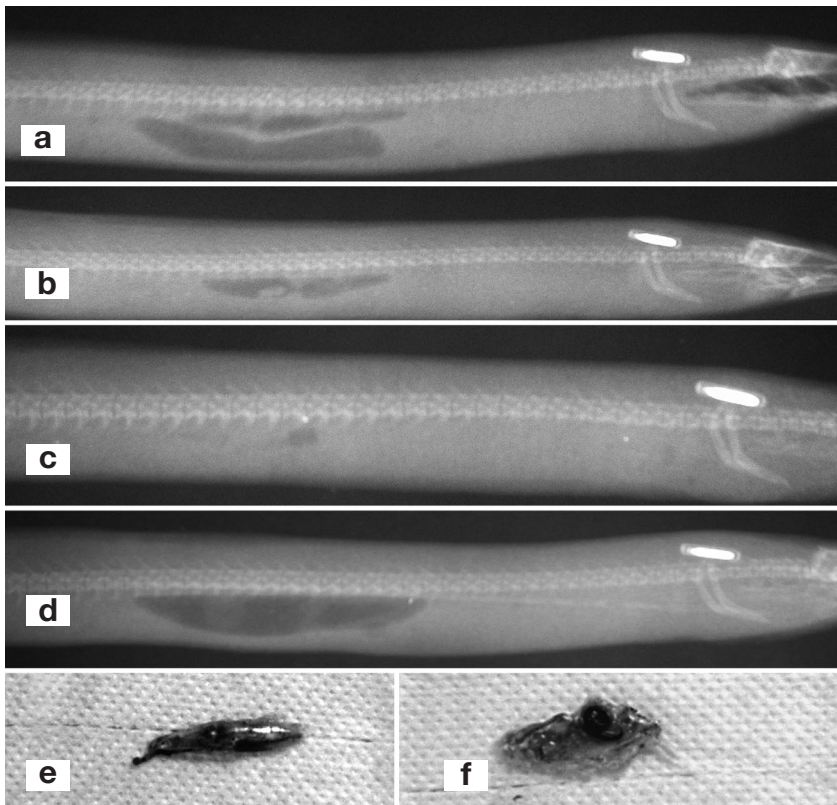


Fig. 6. *Anguillicola crassus* infecting *Anguilla anguilla*. Radiograph of eel in the 'moderate swimbladder changes' category, showing a relatively intact swimbladder at the first X-ray. (a–d) Status of the swimbladder as shown by its radiographic shadow varied during the course of the study, first deteriorating and then improving. (e) Wall of the swimbladder is transparent and the lumen contains worms. (f) Wall of the swimbladder is thin and the lumen contains 2 worms. Reduction of the size of the radiographic shadow (a–c) can be explained by the increase in number and size of worms. By the time of the fourth X-ray examination (d) the majority of the worms had left the swimbladder, presumably through the pneumatic duct, and thus the contours of the swimbladder again became more pronounced. Reductions: (a,b) $\times 0.65$, (c) $\times 0.85$, (d) $\times 0.75$, (e,f) $\times 0.45$

Fig. 7. *Anguillicola crassus* infecting *Anguilla anguilla*. Radiograph of eel in the 'severe swimbladder changes' category at the first X-ray. (a–d) Radiographic shadow of the swimbladder is not discernible in the pictures. The assumed status of the swimbladder remained unchanged during the study. At the time of dissection, neither the swimbladder nor its remnants could be detected. Reductions: (a–c) $\times 0.6$, (d) $\times 0.5$

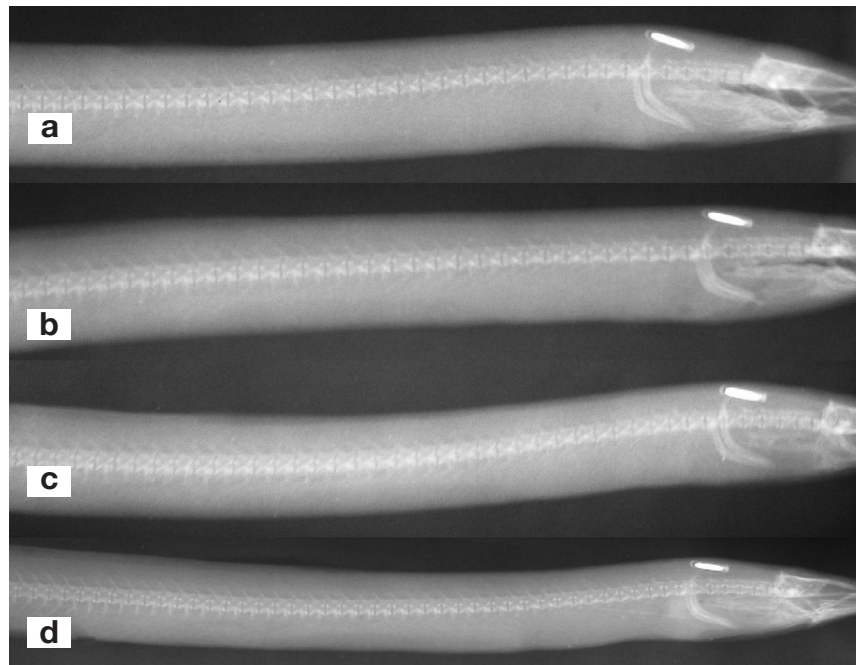



Fig. 8. *Anguillicola crassus* infecting *Anguilla anguilla*. Radiograph of eel in the 'severe swimbladder changes' category at the first X-ray. (a–d) Status of the swimbladder continuously deteriorated during the study; contours of the swimbladder gradually became smaller on successive X-rays and were not discernible at all at the fourth X-ray. Absence of air was due to the growth and increasing number of worms. (e) Small-sized swimbladder is filled with large numbers of worms. (f) Wall of the swimbladder is thin and the lumen is filled with 8 large worms. Reductions: (a) $\times 0.65$, (b–d) $\times 0.6$, (e,f) $\times 0.5$



DISCUSSION

The results obtained during this study prove that during prolonged laboratory maintenance of *Anguillicola crassus*-infected eels no improvement can be

observed in the condition of the swimbladder. In some eels, the condition of the swimbladder did not change, but in the majority of cases the swimbladder deteriorated. The findings of the current study also indicate that statements made in earlier works of the research

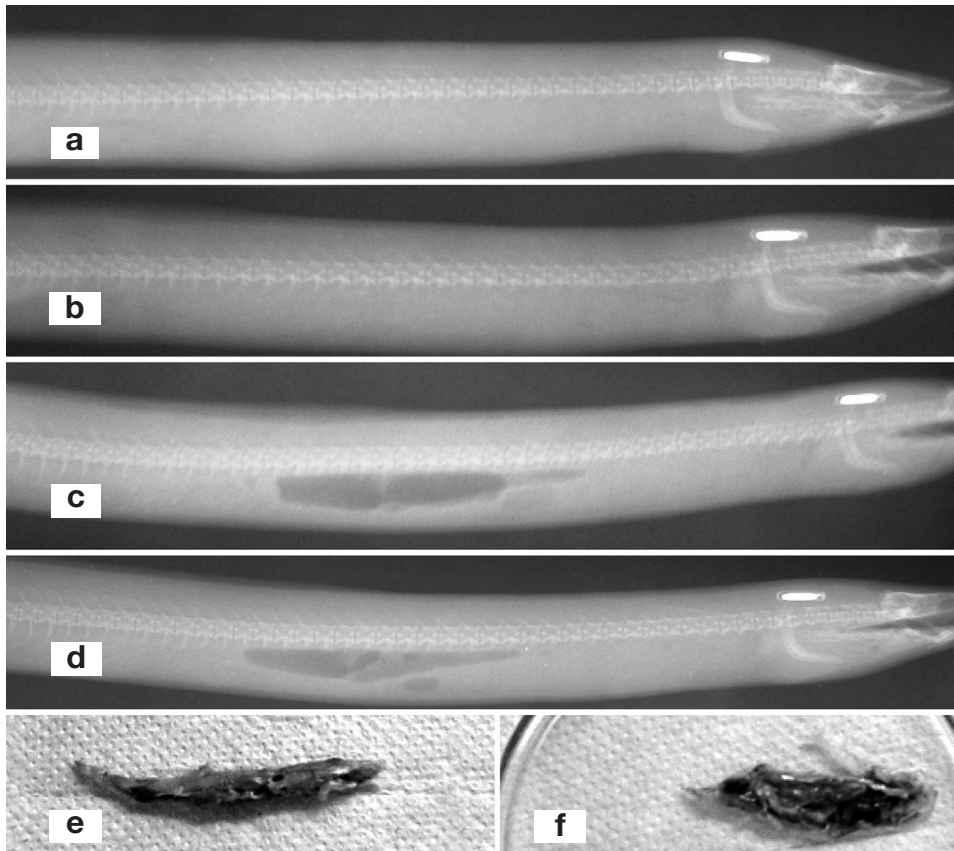


Fig. 9. *Anguillicola crassus* infecting *Anguilla anguilla*. Radiograph of Lake Balaton eel in the category 'severe swimbladder changes' at the first X-ray. (a–d) During the study, the status of the swimbladder initially remained unchanged, and later improved. (e) Swimbladder is opaque but contains air. (f) Wall of the swimbladder is thick (2.5 mm) and fibrotic, and the lumen contains 2 relatively small worms. By third X-ray, the swimbladder contours had become more pronounced, presumably because the majority of the large numbers of worms present in the lumen at the first and second X-rays had left the swimbladder through the pneumatic duct. Paleness of the anterior part of the swimbladder in (c) and the very pale contours of the swimbladder in (d) are indicative of gradual thickening of the swimbladder wall. Reductions: (a,c,d) $\times 0.6$, (b,e,f) $\times 0.7$

team (Beregi et al. 1998, 2001, Székely et al. 2004) require certain modifications. These authors were of the opinion that the total absence of swimbladder contours on the radiographs consistently indicated a marked thickening of the swimbladder wall accompanied by a parallel reduction in the swimbladder lumen. In the present study, however, the above statement could only partially be verified. Repeated radiographs taken from the same fish demonstrate that a lack of contour may also occur if the entire lumen of the swimbladder is filled with worms. In such cases the growing worms gradually expel air from the swimbladder lumen. Naturally, a combination of swimbladder shrinkage associated with swimbladder wall thickening and obstruction of the swimbladder lumen by worms may also result in the absence of swimbladder contours on the radiograph.

The 2 cases of 'variable' swimbladder condition (Figs. 6 & 9) that could not be classified into either the 'unchanged' or the 'deteriorating' category can also be explained by the dynamics of *Anguillicola crassus* infection. It is a well-known fact that some of the older worms die and disintegrate in the lumen of the swimbladder (Molnár et al. 1993). It is also known, and was

also recorded several times in this study, that some worms may leave the swimbladder lumen through the pneumatic duct (De Charleroy et al. 1990). It may be assumed that, in such cases, air can reappear in the swimbladder, which, until this point has been devoid of air and shown no radiographic shadow. In this case, a previous massive swimbladder infection is indicated only by a few retained worms or some young worm specimens newly developed from the larvae.

The results of this study are in apparent contradiction with the findings of earlier surveys on eels living in natural waters (Molnár et al. 1994, Adenauert et al. 2003). These studies suggested that the dynamics of anguillicolosis are characterised by continuous variability: after the excretion of worms, even eels with relatively massive infection may become helminth free, and their swimbladders also have a certain degree of regenerative potential. However, these contradictions obviously arise from differences in the study conditions. The absence of infection dynamics typical of the natural habitat of fish can also be explained by the unnatural conditions of a laboratory study. At the same time, the present study has shed light on the type of changes that can be expected in an *Anguillicola* infec-

tion of eels subjected to prolonged laboratory experiments. The condition of the swimbladder consistently changed for the worse. A decrease in worm count rarely occurred, and even in this case, a thickening of the swimbladder wall and reduction of the swimbladder lumen could be detected.

Acknowledgements. The authors are indebted to Mrs. Györgyi Ostoros Pataki, Mrs. Józsefné Kampó, András Specziár, István Báthory and Géza Dobos for their valuable help during this work. Financial support was provided by research contracts EU Q5RS-2001-01836 (EELREP) and the Hungarian Scientific Research Fund (OTKA) project no. T 45891.

LITERATURE CITED

- Adenauert V, Huysse T, Goemans G, Belpaire C, Volckaert F (2003) Spatio-temporal dynamics of the parasitic nematode *Anguillicola crassus* in Flanders, Belgium. *Dis Aquat Org* 56:223–233
- Barus V, Prokes M (1996) Length-weight relations of uninfected and infected eels (*Anguilla anguilla*) by *Anguillicola crassus* (Nematoda). *Folia Zool* 45:183–189
- Beregi A, Molnár K, Békési L, Székely C (1998) Radiodiagnostic method for studying swimbladder inflammation caused by *Anguillicola crassus* (Nematoda: Dracunculoidea). *Dis Aquat Org* 34:155–160
- Beregi A, Székely C, Békési L, Szabó J, Molnár V, Molnár (2001) Radiodiagnostic examination of the swimbladder of some fish species. *Acta Vet Hung* 49:87–98
- Böttcher K, Böttcher M (2000) Röntgendiagnostik bei Fischen: Röntgenanatomie des Karpfens. *Kleintierpraxis* 45:351–358
- Böttcher K, Böttcher M (2003a) Bildgebende Diagnostik bei Fischen (Teil 1): Dislokationen und Vergrößerungen sowie Ergüsse der Schwimmblase. *Kleintierpraxis* 48:481–488
- Böttcher K, Böttcher M (2003b) Bildgebende Diagnostik bei Fischen (Teil 2): Entzündungen der Schwimmblase und 'Kopfsteher-Syndrom'. *Kleintierpraxis* 48:547–552
- De Charleroy D, Grisez L, Thomas K, Belpaire C, Ollevier F (1990) The life cycle of *Anguillicola crassus*. *Dis Aquat Org* 8:77–84
- Dekker W (2003) Did lack of spawners cause the collapse of the European eel, *Anguilla anguilla*? *Fish Manag Ecol* 10:365–376
- EELREP Q5RS-2001-01836 (2001) Estimation of the reproduction capacity of European eel. Enhancing the biological basis for sustainable fisheries and aquaculture. Available at: <http://www.fishbiology.net/silvereel.html>
- Egusa S (1979) Notes on the culture of the European eel (*Anguilla anguilla* L.) in Japanese eel farming ponds. *Rapp P-V Réun Comm Int Explor Sci Mer Médit* 174:51–58
- Kirk R (2003) The impact of *Anguillicola crassus* on European eels. *Fish Manag Ecol* 10:385–394
- Molnár K (1993) Effect of decreased oxygen content on eels (*Anguilla anguilla*) infected by *Anguillicola crassus* (Nematoda: Dracunculoidea). *Acta Vet Hung* 41:349–360
- Molnár K, Baska F, Csaba Gy, Glávits R, Székely C (1993) Pathological and histopathological studies of the swimbladder of eel *Anguilla anguilla* infected by *Anguillicola crassus* (Nematoda: Dracunculoidea). *Dis Aquat Org* 15:41–50
- Molnár K, Székely C, Perényi M (1994) Dynamics of *Anguillicola crassus* (Nematoda: Dracunculoidea) infection in eels of Lake Balaton, Hungary. *Folia Parasitol* 41:193–202
- Moravec F (1992) Spreading of the nematode *Anguillicola crassus* (Dracunculoidea) among eel population in Europe. *Folia Parasitol* 39:247–248
- Nagasawa K, Kim Y, Hirose H (1994) *Anguillicola crassus* and *A. globiceps* (Nematoda: Dracunculoidea) parasitic in the swimbladder of eels (*Anguilla japonica* and *A. anguilla*) in East-Asia: a review. *Folia Parasitol* 41:127–137
- Sprengel G, Luchtenberg H (1991) Infection by endoparasites reduces maximum swimming speed of European smelt *Osmerus eperlanus* and European eel, *Anguilla anguilla*. *Dis Aquat Org* 11:31–35
- Székely C, Molnár K, Müller T, Szabó A, Romvári R, Hancz C, Bercsényi M (2004) Comparative study of X-ray computerised tomography and conventional X-ray methods in the diagnosis of swimbladder infection of eel caused by *Anguillicola crassus*. *Dis Aquat Org* 58:157–164
- Vettier A, Székely C, Sébert P (2003) Are yellow eels from Lake Balaton able to cope with high pressure encountered during migration to the Sargasso sea? The case of energy metabolism. *Anim Biol* (formerly: *Neth J Zool*) 53:329–338
- Würtz J, Taraschewski H (2000) Histopathological changes in the swimbladder wall of the European eel *Anguilla anguilla* due to infection with *Anguillicola crassus*. *Dis Aquat Org* 39:121–134

Editorial responsibility: Wolfgang Körting, Hannover, Germany

*Submitted: June 7, 2004; Accepted: August 24, 2004
Proofs received from author(s): February 22, 2005*