

Vitamin C attenuates methotrexate-induced oxidative stress in kidney and liver of rats

M Savran¹, E Cicek², DK Doguc³, H Asci², S Yesilot², IA Candan⁴, B Dagdeviren³, FN Cankara², M Oncu⁴, AC Uğuz⁵, MK Ozer⁶

¹Provincial Directorate of Health, Republic of Turkey Ministry of Health, Antalya, Turkey

²Department of Pharmacology, School of Medicine, Süleyman Demirel University, Isparta, Turkey

³Department of Biochemistry, School of Medicine, Süleyman Demirel University, Isparta, Turkey

⁴Department of Histology and Embryology, School of Medicine, Süleyman Demirel University, Isparta, Turkey

⁵Department of Biophysics, School of Medicine, Süleyman Demirel University, Isparta, Turkey

⁶Department of Pharmacology, School of Medicine, Firat University, Elazığ, Turkey

Received: December 30, 2015

Accepted: May 29, 2017

Like several other anticancer drugs, methotrexate (MTX) causes side effects, such as neuropathic pain, hepatotoxicity, and nephrotoxicity. Abnormal production of reactive oxygen species has been suspected in the pathophysiology of MTX-induced hepatorenal toxicity. Therefore, the aim of this study was to investigate the probable protective role of vitamin C (Vit C) on oxidative stress induced by MTX in the liver and kidney tissues of rats. A total of 32 rats were randomly and equally divided into four groups. The first group served as the control group. The second group received a single dose of 20 mg/kg of MTX intraperitoneally. To demonstrate our hypothesis, the third and the fourth groups received 250 mg/kg of Vit C for 3 days by oral gavage, with or without MTX treatment. At the end of the study, the liver and kidney tissues of the rats were collected and examined using histology. Both the tissues were assayed for malondialdehyde concentration and superoxide dismutase (SOD), catalase (CAT), and glutathione peroxidase (GSH-Px) activities. In hepatic and renal tissues, lipid peroxidation levels were increased, whereas SOD, CAT, and GSH-Px levels were decreased by MTX. All parameters, including CAT levels in hepatic tissue, were significantly restored after the administration of Vit C for 3 days. Similar to the biochemical findings, evidence of oxidative damage was examined in both types of tissues by histopathological examination. From the results of this study, we were able to observe that Vit C administration modulates the antioxidant redox system and reduces the renal and hepatic oxidative stress induced by MTX. Vit C can ameliorate the toxic effect of MTX in liver and kidney tissues of rat.

Keywords: methotrexate, vitamin C, kidney, liver, oxidative stress

Introduction

Methotrexate (MTX), a folate antagonist, is used in higher doses for the treatment of several types of cancer, in relatively lower doses for the treatment of autoimmune diseases like rheumatoid arthritis, and with conservative usage in the treatment of ectopic pregnancy (Oktem et al., 2006). The clinical use of MTX is limited due to dose-dependent hepatotoxicity and nephrotoxicity (11, 27). The exact mechanisms of MTX-induced liver toxicity are not clear, but there are several hypotheses which have been proposed for this injury. One of them is cellular antioxidant defense deregulation that causes more oxidative stress-induced

Corresponding author: Dr. A. Cihangir Uğuz

Department of Biophysics, School of Medicine, Süleyman Demirel University

Cunur, Isparta TR-32260, Turkey

Phone: +90 246 211 36 60; Fax: +90 246 237 11 65; E-mail: cihangiruguz@yahoo.com

damages to the liver cells. Another complication of MTX treatment is the nephrotoxicity that also seems to be related to reactive oxygen species (ROS). As the oxidative damage by ROS has been implicated in the pathogenesis of MTX toxicity (11, 27), several antioxidant agents have been reported to specifically prevent hepatorenal damage following the MTX administration (12).

ROS, which led to death of cells by damaging the biomolecules, such as lipids, proteins, and DNA, act as an intracellular messenger in physiological processes, such as gene expression, signal transduction, and regulation of cell proliferation, when they are excessively generated or when enzymatic and non-enzymatic defense systems are impaired (17). The major intracellular antioxidant enzymes, glutathione peroxidase (GSH-Px) and catalase (CAT), detoxify hydrogen peroxide (H_2O_2) into water, although superoxide dismutase (SOD) enzyme dismutates superoxide radical into H_2O_2 . Therefore, ROS can indirectly be evaluated by the measurement of some antioxidants, such as GSH-Px, SOD, and CAT (5). Vitamin C (Vit C), also known as ascorbic acid, is a well-known water-soluble antioxidant agent that is present in cells, body fluids, and plasma. Vit C not only acts as an ROS scavenger but also plays a role in the oxidative stress pathways as an essential coenzyme and was used in various studies for this property (9). However, nowadays, it is not being used in MTX-induced hepatorenal toxicity. These, including lipid peroxidation product malondialdehyde (MDA), reflect damage and activity of antioxidant enzymes, such as SOD, CAT, and GSH-Px, in the liver and kidney (which are used to indicate the tissue damage due to oxidative stress). According to our knowledge, there have been no studies evaluating the protective roles of Vit C administration against oxidative damage in renal and liver tissues triggered by MTX. Based on this, this research was conducted to investigate the probable role of the short-term regulatory/protective effect of Vit C against oxidative stress in the kidneys and livers of rats exposed to the MTX administration.

Materials and Methods

Experimental conditions

Wistar rats, 12–16 weeks of age, weighing 200–250 g, were maintained at a temperature of 21 ± 2 °C with a 12-h light and 12-h dark cycle. Vit C dosage was determined according to previous studies (1, 16, 26). The rats were divided into four groups (six rats per group, except control. Control group included eight rats):

Group I: The control group received only physiological saline intraperitoneally (i.p.) for 3 days (control group).

Group II: The MTX alone group received 20 mg of MTX/kg of body weight (i.p.) (Emthexate-S 5 mg 1 vial/Pharmachemie B.V./Holland) at a single dose (12).

Group III: The Vit C alone group received 250 mg of Vit C/kg of body weight (1) for 3 days. The Vit C was dissolved into the rats' drinking water.

Group IV: The MTX + Vit C group received 250 mg of Vit C/kg of body weight (by oral gavage) 1 h before the application of 20 mg of MTX/kg of body weight at a single dose (i.p.) and continued for 2 days.

Twenty-four hours after the last dose of Vit C, all the rats were anesthetized by i.p. injection of 50 mg/kg ketamine + 10 mg/kg xylazine mixture, subsequently, the kidneys and livers of rats were then quickly removed, decapsulated, and divided equally into two longitudinal sections. One section was placed in 5% formaldehyde solution for routine

histopathological examination by light microscopy. The other section was placed into liquid nitrogen and stored at -70°C until assayed for MDA, SOD, CAT, and GSH-Px activities. In each group, except the control one, two rats died due to diarrhea. All experiments in this study were performed in accordance with the guidelines for animal research from the National Institutes of Health and were approved by the Committee on Animal Research at Süleyman Demirel University, Isparta, Turkey (30.03.2010/03).

Biochemical analyses

MDA assay. MDA level was determined according to the double heating method of Draper and Hadley (8). The principle of the method was spectrophotometric measurement of the color produced during the reaction of thiobarbituric acid (TBA) with MDA. For this purpose, 2.5 ml of 100 g/l trichloroacetic acid solution was added to 0.5 ml of supernatant of tissue homogenate (1.15% KCl) in a centrifuge tube and placed in a boiling water bath for 15 min. After cooling in tap water, the mixture was centrifuged at 1,000g for 10 min, and 2 ml of supernatant was separated and added into a new test tube. An amount of 1 ml of 6.7 g/l TBA solution was added and the mixture was placed in a boiling water bath for 15 min. The solution was then cooled in tap water, and its absorbance was measured using a spectrophotometer at 532 nm. An amount of 8,360 $\mu\text{mol/l}$ stock solution of 1,1,3,3-tetraethoxypropane, which was prepared with 40% ethanol, was used as standard with serial dilutions (83.6, 41.8, 20.9, 10.47, 5.22, 4.86, 2.43, 1.22, and 0.62 $\mu\text{mol/l}$). To determine the concentration of each tissue sample, standard-absorbance curve plot was used and the concentration of MDA is expressed as nmol/g protein. Shimadzu UV-1601 spectrophotometer (Shimadzu, Kyoto, Japan) was used to estimate the levels of MDA.

SOD activity assay. SOD activity was estimated by following the method of Sun et al. (22). The measurement of SOD was based on the principle in which xanthine reacts with xanthine oxidase to generate superoxide radicals, which react with 2-(4-iodophenyl)-3-(4-nitrophenol)-5-phenyltetrazolium chloride to form a red formazan dye. The SOD activity is then measured by the degree of inhibition of this reaction. The results were expressed as U/g protein.

CAT activity assay. CAT activity was measured according to the method of Aebi (2). The principle of the assay is based on the determination of the rate constant (k/s) of H_2O_2 decomposition by CAT enzyme. The results were expressed as U/g protein.

GSH-Px activity assay. The determination of GSH-Px activity was based on the method of Paglia and Valentine (18). The principle of the method is as follows: GSH-Px catalyzes the oxidation of GSH by cumene hydroperoxide. In the presence of GSH reductase and nicotinamide adenosine diphosphate hydrogen (NADPH), the oxidized GSH is immediately converted to the reduced form with a concomitant oxidation of NADPH to nicotinamide adenosine diphosphate (NADP^+). The decrease in absorbance of NADPH was measured at 340 nm. The results were expressed as U/g protein.

Histopathological analyses

Paraffin-embedded kidney and liver tissues were cut at 4 μm and stained with hematoxylin and eosin (H&E). Histological specimens from kidney and liver tissues were histopathologically evaluated using slides stained with H&E. The slides were then examined using Olympus BX50 and photographed. An effort was made to determine mononuclear infiltration and degeneration of the normal tissue.

Protein assay

The protein content in the liver and kidney tissues was measured according to the method of Lowry et al. (14) with bovine serum albumin as the standard.

Statistical analysis

Statistical evaluations were carried out using the “SPSS 11.0 for Windows” software package and Epi Info StatCalc programs. Comparison of measured values was carried out between the two groups (biochemical values) using ANOVA test and group-to-group comparison using Tukey’s test. Pearson’s χ^2 test was used for positions in the tables below the expected value of 5 in the case. Fisher’s χ^2 test was also used. Relevance 95% confidence intervals and p values <0.05 were chosen as statistical significant difference.

Results

Biochemical analyses

MDA levels and activities of antioxidant enzymes, such as SOD, CAT, and GSH-Px, in liver and kidney tissues are shown in Tables I and II, respectively. We found that MDA levels were significantly higher and activities of SOD, CAT, and GSH-Px were significantly lower in the MTX-administered rats compared with the control group ($p = 0.034$). Vit C administration significantly reduced the level of MDA and significantly increased the SOD and GSH-Px activities. In the Vit C alone group, CAT activity was found to be decreased compared with the control group. CAT levels were increased when comparing with MTX and MTX + Vit C groups.

Histopathological analyses

Histopathological appearances of liver and renal tissues are shown in Figs 1 and 2, respectively.

Table I. Malondialdehyde (MDA) levels and catalase (CAT), superoxide dismutase (SOD), and glutathione peroxidase (GSH-Px) activities in liver tissues

Groups (liver)	MDA (nmol/g protein)	CAT (U/g protein)	SOD (U/g protein)	GSH-Px (U/g protein)
Group I (control)	26.8 ± 6.23	20.3 ± 5.60	636.2 ± 13.03	136 ± 2.45
Group II (MTX)	63.6 ± 13.80 ^a	12.2 ± 3.05 ^a	473.7 ± 42.32 ^a	94.3 ± 13.14 ^a
Group III (Vit C)	24.1 ± 4.36 ^b	18.5 ± 3.88 ^b	686.96 ± 61.87 ^b	184.64 ± 18.03 ^b
Group IV (MTX + Vit C)	32.7 ± 8.24 ^{a,b,c}	16.4 ± 4.72 ^{a,b,c}	635.0 ± 26.18 ^{a,b,c}	164.86 ± 13.71 ^{a,b,c}

Values are means ± SEM, $n = 6$ in each group except control ($n = 8$).

(I) Control, (II) 20 mg/kg methotrexate (MTX) (i.p.) at a single dose, (III) 250 mg/kg Vit C for 3 days (orally), and (IV) 250 mg/kg Vit C (orally) 1 h prior to 20 mg/kg MTX at a single dose (i.p.) and continued for 2 days.

^a $p = 0.027$ vs. control.

^b $p = 0.039$ vs. MTX.

^c $p = 0.041$ vs. Vit C

Table II. Malondialdehyde (MDA) levels and catalase (CAT), superoxide dismutase (SOD), and glutathione peroxidase (GSH-Px) activities in kidney tissues

Groups (kidney)	MDA (nmol/g protein)	CAT (U/g protein)	SOD (U/g protein)	GSH-Px (U/g protein)
Group I (control)	14.7 ± 5.01	13.23 ± 1.7	444.61 ± 157.12	937.35 ± 17.60
Group II (MTX)	39.26 ± 1.97 ^a	7.74 ± 2.92 ^a	196.3 ± 9.09 ^a	667.22 ± 55.76 ^a
Group III (Vit C)	13.70 ± 4.14 ^{a,b}	17.7 ± 3.7 ^{a,b}	593.4 ± 140.83 ^{a,b}	957.15 ± 27.92 ^{a,b}
Group IV (MTX + Vit C)	15.95 ± 4.68 ^{a,b,c}	15.2 ± 3.18 ^{a,b,c}	331.08 ± 10.47 ^{a,b,c}	796.02 ± 81.75 ^{a,b,c}

Values are means ± SEM, $n = 6$ in each group except control ($n = 8$).

(I) Control, (II) 20 mg/kg methotrexate (MTX) (i.p.) at a single dose, (III) 250 mg/kg Vit C for 3 days (orally), and (IV) 250 mg/kg Vit C (orally) 1 h prior to 20 mg/kg MTX at a single dose (i.p.) and continued for 2 days.

^a $p = 0.032$ vs. control.

^b $p = 0.043$ vs. MTX.

^c $p = 0.038$ vs. Vit C

Hepatic histopathology. The histopathological appearance of liver tissues was normal in the control group rats (data not shown). Major histopathological changes were observed in the MTX alone group (Fig. 1A), including notable granular degeneration in hepatocytes, inflammatory cell infiltration, and the increase in connective tissues in portal area. In addition, pyknotic nuclei in hepatocytes, vascular congestion, and sinusoidal dilatation at low levels were detected. In the Vit C alone group (Fig. 1B), granular degeneration was shown to be at high level, whereas inflammatory cell infiltration in portal area, vascular congestion, and sinusoidal dilatation at low levels. In the MTX + Vit C group (Fig. 1C), the histopathological changes were less than those in the MTX alone group, such as hepatic granular degeneration at mild level, inflammatory cell infiltration in portal area, and pyknotic nuclei, bile duct proliferation, vascular congestion, and sinusoidal dilatation at low levels.

Renal histopathology. The histopathological appearance of kidney tissues was normal in the control group (data not shown). In the MTX alone group, the evidence of hydropic degeneration was examined in proximal and distal tubular epithelial cells, and inflammatory cell infiltration was examined in perivascular and intertubular areas (Fig. 2A). In addition, vascular and glomerular congestions, tubular dilatation, atrophy in some tubules, and narrowing in some Bowman's capsules were detected (Fig. 2A). In the Vit C alone group, glomerular and vascular congestions were detected at mild levels, whereas inflammatory cell infiltration and tubular dilatation at low levels, and narrowing in some Bowman's capsules was detected (Fig. 2B). In the MTX + Vit C group, vascular congestion, inflammatory cell infiltration, tubular dilatation, and narrowing in some Bowman's capsules were detected (Fig. 2C).

Discussion

This study was designed to determine whether Vit C is a potent antioxidant against MTX-induced oxidative stress in a rat model. In this study, it can easily be observed that MTX significantly altered the parameters of oxidative stress, such as MDA, SOD, CAT, and

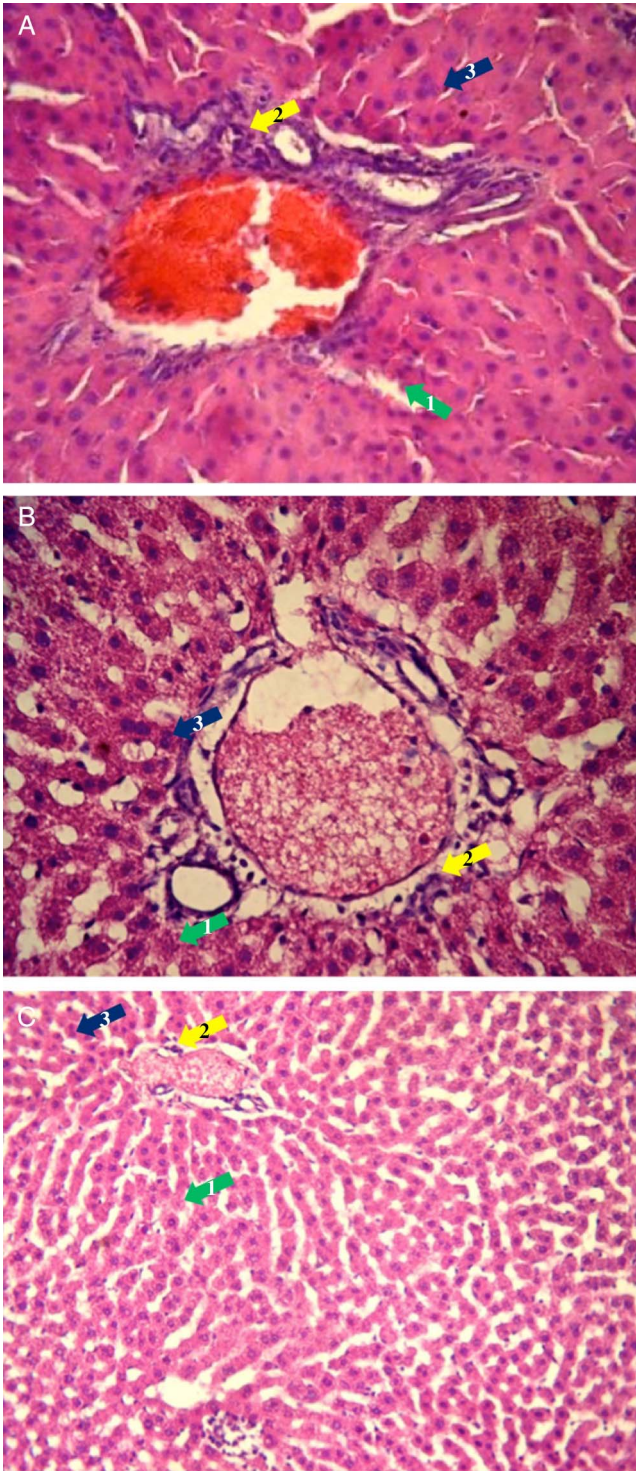


Fig. 1. Histopathological appearance of liver tissue. (A) MTX alone group, liver (H&E, 40 \times). Granular degeneration in hepatocytes, inflammatory cell infiltration, rising connective tissues in portal area, and bile duct proliferation were seen. In addition, mild *pyknotic* nuclei in hepatocytes, vascular congestion, and sinusoidal dilatation at low levels were detected. (B) Vit C alone group, liver (H&E, 40 \times). Granular degeneration at high level and inflammatory cell infiltration in portal area, vascular congestion, and sinusoidal dilatation at low levels were seen. (C) MTX + Vit C group, liver (H&E, 20 \times). Hepatic granular degeneration at mild level, inflammatory cell infiltration in portal area, *pyknotic* nuclei, bile duct proliferation, vascular congestion, and sinusoidal dilatation at low levels were seen. 1: granular degeneration; 2: inflammatory cell infiltration, rising connective tissues, and bile duct proliferation; 3: *pyknotic* nuclei

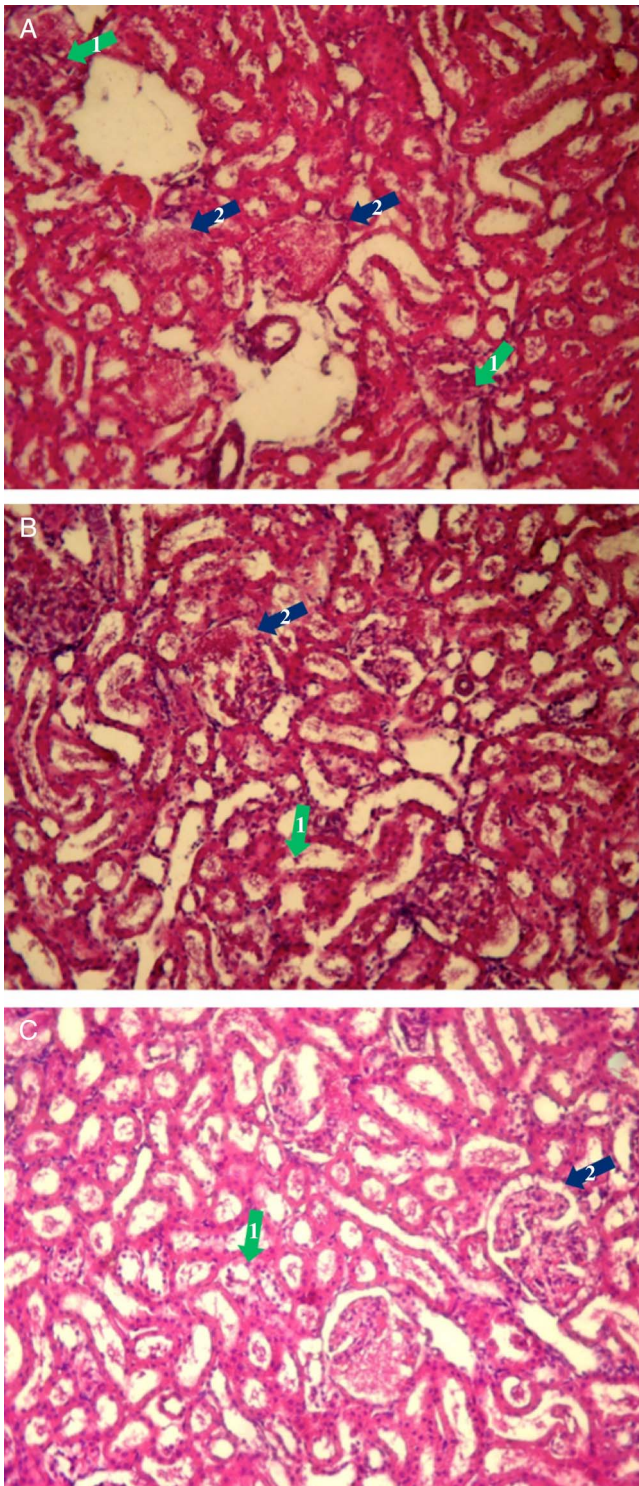


Fig. 2. Histopathological appearance of kidney tissue. (A) MTX alone group, kidney (H&E, 20×). Inflammatory cell infiltration in perivascular and intertubular areas, glomerular congestion, tubular dilatation, atrophy in some tubules, and narrowing in some Bowman’s capsules were detected. (B) Vit C-3 days group, kidney (H&E, 20×). Glomerular and vascular congestions were detected at mild levels, whereas inflammatory cell infiltration and tubular dilatation were at low levels. (C) MTX + Vit C group, kidney (H&E, 20×).

Vascular congestion, inflammatory cell infiltration, and tubular dilatation were detected. 1: tubular damage; 2: glomerular and vascular congestions

GSH-Px levels in the liver and kidney. MDA levels were determined to be significantly higher in the MTX alone group. Moreover, SOD, CAT, and GSH-Px activities were determined to be significantly lower in the only MTX-treated rats compared with the control group ($p < 0.05$). The histopathological findings also supported our biochemical findings. As may be observed in this study, MTX caused liver and kidney injuries by oxidative damage. Although the mechanism of MTX-induced hepatorenal toxicity is not well understood, recent studies indicated the oxidative damage to be the causative factor (19).

It had been shown that the cytosolic NADP-dependent dehydrogenases and NADP-malic enzymes were inhibited by MTX, suggesting that the drug could either decrease the availability of reduced NADPH in cells (12) or NADPH was used by GSH reductase to reduce an important cytosolic antioxidant, GSH. The significant reduction in GSH levels promoted by MTX could cause two results: first, in conjunction with reduced GSH levels, inactivation of reactive molecules; second, the tendency of covalent bonding with other macromolecules increases. This could lead to a reduction in effectiveness of the antioxidant enzyme defense system, sensitizing the cells to ROS (19). Tissue CAT is an important oxidant detoxifier, playing a key role in the elimination of lipid peroxides and H_2O_2 . Moreover, CAT can reduce peroxides by donating hydrogen (7). In addition, our results showed increased levels of CAT activity in the group administered only Vit C. However, the MTX alone group showed statistically decreased CAT activity. Vit C administration reversed the MTX effect in the CAT activity levels. The involvement of oxidative stress in the cell death mechanism has been well documented in the literature. Using antioxidant molecules, which increase the synthesis of GSH against drug-induced hepatorenal injury, has become a common means to investigate the relationship between GSH and the toxic effects of MTX (12). For example, rats having increased MDA levels in blood, liver, and kidney tissues along with reduced blood GSH levels were restored to normal levels using melatonin treatment (12). Vit C has been shown to be an important antioxidant, to regenerate vitamin E (Vit E) through redox cycling and to raise intracellular GSH levels (20). Higher MDA levels and lower GSH, SOD, and CAT activities caused by MTX in liver were normalized through the use of N-acetylcysteine in rats (7). MTX-induced hepatic injury was biochemically and histopathologically impaired by ursodeoxicolic acid (23) and MTX-induced oxidative damage in the liver was biochemically ameliorated by curcumin (11). In a recent study, β -carotene restored the MTX-induced hepatic injury by radical scavenger effect (25). Similarly, a flavonoid molecule, rutin, had been shown to be beneficial for MTX-induced hepatotoxicity by antioxidant effects.

Similar to the hepatic damage, oxidative stress and neutrophil infiltration were found to cause the renal damage (13), and a potential radical scavenger, caffeic acid phenethyl ester, had shown a protective effect against the MTX-induced renal damage (24). In rats administered with MTX, their increased levels of MDA, myeloperoxidase, and collagen content were statistically reduced, whereas in rats administered with L-carnitine, GSH levels were increased (21). In another study, it was found that nephrotoxicity induced by MTX was ameliorated by lycopene alone or combined with melatonin, presumably by antioxidant activity.

The recent studies demonstrate that ROS and H_2O_2 are linked to the development of several pathological processes associated with chemotherapy, including adverse effects of antitumor drugs. It may be inferred that the cells could be more sensitive to ROS, which subsequently results in a reduction in effectiveness of the antioxidant enzyme defense

system (6). As GSH precursor, N-acetylcysteine, can ameliorate paracetamol-induced hepatotoxicity but not nephrotoxicity, Vit C was used for the renal damage induced by paracetamol. Vit C administered in different dosages (250, 500, and 1,000 mg/kg) and at different times (1.5, 6, 9, and 16 h after paracetamol administration) demonstrates that low doses could protect renal injury in early administration, whereas high doses could be protective in later administrations. Vit C treatment in 60 postmenopausal breast cancer patients using tamoxifen restored the levels of antioxidant enzymes, such as SOD, CAT, and GSH-PX (15).

Nephrotoxicity models induced by cisplatin in rats, 250 and 500 mg/kg doses of Vits C and E were used. Blood urine nitrogen and creatinine levels were increased by cisplatin and normalized by both doses of both vitamins. Reduced SOD, CAT, and GSH-Px levels were only restored in 500 mg/kg dose of both vitamins, whereas GSH-Px levels were increased by both doses of both Vits C and E. At the end of this study, it was shown that high dose of Vit C was more effective in the protection of renal oxidative damage; in addition, Vit C had more renoprotective effect than Vit E (3). In a separate study in which cisplatin + Vit C was implemented in rats, 50, 100, and 200 mg/kg doses of Vit C were used and decreased GSH levels were determined as in 100 and 200 mg/kg groups. Similar to GSH results, an indicator of lipid peroxidation, TBA reactive substance levels were significantly increased in the same groups. As a result, it was said that the protective effect of Vit C was shown in a dose-dependent manner (4). These findings also support our results that application of Vit C was found to be effective against this oxidative damage. Heaney et al. (10) determined the protective effect of Vit C against chemotherapeutics-induced cell death in their cell culture studies.

In conclusion, MTX-induced liver and kidney damages can be reduced by administering Vit C. According to the previous studies and our results, the protective effect of Vit C seemed to be related to increased GSH levels. Improvement of the tissues was observed in vitamin group histologically and biochemically. According to these results, Vit C could have protected against MTX-induced hepatorenal damage, offering potential new uses for the pharmaceutical industry.

Acknowledgements

MS and MKO formulated the present hypothesis. IAC, DKD, BD, FNC, and SY were responsible for conducting the experiments. HA and ACU made critical revisions to the manuscript. MS was responsible for the analysis and writing of the report. The study was partially supported by the Scientific Research Project Unit of Süleyman Demirel University (2270-TU-10).

Abbreviations

MTX	: Methotrexate
MDA	: Malondialdehyde
SOD	: Superoxide dismutase
CAT	: Catalase
GSH-Px	: Glutathione peroxidase
ROS	: Reactive oxygen species
NADP	: Nicotinamide adenine dinucleotide phosphate
H ₂ O ₂	: Hydrogen peroxide

REFERENCES

1. Abraham P: Vitamin C may be beneficial in the prevention of paracetamol-induced renal damage. *Clin. Exp. Nephrol.* 9, 24–30 (2005)
2. Aebi H: Catalase in vitro. *Methods Enzymol.* 105, 121–126 (1984)
3. Ajith TA, Usha S, Nivitha V: Ascorbic acid and α -tocopherol protect anticancer drug cisplatin induced nephrotoxicity in mice: a comparative study. *Clin. Chim. Acta.* 375, 82–86 (2007)
4. Antunes LM, Darin JD, Bianchi MD: Protective effects of vitamin C against cisplatin-induced nephrotoxicity and lipid peroxidation in adult rats: a dose-dependent study. *Pharmacol. Res.* 41, 405–411 (2000)
5. Armagan A, Uzar E, Uz E, Yilmaz HR, Kutluhan S, Koyuncuoglu HR: Caffeic acid phenethyl ester modulates methotrexate-induced oxidative stress in testes of rat. *Hum. Exp. Toxicol.* 27, 547–552 (2008)
6. Atashfaraz E, Farokhi F, Najafi G: Protective effect of ethyl pyruvate on epididymal sperm characteristics, oxidative stress and testosterone level in methotrexate treated mice. *J. Reprod. Infertil.* 14, 190–196 (2013)
7. Cetinkaya A, Bulbuloglu E, Kurutas EB, Kantarceken B: N-acetylcysteine ameliorates methotrexate-induced oxidative liver damage in rats. *Med. Sci. Monit.* 12, BR274–BR278 (2006)
8. Draper HH, Hadley M: Malondialdehyde determination as index of lipid peroxidation. *Methods Enzymol.* 186, 421–431 (1990)
9. Harrison FE, Meredith ME, Dawes SM, Saskowski JL, May JM: Low ascorbic acid and increased oxidative stress in *gulo*^{-/-} mice during development. *Brain Res.* 1349, 143–152 (2010)
10. Heaney ML, Gardner JR, Karasavvas N, Golde DW, Scheinberg DA, Smith EA: Vitamin C antagonizes the cytotoxic effects of antineoplastic drugs. *Cancer Res.* 68, 8031–8038 (2008)
11. Hemeida RA, Mohafez OM: Curcumin attenuates methotrexate-induced hepatic oxidative damage in rats. *J. Egypt. Natl. Canc. Inst.* 20, 141–148 (2008)
12. Jahovic N, Cevik H, Sehirli AO, Yegen BC, Sener G: Melatonin prevents methotrexate-induced hepatorenal oxidative injury in rats. *J. Pineal Res.* 34, 282–287 (2003)
13. Kolli VK, Abraham P, Isaac B, Selvakumar D: Neutrophil infiltration and oxidative stress may play a critical role in methotrexate-induced renal damage. *Chemotherapy* 55, 83–90 (2009)
14. Lowry OH, Rosenbrough NJ, Farr AL, Randall RJ: Protein measurement with the folin phenol reagent. *J. Biol. Chem.* 193, 265–275 (1951)
15. Muralikrishnan G, Amanullah S, Basha MI, Boopalan S, Vijayakumar S, Shakeel F: Effect of vitamin C on lipidperoxidation and antioxidant status in tamoxifen-treated breast cancer patients. *Chemotherapy* 56, 298–302 (2010)
16. Naseer MI, Ullah I, Ullah N, Lee HY, Cheon EW, Chung J: Neuroprotective effect of vitamin C against PTZ induced apoptotic neurodegeneration in adult rat brain. *Pak. J. Pharm. Sci.* 24, 263–268 (2011)
17. Naziroglu M, Kilinc F, Uguz AC, Celik O, Bal R, Butterworth PJ: Oral vitamin C and E combination modulates blood lipid peroxidation and antioxidant vitamin levels in maximal exercising basketball players. *Cell Biochem. Funct.* 28, 300–305 (2010)
18. Paglia DE, Valentine WN: Studies on the quantitative and qualitative characterization of erythrocyte glutathione peroxidase. *J. Lab. Clin. Med.* 70, 158–169 (1967)
19. Pinheiro FV, Pimentel VC, De Bona KS, Scola G, Salvador M, Funchal C: Decrease of adenosine deaminase activity and increase of the lipid peroxidation after acute methotrexate treatment in young rats: protective effects of grape seed extract. *Cell Biochem. Funct.* 28, 89–94 (2010)
20. Sen CK, Packer L: Thiol homeostasis and supplements in physical exercise. *Am. J. Clin. Nutr.* 72, 653–669 (2000)
21. Sener G, Eksioğlu-Demiralp E, Cetiner M, Ercan F, Sirvanci S, Gedik N: L-carnitine ameliorates methotrexate-induced oxidative organ injury and inhibits leukocyte death. *Cell Biol. Toxicol.* 22, 47–60 (2006)
22. Sun Y, Oberley LW, Li Y: A simple method for clinical assay of superoxide dismutase. *Clin. Chem.* 34, 497–500 (1988)
23. Uraz S, Tahan V, Aygun C, Eren F, Unluguzel G, Yuksel M: Role of ursodeoxycholic acid in prevention of methotrexate-induced liver toxicity. *Dig. Dis. Sci.* 53, 1071–1077 (2008)
24. Uzar E, Sahin O, Koyuncuoglu HR, Uz E, Bas O, Kilbas S: The activity of adenosine deaminase and the level of nitric oxide in spinal cord of methotrexate administered rats: protective effect of caffeic acid phenethyl ester. *Toxicology* 218, 125–133 (2006)
25. Vardi N, Parlakpınar H, Cetin A, Erdogan A, Cetin Ozturk I: Protective effect of β -carotene on methotrexate-induced oxidative liver damage. *Toxicol. Pathol.* 38, 592–597 (2010)

26. Xavier SM, Barbosa CO, Barros DO, Silva RF, Oliveira AA, Freitas RM: Vitamin C antioxidant effects in hippocampus of adult Wistar rats after seizures and status epilepticus induced by pilocarpine. *Neurosci. Lett.* 420, 76–79 (2007)
27. Yuksel Y, Yuksel R, Yagmurca M, Haltas H, Erdamar H, Toktas M, Ozcan O: Effects of quercetin on methotrexate-induced nephrotoxicity in rats. *Hum. Exp. Toxicol.* 22 Mar 2016. [Epub ahead of print]